

## Nontuberculous mycobacteria in surgery: challenges likely to be faced in Brazil?

*Micobactérias não tuberculosas em cirurgias: desafio passível de enfrentamento no Brasil?*

*Micobacterias no tuberculosas en cirugías: desafío pasible de enfrentamiento en el Brasil?*

Danielle Bezerra Cabral<sup>1</sup>, Denise de Andrade<sup>2</sup>

### ABSTRACT

Infections caused by nontuberculous mycobacteria (MNT) represent an epidemiological and health emergency, especially in patients undergoing invasive procedures. Based on these, we aimed to analyze the scientific evidence, the scientific literature, on the occurrence in Brazil of MNT infections in surgical patients. We used as a research method integrative review of the literature using the databases Lilacs, Medline/Pubmed, ISI Web of Science and the Cochrane Library. We selected 15 publications on this theme from the last 30 years that were directed at methods of prevention and control, with a focus on post-discharge surveillance, the use of antibiotics and glutaraldehyde. Eye surgery, cosmetic, heart, laparoscopic and arthroscopic procedures were the most commonly investigated. The national situation of MNTs is concerning, especially when one recognizes the possibility of underreporting.

**Keywords:** Mycobacteria, atypical; Surgical procedures operative; *Mycobacterium* infections atypical

### RESUMO

Infecções por micobactéria não tuberculosa (MNT) representam uma emergência epidemiológica e sanitária, especialmente, em pacientes submetidos a procedimentos invasivos. Frente ao exposto, objetivou-se analisar as evidências científicas, na literatura científica, sobre a ocorrência no Brasil de infecções por MNT em pacientes cirúrgicos. Utilizou-se como método de pesquisa a revisão integrativa da literatura nas bases de dados *Lilacs*, *Medline/Pubmed*, *ISI Web of Science* e *Biblioteca Cochrane*. Foram selecionadas 15 publicações sobre a temática nos últimos 30 anos que estavam direcionadas às medidas de prevenção e controle com foco na vigilância pós-alta, no uso de antibioticoterapia e glutaraldeído. Cirurgias oftalmológicas, estéticas, cardíacas e procedimentos laparoscópicos e artroscópicos foram as mais investigadas. A situação nacional das MNTs é preocupante, ainda mais quando se reconhece a possibilidade de subnotificação.

**Descritores:** Micobactérias atípicas; Procedimentos cirúrgicos operatórios; Infecções atípicas por *Mycobacterium*

### RESUMEN

Las infecciones por micobacteria no tuberculosa (MNT) representan una emergencia epidemiológica y sanitaria, especialmente, en pacientes sometidos a procedimientos invasivos. Frente a lo expuesto, se tuvo como objetivo analizar las evidencias científicas, en la literatura científica, sobre la ocurrencia en el Brasil de infecciones por MNT en pacientes quirúrgicos. Se utilizó como método de investigación la revisión integrativa de la literatura en las bases de datos *Lilacs*, *Medline/Pubmed*, *ISI Web of Science* y *Biblioteca Cochrane*. Se seleccionaron 15 publicaciones sobre la temática en los últimos 30 años que estaban orientadas a las medidas de prevención y control con foco en la vigilancia post alta, en el uso de antibioticoterapia y glutaraldeído. Cirugías oftalmológicas, estéticas, cardíacas y procedimientos laparoscópicos y artroscópicos fueron las más investigadas. La situación nacional de las MNTs es preocupante, aun más cuando se reconoce la posibilidad de subnotificación.

**Descriptores:** Micobacterias atípicas; Procedimientos quirúrgicos operativos; Infecciones atípicas por *Mycobacterium*

<sup>1</sup> Graduate student (PhD) in Nursing from the School of Nursing of Ribeirão Preto, Universidade de São Paulo - USP, Ribeirão Preto (SP), Brazil.

<sup>2</sup> Associate Professor, Department of General and Specialized Nursing School of Nursing of Ribeirão Preto, Universidade de São Paulo - USP, Ribeirão Preto (SP), Brazil.

## INTRODUCTION

Nontuberculous mycobacteria (NTM) are ubiquitous, grow in less than one hour and form visible colonies after two to five days; they are isolated in natural water and supply systems, soil, protozoa, animals and in humans<sup>(1-5)</sup>. Various species have been identified and for a long time these microorganisms were called environmental mycobacteria and then “atypical” mycobacteria or NTM or fast-growing bacteria<sup>(1)</sup>. NTM infections are more frequent on the skin and subcutaneous tissue and in general are associated with cosmetic surgical procedures such as liposuction or liposculpture<sup>(6)</sup>, injectable solutions such as procaine, L-carnitine, C vitamin, and lidocaine and after injection of silicone in mammary prosthesis<sup>(7)</sup>; acupuncture treatment; placement of nipple piercing and skin infections after tattooing<sup>(8)</sup>.

There are few cases of NTM infections published in Brazil, such as studies addressing keratitis due to *M. Chelonae* after surgery to correct myopia<sup>(9)</sup>, skin infections due to *M. abscessus* and *M. fortuitum* after applications in mesotherapy or cosmetic surgery<sup>(10)</sup> and studies addressing the increasing risk of infections caused by these species of mycobacteria in patients undergoing invasive medical procedures<sup>(11)</sup>. Hence, there seems to be an underreported distribution concerning the occurrence of NTM associated with surgeries in Brazil. It is worth noting that surgical infections result in an average of 12 additional days of hospitalization and increased costs and are considered a high priority according to the Joint Commission’s infections control standards<sup>(1)</sup>.

The prevention and control of NTM infections with the application of safe surgery protocols in Brazilian hospitals can reduce complications, which are in most instances preventable<sup>(12-13)</sup>.

This study analyzes scientific evidence concerning the occurrence of NMT infectious related to surgical procedures in Brazil and establishes an overview of the Brazilian situation based on clinical data.

## METHODS

This integrative literature review is intended to contribute to theoretical development and the incorporation of evidence-based clinical practice<sup>(14)</sup>. This is a method of choice by the researcher of the studied issue so new or emergent topics are addressed and provide readers a synthesis of this knowledge in a conceptual manner, offering a new perspective on the topic<sup>(15)</sup>.

The selection of papers was based on the following question: “What has been published in Brazil concerning the occurrence of nontuberculous mycobacteria related to surgical procedures in adult individuals without

immunological impairment?”

Controlled and non-controlled descriptors were used in the search for papers, conducted in the Medline/ PubMed (biomedical and health sciences digital files at the National Library of Medicine’s) ISI Web of Science (digital files of medical, social sciences, art and humanities of the Institute for Scientific Information – ISI Web of knowledge) and Lilacs (Latin American and Caribbean Health Sciences). The controlled descriptors obtained in the Health Sciences Descriptors (DeCS) were: Mycobacterium; Mycobacteria, Atypical; Corneal Surgery, Laser; Surgery, Plastic; Mycobacterium Infections, Atypical; Video-Assisted Surgery; Surgery Wound Infection; and Surgical Procedures, Operative. Non-controlled descriptors included: cosmetic surgical procedures; nontuberculous mycobacteria and fast-growing bacteria.

The inclusion criteria for the papers to be selected for this integrative review were full-text papers reporting the Brazilian context concerning NTM infectious in surgical procedures of adult patients. Papers written in English, Portuguese and Spanish were searched from 1980 to 2010, regardless of the study design.

Papers addressing animals or individuals with Acquired Immunodeficiency Syndrome (AIDS) undergoing treatment with antiretroviral agents— Highly Active Antiretroviral Therapy— as well as studies involving clinical samples of pulmonary secretion and endoscopic procedures for diagnosis were excluded. In the analysis of studies included in this review we used: levels of evidence (I – Systematic Reviews or meta analysis of randomized and controlled Clinical Trials (RCCT); II – randomized and controlled Clinical Trials (RCCT); III – non-randomized CT; IV – control-case or cohort studies; V – systematic reviews of qualitative studies; VI – single descriptive study; VII – expert report) and quality of information proposed by researchers in the field<sup>(16)</sup>.

## RESULTS

Fifteen studies addressing the occurrence of NTM infections in surgical procedures in Brazil were selected. Six (40%) out of these were retrieved from the Medline/ PubMed, seven (46.7%) from Lilacs and two (13.3%) from ISI Web of Science. Seven (52.9%) papers were published in Portuguese and eight (47.1%) in English. Considering the proportion of papers published per year, we observed a decrease between 1990 and 2000 and an incremental increase from 2000 to 2010 (Figure 1).

We believe that the increased number of studies between 2000 and 2010 is related to the outbreak of NTM infections. Over recent years the National Health Surveillance Agency (ANVISA) has monitored the

occurrence of post surgical NTM infections in different regions of Brazil.

In relation to the level of evidence, ten studies present weak evidence (VI and VII) with the following study's designs: case report, cross-sectional studies and literature review and five with moderate evidence (III and IV) with quasi-experimental design, retrospective cohort, methodological and longitudinal prospective studies. Hence, the presentation of data categorized the studies according to the authors' objective. The scientific production was categorized into: types of surgeries and prevention and control of mycobacteria infection followed by the subcategories: post discharge surveillance, antibiotic therapy and use of glutaraldehyde (GA). The most frequent surgeries were: cardiac surgeries (placement of porcine bio prostheses), laser *in-situ* keratomileusis (LASIK) to correct myopia, astigmatism and breast augmentation.

Table 1 presents the synthesis of the studied papers according to authors, objective, description of results and level of evidence.

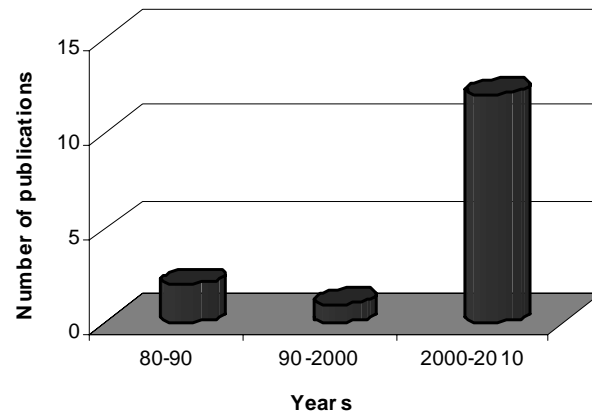


Figure 1- Scientific production according to the decade of publication. Brazil, 1980-2010.

Table 1 – Scientific studies addressing surgical infections caused by Nontuberculous mycobacteria according to the authors, objective, study's design, description of results and levels of evidence.

Authors	Objective	Design	Description of results	Level of evidence
Fontana, RT <sup>(1)</sup>	To evaluate hospital-acquired infections caused by NTM in the literature.	Literature review	Identifying strains is important to establish an early diagnosis and appropriate therapy. The contamination of products and medical devices poses a "real" risk.	VII
Padoveze MC, Fortaleza CM, Freire MP, Brandão de Assis D, Madalosso G, Pellini AC et al. <sup>(7)</sup>	To describe outbreak caused by NTM after breast implant surgeries.	Retrospective cohort	492 medical files were reviewed and 14 cases were confirmed; 12 out of the 14 cases were isolated and the following were found: <i>M. fortuitum</i> , <i>M. abscessus</i> and <i>M. porcinum</i> . The sale and reprocessing of sizers did not meet the ANVISA's requirements and were withdrawn.	IV
Alvarenga L, Freitas D, Höfling-Lima AL, Belford R Jr, Sampaio J, Sousa L et al. <sup>(9)</sup>	To describe three cases of post-LASIK infectious keratitis caused by NTM.	Cases series	Series of cases of corneal infiltrates similar to the crystalline keratopathy after LASIK surgery. Culture specimens were subsequently subjected to REA, which identified <i>M. chelonae</i> .	VI
Lorena NSO, Duarte RS and Pitombo MB <sup>(13)</sup>	To investigate the susceptibility of <i>M. mageritense</i> strains isolated for disinfection after 30 minutes, 1 hour, 6 hours and 10 hours of exposure to commercial disinfectants.	Quasi-experiment	Standard strains did not show growth after 30 minutes in 2% GA. <i>M. mageritense</i> strains were recovered after the time indicated for disinfection (30 minutes and 60 minutes) and sterilization (6 hours and 10 hours) indicating high tolerance to 2% GA.	IV
Jorge SC, Gondim FAA, Arnoni AS, Zamorano MM, Garcia DO and Sousa JEMR <sup>(17)</sup>	To describe a case of infective endocarditis in a biological valve prosthesis with negative blood cultures	Case report	40-year-old man with clinical hypothesis of infective endocarditis underwent aortic valve replacement. Negative blood cultures were performed and prosthesis revealed <i>M. chelonae</i> .	VI
Casagrande ISJ, Lucciola J and Salles CA <sup>(8)</sup>	To analyze the etiopathogenesis of contamination of porcine bio prostheses by a typical mycobacteria.	Quasi-experiment	The microbiological analysis of 400 cultures of aortic porcine valves submitted to tanning in glutaraldehyde identified colonies of <i>M. chelonae</i> . This mycobacterium was resistant to the action of 0.625% GA.	IV
Höfling-Lima AL, de Freitas D, Sampaio JL, Leão SC and Contarini P <sup>(19)</sup>	To evaluate the <i>in vitro</i> susceptibility <i>M. chelonae</i> and <i>M. abscessus</i> to antimicrobial agents based on keratitis isolates recovered after refractive surgery (LASIK)	Quasi-experiment	Isolates of <i>M. chelonae</i> (15) and <i>M. abscessus</i> (3) were tested and one among nine isolated from an outbreak in SP was sensitive to all fluoroquinolones; the remained were resistant.	IV

continue...

... continuation

Authors	Objective	Design	Description of results	Level of evidence
Freitas D, Alvarenga L, Sampaio J, Mannis M, Sato E, Sousa L et al. <sup>(20)</sup>	To describe 11 cases of keratitis by <i>M. chelonae</i> after LASIK, with microbiological and clinical investigation.	Cases series	In 2000, ten patients developed infection after LASIK. Nine eyes submitted to corneal scraping showed <i>M. chelonae</i> . Samples from the air conditioning system and water from the portable vaporizer used to clean the microkeratome tested positive to <i>M. chelonae</i> .	VI
Gusmão FA, Alvarenga L, Barbosa L, Sampaio J, Leão SC, Höfling-Lima AL et al. <sup>(21)</sup>	To describe the presence of mycobacteria in patients with deep stromal keratitis six months after intensive treatment.	Case report	41-year-old man had blurred vision, eye pain and redness due to a trauma caused by a metallic foreign body. Corneal scrapings were obtained and culture revealed <i>M. abscessus</i> .	VI
Chiquin CA, Silva JH, Cincelos MJ, Lemes MC, Penteado-Filho SR and Tuon FF <sup>(22)</sup>	To establish the occurrence of NTM infection post laparoscopic	Longitudinal Prospective	Response to the questionnaire of infection control applied to post-surgical patients was 77% (468 out of 609 phone calls). Only 11 answers suggested infectious TNM though no case of infection was reported.	VI
da Silva Telles MA, Chima E, Ferrazoli L and Riley LW <sup>(23)</sup>	To characterize the profiles of susceptibility of clinical isolates of <i>M. kansasii</i> through the CIM method	Cross-sectional	A total of 106 isolates of 26 patients infected with samples of genotype I of <i>M. kansasii</i> were collected from 1993 to 1998. Most isolates were susceptible to CLR (99% of strains), AMK (97%) and ETH (95%) and resistant to DOX (99%) and EMB (94%).	VI
Severo LC, Gomes A and Straliozzo S <sup>(24)</sup>	To describe a case of atypical mycobacteriosis by <i>M. chelonae</i> ssp. <i>abscessus</i> , which simulated sporotrichosis.	Case report	67-year-old man reported trauma with metallic object on the back of hand. Erythematous nodules emerged and skin biopsy identified <i>M. chelonae</i> ssp. <i>abscessus</i> .	VI
Pitombo MB, Lupi O and Duarte RS <sup>(25)</sup>	To analyze the main factors for infections caused by <i>M. massiliense</i> related to the clone BRA100 resistant to GA 2%.	Literature review	Brazilian studies investigated in this review presented evidence that reprocessing of surgical devices was inappropriate, especially those submitted to 2% GA.	VII
Duarte RS, Lourenço MC, Fonseca L de S, Leão SC, Amorim E de L, Rocha IL et al. <sup>(26)</sup>	To determine the species, patterns of sensitivity to antimicrobial and GA and clonality of isolates of mycobacteria recovered from post-surgical infections.	Cross-sectional	Of the 1,051 potential cases of post-surgical infections from 2006 to 2007, 148 isolates were available to molecular characterization. All isolates of the clone BRA100 <i>M. massiliense</i> survived after 30 minutes and 10 hours in 2% GA.	VI
Carvalho Júnior LH, Pereira ML, Costa LP, Gonçalves MJB, Soares LFM, Santos RL et al. <sup>(27)</sup>	To evaluate <i>in vitro</i> the 2.2% GA power antiseptics in disposable razors used in arthroscopy.	Non-randomized experiment	Growth was not observed in any of the samples in the group 1 after analysis of cultures. The growth of microorganisms was observed in all the samples in the group 2. No growth was observed after 30 minutes in 2.2% GA.	III

## DISCUSSION

Mycobacterial infections related to cardiac surgeries have been reported since the mid 1970s in the United States and Hungary<sup>(6)</sup>. Post-surgical infective endocarditis is among these infections, which should be included in the etiological diagnosis of prosthetic infections, which implies removing the infected prosthesis. It is important to stress the importance of cultures and the histopathological exams of prostheses when replaced in cases of suspected endocarditis because it may be the only evidence of the diagnosis of patients with an "apparently negative" blood culture<sup>(17-18)</sup>.

The risk of NTM infection in reconstructive breast surgery has a worldwide incidence of 4.8% to 17.8% but there are no data concerning its occurrence in Brazil<sup>(7,28)</sup>. The complications of this surgery are significant causes of morbidity, many of which are related to the healing of wounds and viability of the breast implant<sup>(28)</sup>. The onset of clinical signs range from three weeks to three months, though there are reports of up to two years after surgery. Symptomatology includes edema, sensitivity and erythema<sup>(7)</sup>. In the therapeutic context, the initial treatment of any infection after breast implants is empirical antibiotic therapy and if symptoms and periprosthetic infection do not

improve, removal of the prosthesis with debridement is recommended<sup>(8)</sup>.

Reports of NTM infections related to ophthalmological surgeries mainly indicated laser surgeries to correct myopia<sup>(8)</sup>. Hence, clinical characteristics of NTM infections are key for suspecting infection post LASIK. NTM keratitis is characterized by its indolent course and low antimicrobial response, progressing to a severe necrosis due to the inflammatory process<sup>(9,19-20)</sup>. Patients report pain, photophobia, decreased vision and redness, and alternatively they may complain of foreign body sensation or just a mild irritation<sup>(9)</sup>.

The incidence and etiology of infectious keratitis related to LASIK in Brazil is unknown<sup>(21)</sup>. However, mycobacterial infections have been frequently associated with keratitis post LASIK due to failure in antimicrobial therapy, especially monotherapy<sup>(29)</sup>. Nevertheless some authors recommend performing cultures of corneal infiltrates to confirm the diagnosis and determine sensitivity to antibiotics to implement appropriate therapeutic measures<sup>(9,20)</sup>.

Considering that the risk for infection represents an important threat to the safety of patients and professionals delivering care, prevention and control actions should be implemented in the entire organizational structure. There is a need for integrated and responsive programs in a multidisciplinary scope. A difficulty identified in post-discharge surveillance is the monitoring and early identification of infected and colonized cases in postsurgical procedures<sup>(22)</sup>. Hence, various post-discharge surveillance methods concerning Healthcare-Associated Infections (HAI) are recommended, however choosing the best method is difficult and each institution should use the one compatible with its resources, structure and clientele profile<sup>(22,30)</sup>.

The NTM infection diagnosis may be difficult, nevertheless the greatest problem faced by health professionals is its treatment<sup>(31)</sup>. An important characteristic of these mycobacteria is resistance to medications used in the treatment of tuberculosis<sup>(11)</sup>. It is worth noting that the clone BRA100 of *M. massiliense*, predominant in Brazil, is sensitive *in vitro* to ampicillin, claritromicina and tigecycline but resistant to doxycycline and ciprofloxacin, and has intermediate sensitivity to cefoxitin and imipenem<sup>(8)</sup>. In this context, empirical

antibiotic therapy should be implemented for at least six months and include, whenever possible, a surgical approach to remove infected tissue or any other foreign body to ensure the success of therapy<sup>(4,8)</sup>.

Given the previous discussion, the identification of species is important for implementing appropriate therapy, because isolated strains of clinical cases present differences in patterns of sensitivity to antimicrobial agents<sup>(1,23)</sup>. We also highlight the possibility of harmonic association among different microorganisms. Therefore, identifying the epidemiological and pathogenetic chain of NTM is required to adopt preventive measures of symptomatology associated with other microbial species such as fungi<sup>(24)</sup>. National alert reports the specific features of the Brazilian profile of the strain sensitivity, given guidelines of the Committees of Hospital-Acquired Infections Control and the patients' individual conditions<sup>(32)</sup>.

Mycobacterial infections are strongly associated with failure in reprocessing surgical devices. In most of the health services investigated by the Brazilian health agency, these devices were submitted only to the disinfection process and not to sterilization<sup>(25)</sup>. Studies included in the subcategory—use of glutaraldehyde (GA)—, showed that clinical strains of post-laparoscopy lesions, previously classified as *M. massiliense*, were resistant to 2% GA both in the disinfection and sterilization processes<sup>(13,25-27)</sup>.

## CONCLUSION

This review shows that the most important aspect in the conduct of mycobacteria is prevention. Obviously in a country with continental proportions such as Brazil, a diversity of situations and conduct is inevitable. Consequently, effective surveillance strategies, control, supervision, and educational interventions were idealized in theory but are fragmented in the practical context of health care. Various post-discharge surveillance methods concerning HAI were recommended but choosing the ideal method is difficult and each institution should develop and use the one compatible with its resources, structure and profile of its clientele. In this context, the real occurrence of TNM in surgeries in Brazil remains obscure, especially if we consider that some diagnosis and control strategies have been already implemented.

## REFERENCES

1. Fontana RT. As micobactérias de crescimento rápido e a infecção hospitalar: um problema de saúde pública. *Rev Bras Enferm*. 2008;61(3):371-6.
2. Marinho A, Fernandes G, Carvalho T, Pinheiro D, Gomes I. Micobactérias atípicas em doentes sem síndrome de imunodeficiência adquirida. *Rev Port Pneumol*. 2008;14(3):323-37.
3. Pedro HSP, Pereira MIF, Goloni MRA, Ueki SYM, Chimara E. Isolamento de micobactérias não-tuberculosas em São José do Rio Preto entre 1996 e 2005. *J Bras Pneumol*.

- 2008;34(11):950-5.
4. Hinrichsen SL. Micobactéria de crescimento rápido – MCR. *Prática Hosp.* 2007;9(53):106-11.
  5. Macedo JS, Henriques CMP. Infecções pós-operatórias por micobactérias de crescimento rápido no Brasil. *Rev Bras Cir Plást.* 2009;24(4):544-51.
  6. Murillo J, Torres J, Bofill L, Ríos-Fabra A, Irausquin E, Istúriz R, et al. Skin and wound infection by rapidly growing mycobacteria: an unexpected complication of liposuction and liposculpture. The Venezuelan Collaborative Infectious and Tropical Diseases Study Group. *Arch Dermatol.* 2000;136(11):1347-52.
  7. Padoveze MC, Fortaleza CM, Freire MP, Brandão de Assis D, Madalosso G, Pellini AC, et al. Outbreak of surgical infection caused by non-tuberculous mycobacteria in breast implants in Brazil. *J Hosp Infect.* 2007;67(2):161-7.
  8. Brasil. Ministério da Saúde. Agência Nacional de Vigilância Sanitária. Nota técnica conjunta n° 01/2009 – SVS/MS e ANVISA. Infecções por micobactérias de crescimento rápido: fluxo de notificações, diagnósticos clínico, microbiológico e tratamento. Infecções por micobactérias em pacientes submetidos a procedimentos cirúrgicos ou cosméticos. 2009. [citado 2010 Jan 11]. Disponível em: [http://www.anvisa.gov.br/hotsite/hotsite\\_micobacteria/nota\\_tecnica\\_conjunta.pdf](http://www.anvisa.gov.br/hotsite/hotsite_micobacteria/nota_tecnica_conjunta.pdf).
  9. Alvarenga L, Freitas D, Höfling-Lima AL, Belford R Jr, Sampaio J, Sousa L, et al. Infectious post-LASIK crystalline keratopathy caused by nontuberculous mycobacteria. *Cornea.* 2002;21(4):426-9.
  10. Oliveira e Sousa ACG, Pereira CP, Guimarães NS, Rego VR, Paixão AP, Barbosa Júnior AA. Micobacteriose cutânea atípica pós-mesoterapia. *An Bras Dermatol.* 2001;76(6):711-5.
  11. Cardoso AM, Martins de Sousa E, Viana-Niero C, Bonfim de Bortoli F, Pereira das Neves ZC, Leão SC, et al. Emergence of nosocomial *Mycobacterium massiliense* infection in Goiás, Brazil. *Microbes Infect.* 2008;10(14-15):1552-7.
  12. Ferraz EM. A cirurgia segura. Uma exigência do século XXI. *Rev Col Bras Cir.* 2009;36(4):281-2.
  13. Lorena NSO, Duarte RS, Pitombo MB. Infecção por micobactérias de crescimento rápido após procedimentos videocirúrgicos – a hipótese do glutaraldeído. *Rev Col Bras Cir.* 2009;36(3):266-7.
  14. Whitemore R, Knafl K. The integrative review: updated methodology. *J Adv Nurs.* 2005;52(5):546-53.
  15. Torraco RJ. Writing integrative literature reviews: guidelines and examples. *Hum Res Develop Rev.* 2005;4(3):356-67.
  16. Melnyk BM, Fineout-Overholt E. Making the case for evidence-based practice. In: Melnyk BM, Fineout-Overholt E. Evidence-based practice in nursing & healthcare: a guide to best practice. Philadelphia: Lippincott Williams & Wilkins; 2005. p. 3-24.
  17. Jorge SC, Gondim FAA, Arnoni AS, Zamorano MM, Garcia DO, Sousa JEMR. Endocardite por *Mycobacterium chelonae* em prótese valvar. *Arq Bras Cardiol.* 1994;63(2):121-5.
  18. Casagrande ISJ, Lucciola J, Salles CA. Micobactérias atípicas em biopróteses: causa potencial de endocardite com culturas negativas. *Rev Bras Cir Cardiovasc.* 1986;1(1):40-3.
  19. Höfling-Lima AL, de Freitas D, Sampaio JL, Leão SC, Contarini P. In vitro activity of fluoroquinolones against *Mycobacterium abscessus* and *Mycobacterium chelonae* causing infectious keratitis after LASIK in Brazil. *Cornea.* 2005;24(6):730-4.
  20. Freitas D, Alvarenga L, Sampaio J, Mannis M, Sato E, Sousa L, et al. An outbreak of *Mycobacterium chelonae* infection after LASIK. *Ophthalmology.* 2003;110(2):276-85. Review.
  21. Gusmão FA, Alvarenga L, Barbosa L, Sampaio J, Leão SC, Höfling-Lima AL, et al. Deep stromal mycobacterial keratitis: viable bacteria after six months of treatment: case report and literature review. *Arq Bras Oftalmol.* 2005;68(4):551-3.
  22. Chiquin CA, Silva JH, Ciruelos MJ, Lemes MC, Pentead-Filho SR, Tuon FF. Postdischarge surveillance system for nontuberculous mycobacterial infection at a Brazilian regional referral hospital after an outbreak. *Infect Control Hosp Epidemiol.* 2009;30(4):399-401.
  23. da Silva Telles MA, Chimara E, Ferrazoli L, Riley LW. *Mycobacterium kansasii*: antibiotic susceptibility and PCR-restriction analysis of clinical isolates. *J Med Microbiol.* 2005;54(Pt 10):975-9.
  24. Severo LC, Gomes A, Stralio S. Micobacteriose atípica (*Mycobacterium chelonae* ssp. *abscessus*) simulando esporotricose. *An Bras Dermatol.* 1987;62(2):105-7.
  25. Pitombo MB, Lupi O, Duarte RS. Infecções por micobactérias de crescimento rápido resistentes a desinfetantes: uma problemática nacional? *Rev Bras Ginecol Obstet.* 2009;31(11):529-33.
  26. Duarte RS, Lourenço MC, Fonseca L de S, Leão SC, Amorim E de L, Rocha IL, et al. Epidemic of postsurgical infections caused by *Mycobacterium massiliense*. *J Clin Microbiol.* 2009;47(7):2149-55.
  27. Carvalho Júnior LH, Pereira ML, Costa LP, Gonçalves MJB, Soares LFM, Santos RL, et al. Infecção por micobactéria após videoartroscopia: o glutaraldeído pode ser o culpado? Estudo experimental in vitro. *Rev Bras Ortop.* 2008;43(6):256-60.
  28. Coney PM, Thrush S. Cutaneous *Mycobacterium fortuitum* complicating breast reconstruction. *J Plast Reconstr Aesthet Surg.* 2007;60(10):1162-3.
  29. de la Cruz J, Behlau I, Pineda R. Atypical mycobacteria keratitis after laser in situ keratomileusis unresponsive to fourth-generation fluoroquinolone therapy. *J Cataract Refract Surg.* 2007;33(7):1318-21.
  30. Sherertz RJ, Garibaldi RA, Marosok RD, Mayhall CG, Scheckler WE, Berg R, et al. Consensus paper on the surveillance of surgical wound infections. *Am. J. Infect. Control.* 1992;20(5):263-70.
  31. Saluja A, Peters NT, Lowe L, Johnson TM. A surgical wound infection due to *Mycobacterium chelonae* successfully treated with clarithromycin. *Dermatol Surg.* 1997;23(7):539-43.
  32. Brasil. Ministério da Saúde. Agência Nacional de Vigilância Sanitária. Informe técnico n° 02/07. Medidas para a interrupção do surto de infecção por MCR e ações preventivas. 2007. [acesso em 11 jan 2010]. Disponível em: [http://www.anvisa.gov.br/servicosaude/control/Alertas/informe\\_tecnico\\_2.pdf](http://www.anvisa.gov.br/servicosaude/control/Alertas/informe_tecnico_2.pdf).