

Uri Adrian Prync Flato<sup>1</sup>, Hélio Penna Guimarães<sup>2-4</sup>, Renato Delascio Lopes<sup>3-4</sup>, Jorge Luís Valiatti<sup>5</sup>, Elias Marcos Silva Flato<sup>6</sup>, Ricardo Gonçalves Lorenzo<sup>7</sup>

## Usefulness of Extended-FAST (EFAST-Extended Focused Assessment with Sonography for Trauma) in critical care setting

*Utilização do FAST-Estendido (EFAST-Extended Focused Assessment with Sonography for Trauma) em terapia intensiva*

1. Physician of the Intensive Care Unit of Instituto Dante Pazzanese de Cardiologia – São Paulo (SP), Brazil.
2. Coordinator for the Training Center of the Hospital do Coração - CETES-HCor – São Paulo (SP), Brazil.
3. Adjunct Professor for the Division of Cardiology of the Department of Internal Medicine of the Duke Clinical Research Institute, Duke Medical Center, Duke University, Durham - USA.
4. Physician of the Discipline of Internal Medicine of the Universidade Federal de São Paulo – UNIFESP – São Paulo (SP), Brazil.
5. Titular Professor for the Discipline of Intensive Care Medicine of the Faculdade de Medicina de Catanduva – Catanduva (SP), Brazil.
6. Internal Medicine Resident Physician of the Santa Casa de São Paulo – SCMSP - São Paulo (SP), Brazil.
7. Physician of the Center Diagnostic Imaging of Hospital Alemão Oswaldo Cruz – São Paulo (SP), Brazil.

Received from the Intensive Care Unit of the Instituto Dante Pazzanese de Cardiologia - São Paulo (SP), Brazil.

Submitted on March 20, 2010  
Accepted on August 13, 2010

### Author for correspondence:

Uri Adrian Prync Flato  
Instituto Dante Pazzanese de Cardiologia  
Av. Dr. Dante Pazzanese, 500- 3<sup>rd</sup> floor  
Zip Code: 04012-180- São Paulo (SP), Brazil.  
Phone/Fax: +55 (11) 5081-4531  
Email: uriflato@gmail.com

### ABSTRACT

Trauma is the leading cause of death in people below 45 years-old in Brazil, and responsible for one third of all intensive care unit admissions. The increasing knowledge on ultrasound diagnosis methods and its availability for life-threatening injuries (such as cardiac tamponade and abdominal cavity solid organs rupture leading to hemorrhagic shock) diagnosis and monitoring, lead to the development of the FAST (Focused Assessment with Sonography for Trauma) protocol, aimed to be used both in the emergency and intensive care unit settings. Due to its reproducibility, lack of radiation exposure, and bedside feasibility, this technology is being increasingly accepted. A new protocol extension, the Extend-

ed-FAST, provides valuable information for improved patients' management, extending its availability from the abdominal conditions to other diagnosis such as hemothorax, pleural effusion and pneumothorax. We must underline that this technique is able to replace computed tomography and diagnostic peritoneal wash, and do not delay surgical procedure instead of perform this exam. Thus, its careful appraisal in connection with the clinical information should guide the therapeutic approaches, specially in inhospitable sites such as intensive care units in war zones, rural or distant places, where other imagery methods are not available.

**Keywords:** Ultrasonography/utilization; Trauma; Intensive care/trends; Point-of-care systems

### INTRODUCTION

The use of ultrasonography (US) in polytrauma patients, specially according to the FAST (Focused Assessment with Sonography for Trauma) protocol,<sup>(1-3)</sup> is not restricted to the initially stable or unstable patient' evaluation, but is additionally a valuable tool for the follow-up. Considering that being "stable" not necessarily means being free of threats to life, but, depending on the trauma mechanics may be a potentially dangerous condition, portable devices providing early identification of life threatening injuries (consequently changing its natural course), may become life-and-death deciders. A practical example could include a closed abdominal trauma patient without cardiac tamponade clinical signs, in who early US identifies signs of pericardial effusion

with myocardial restriction – which would radically change the approach to an immediate intervention. A FAST protocol extension, the Extended-FAST, was developed aimed to extend the evaluation, previously restricted to heart and abdominal wall evaluations, to the chest cavity, allowing pneumothorax, hemothorax and diaphragm rupture diagnosis. The Chart 1 describes the main EFAST<sup>(4)</sup> indications.

**Chart 1- EFAST Indications**

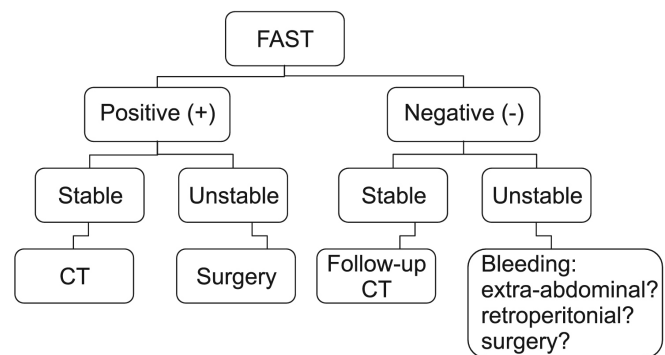
EFAST Indications
Penetrating heart trauma
Closed heart trauma
Closed abdominal trauma
Chest trauma
Pneumothorax
Hemothorax
Undefined cause hypotension

“Stable” should mean “stay alert and keep monitoring the patient”; on the other hand, instability should be understood as a clinical condition where immediate measures are required to prevent a catastrophic outcomes. Peitzman et al. evaluated the closed trauma shock etiology, and described as primary cause (decreasing frequency) hypovolemia (59%), head trauma (16%), obstruction (pneumothorax, cardiac tamponade) (13%), neurogenic shock (7%) and others (7%).<sup>(5)</sup> The bleeding site identification and its control is vital, as resuscitation measures, such as crystalloid infusions, may have either transitory or no response at all if the bleeding site is left untreated. In case of a vascular injury, the definitive treatment is vital, as is the Damage Control Therapy in selected cases.

During the last decade, several international societies have strongly recommended the FAST protocol (Grade I).<sup>(6-10)</sup> It is suitable for closed abdominal trauma, closed or penetrating chest trauma, either in stable or unstable patients. As it is an operator-dependent test, the apprenticeship curve, which is correlated with the results, is required. The literature describes variable outcomes according to different operators (radiologist versus emergencist), associated parenchyma injuries (which the method was not planned for) and hemodynamic status (arterial hypotension versus normotension).<sup>(11-14)</sup>

A positive FAST test points to in-cavity bleeding and likely requires exploratory laparotomy if the patient is hemodynamically unstable, or con-

tinued diagnosis with computed tomography (CT), if available, in clinically stable patients (Figure 1).



Scalea TM, Rodriguez A, Chiu WC, et al. Focused assessment with sonography for trauma (FAST): results from an international consensus conference. *J Trauma* 1999;46(3):466–72.

CT – computed tomography; FAST - Focused Assessment with Sonography for Trauma.

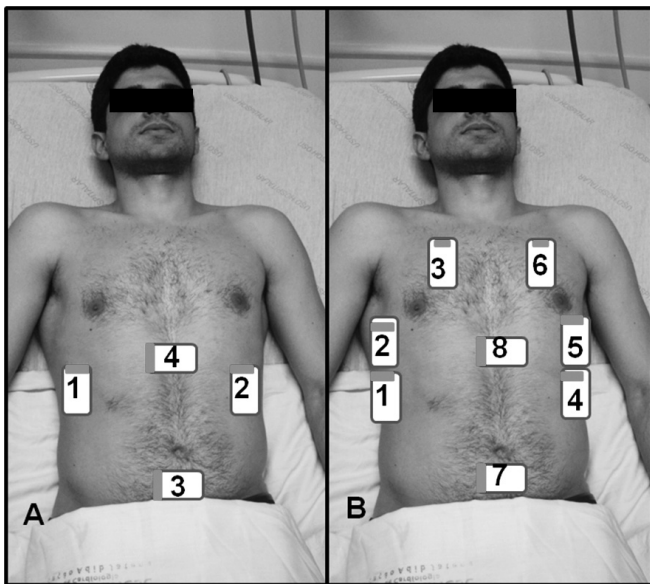
**Figure 1 - FAST consensus.**

A FAST peculiarity is its feasibility even in restricted complementary methods sites, as seen in natural catastrophes (e.g. earthquakes), war conflicts, spatial stations, where additional data may be decisive and no other complementary methods are available.<sup>(15-17)</sup>

Isolated free fluid in the cavity itself does not mean immediate surgery requirement, as it should be associated with other aspects such as the amount of cavity free fluid, number of sites (recesses, gutters) with fluid and the patient’s clinical status. Some authors have proposed FAST positive patients scoring protocols, aiming risk stratification (either low or high) and surgical indication, e.g. free fluid collection observed in more than three recesses was correlated with a more than 1,000 mL intra-peritoneal volume.<sup>(18,19)</sup> Identification of high risk patients (closed abdominal trauma and arterial hypertension) evidenced the test accuracy to be about 95%, the sensitivity 85% and specificity 96%, according to Lee et al., for exploratory laparotomy and consequent therapeutic intervention.<sup>(20)</sup>

With the EFAST<sup>(21)</sup> development and use (Figure 2) the chest cavity may be evaluated just sliding the transducer cranially after the Morrison (hepatorenal) and splenorenal spaces evaluations. The EFAST sequence indicates initially the abdomen evaluation, and then the chest evaluation as described in the secondary Advanced Trauma Life Support evaluation (feet to head evaluation), i.e., following the primary evaluation. However, the WINFOCUS

(World Interactive Network Focused on Critical Ultrasound) is currently developing the use of ultrasound for initial polytrauma patient's evaluation, starting from the primary evaluation until resolution or surgical procedure. This protocol will be included in the Ultrasound Trauma Life Support (US-ATLS) algorithm.<sup>(22)</sup> Based on this sequence, the ABC approach to trauma is suggested, starting by the airways (confirmation of patent airways and support to surgical airway), breathing (pneumothorax and hemothorax) and circulation, by bleedings as hemoperitoneum investigation.



FAST - Focused Assessment with Sonography for Trauma; EFAST - Extended Focused Assessment with Sonography for Trauma.

**Figure 2- FAST (A) and EFAST (B) anatomical references.**

### Pulmonary ultrasound

The correct chest anatomical references as diaphragm, pulmonary parenchyma, costal arcs and US artifacts identification is vital for appropriate reading. Changes as pleural effusion, hemothorax, lack of pleural sliding (pneumothorax, selective intubation), pulmonary complications related to the intubated patient transportation (as tube displacement, among others) may be diagnosed. The relevance of this method parallels with the frequency of chest changes found in major trauma patients. One pneumothorax was evidenced out of every 5 major traumas, which, if not identified, could lead to serious hemodynamic changes and death. Blaiwas et

al.<sup>(23)</sup> evaluated the chest X-ray (anterior-posterior incidence) versus pulmonary US accuracy for occult pneumothorax identification (normal chest X-ray reading and pneumothorax evidenced on CT or US) in polytrauma patients, and found this last to have an approximately 94% accuracy versus X-ray. Occult pneumothorax alone may not directly determine the patient's deterioration, however when associated with secondary injuries such as pulmonary contusion, hypothermia, hypoxia, and positive pressure ventilation, may lead to serious consequences. In observational studies occult pneumothorax in trauma patients was described by chest CT in about 55%.<sup>(24,25)</sup> Its quick bedside identification possibilities to be done in hospital settings /or in battlefield scenarios, not implying risks for the patient or other devices unavailability can optimize the patient care, and thus reduce mortality. This tool is aimed to support the treating physician's decision making process, and to support the monitoring of pharmacological and surgical interventions. The medical experience with EFAST US is related its correct use as well as technical limitations and reading mistakes.<sup>(26-28)</sup>

Appropriate awareness of human anatomy and its correlation with this method's bidimensional images are required, and two different orthogonal approaches are recommended. As this protocol is aimed to identify free fluids within cavities and pneumothorax, rather than complex organs evaluations, its apprenticeship curve is short and relatively easy. Free abdominal fluid detection is made, according to the magnitude, first in the upper right quadrant<sup>(29)</sup> (hepatorenal recess), which when systematically conducted takes just 19 seconds. A full negative FAST examination takes about 3 minutes. Again, it should be emphasized that a negative result does not preclude life threatening injuries such as retroperitoneal bleedings and hollow viscerae injuries, which are not included in the method.

EFAST ultrasound references are:

- Hepatorenal recess (Figure 3)
- Right anterior axillary line (liver-lung (diaphragm) transition) Figure 4)
- Right anterior hemiclavicular line, between the 3<sup>rd</sup> and 5<sup>th</sup> intercostal space (Figure 5)
- Splenorenal recess (Figure 6)
- Left anterior axillary line, spleen-lung transition (Figure 7)

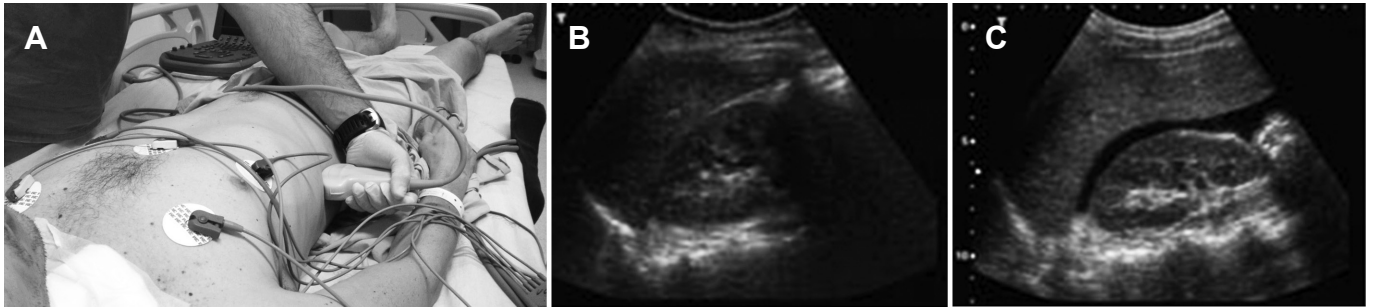


Figure 3 - A- US probe on hepatorenal space; B- normal US image; C- fluid in the Morrison's space (FAST+).

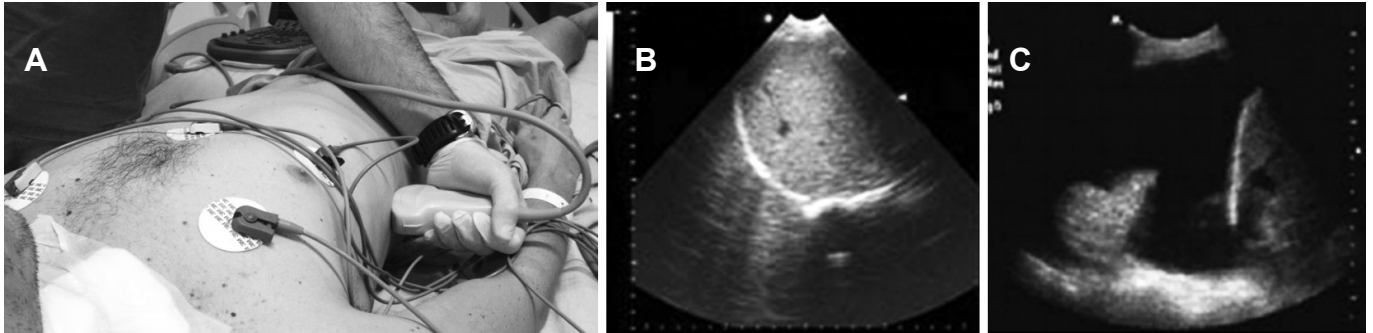


Figure 4 - A- probe on diaphragm/lung parenchyma intersection; B- right chest cavity image without fluid; C- right chest cavity fluid, and pulmonary consolidation.

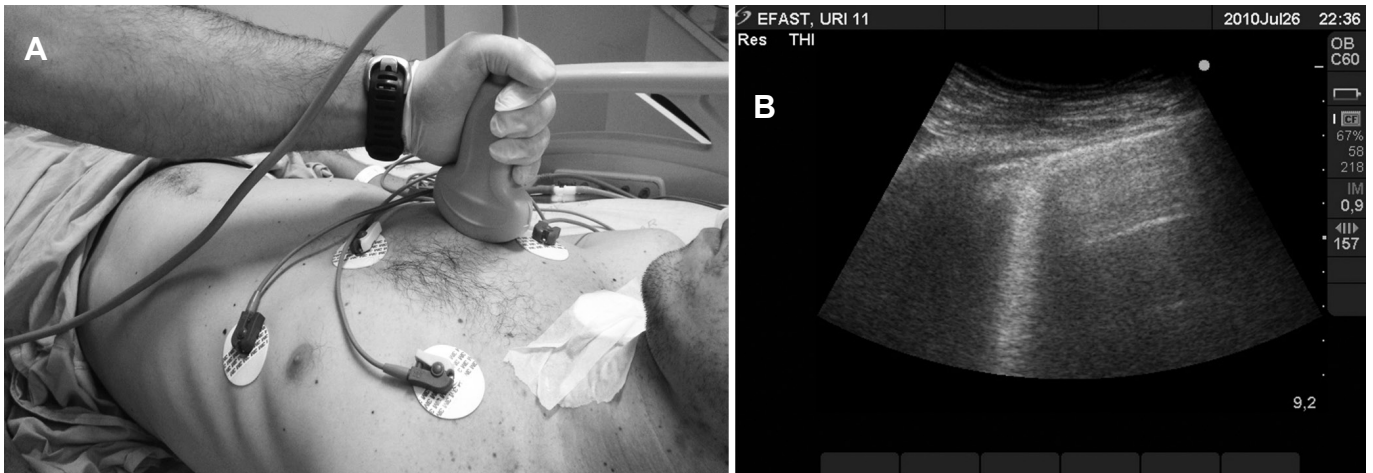


Figure 5 - A- probe on anterior chest region, between 3<sup>rd</sup> and 5<sup>th</sup> intercostal space on right hemiclavicular line; B- normal US image (lines A and B present).

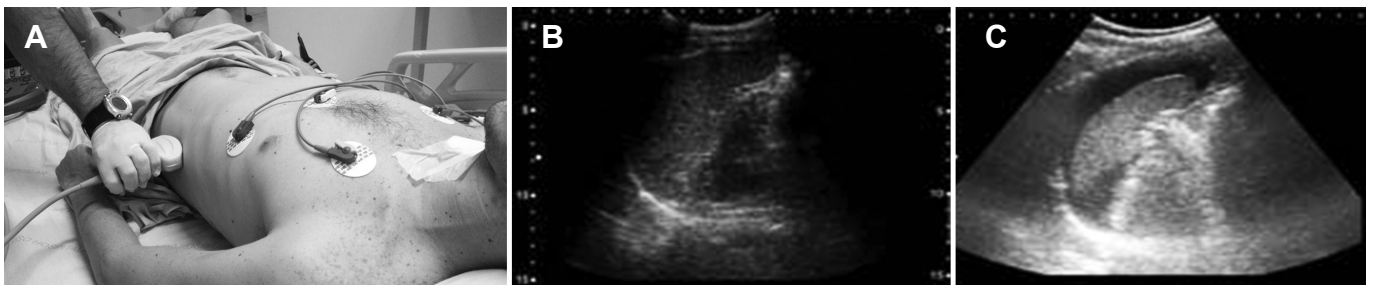


Figure 6 - A- Probe on the splenorenal space; B- normal ultrasonography image; C- peri-splenic space fluid.

- Left anterior hemiclavicular line between the 3<sup>rd</sup> and 5<sup>th</sup> intercostal space (anterior left hemithorax evaluation) (Figure 8)
- Retrovesical space (Douglas space) (Figure 9)

- Pericardial window (sub-xyphoid aspect, 4 heart chambers) (Figure 10)

**Ultrasound pulmonary signs**

The EFAST described ultrasound signs, specially

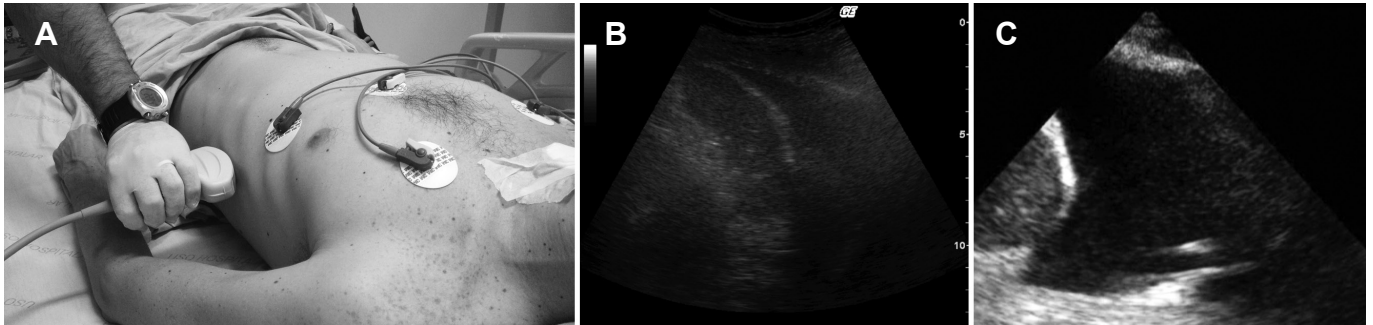


Figure 7 – A- probe on left diaphragm/lung parenchyma intersection; B- left chest cavity image without fluid; C- left chest cavity fluid (pleural effusion).

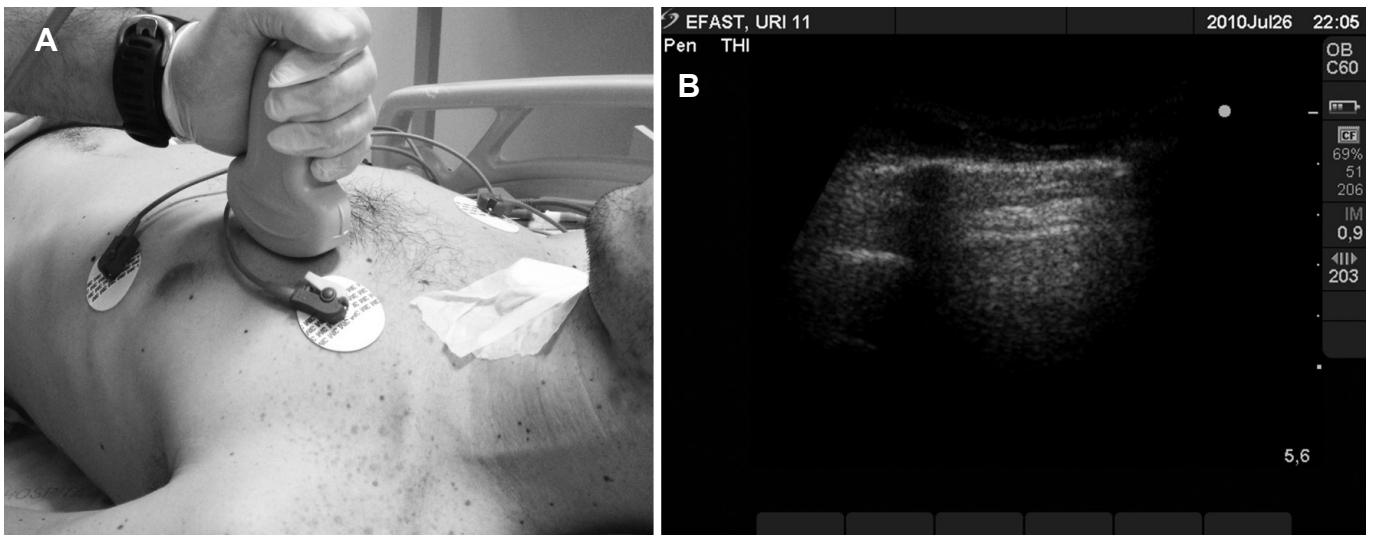


Figure 8 – A- probe on anterior chest between 3<sup>rd</sup> and 5<sup>th</sup> intercostal space by the left hemiclavicular line; B- normal lung image.

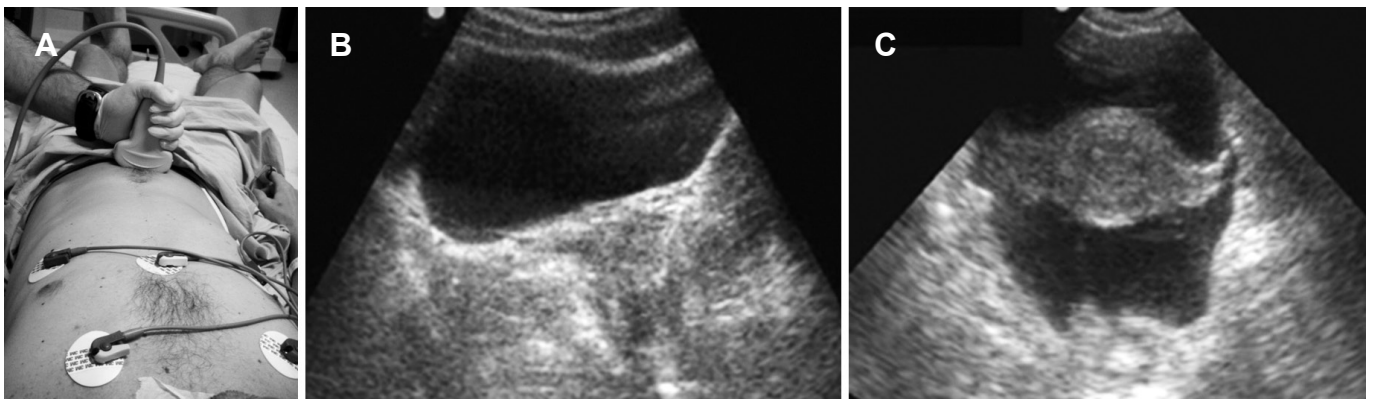
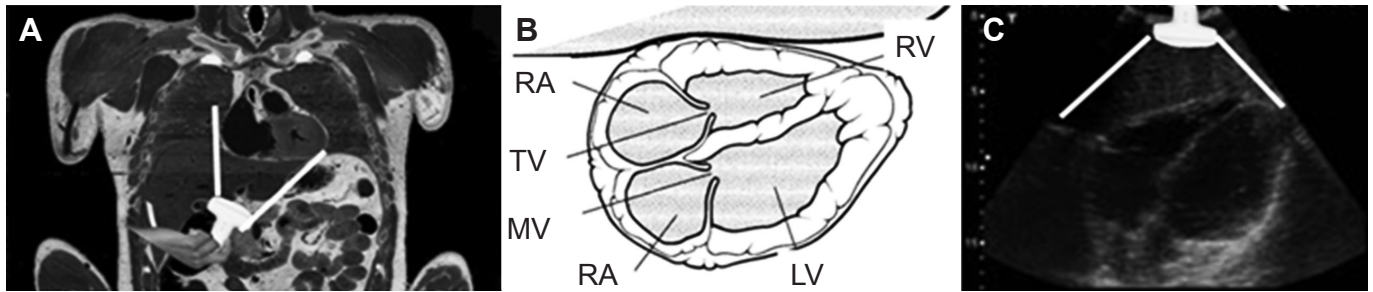


Figure 9 – A- transducer on hypogastric region; B- male patient transversal view showing urinary bladder and the rectum; C- free fluid between the urinary bladder and rectum.



**Figure 10 – A- probe on sub-xyphoid region, using liver as acoustic window; B- heart structures anatomical identification (ultrasound image); C- heart image from sub-xyphoid window.**

on the chest examination, are the search of pleural sliding which may suggest some diagnosis (Chart 2) and ultrasound artifacts such as lines A, lines B, Doppler mode use, Power Sliding and the Lung Point search, this last with 100% sensitivity and 98% specificity for pneumothorax detection.<sup>(30)</sup> In this review we will approach practically and objectively the main pneumothorax detection pulmonary artifacts.

#### Chart 2 – Lung Sliding negative diagnosis

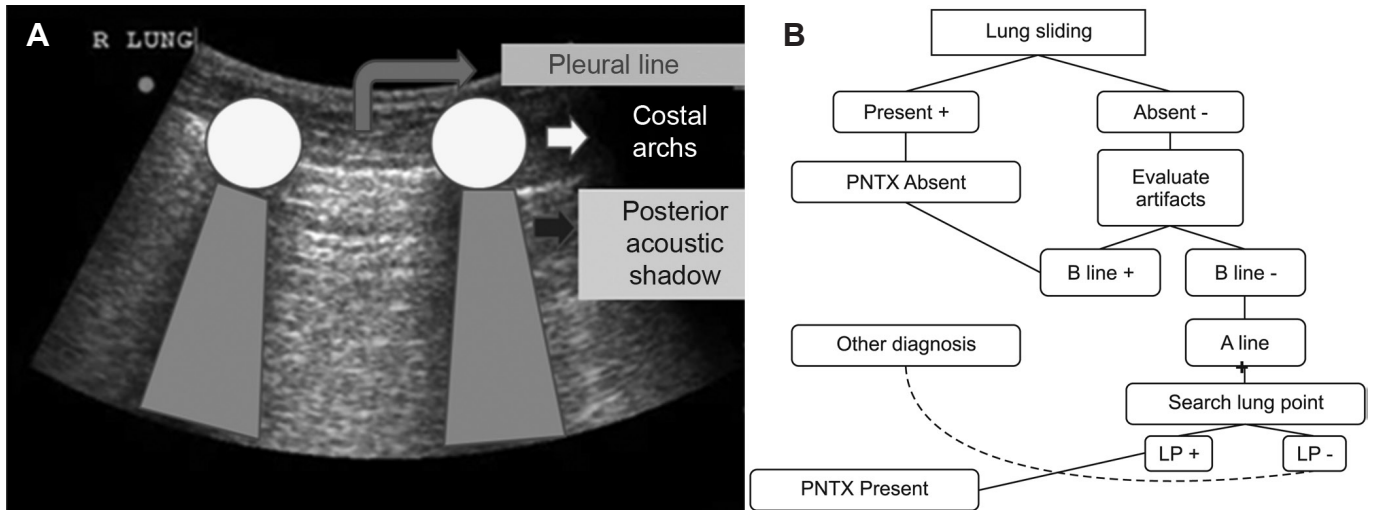
Negative lung sliding sign (Lung Sliding)
Inflammatory adhesences
Atelectasis
Apnea
Pneumothorax
Pneumectomy
Selective pulmonary intubation

Initially pulmonary US was restricted to pleural structures and adjacent diseases, as the pulmonary window is not appropriate for ultrasound waves propagation (reflection effect) through air or intercostal bones.<sup>(31)</sup> Currently, by understanding some diseases' artifacts on pulmonary parenchyma such as interstitial pulmonary diseases, pneumothorax and atelectasis, its use was widespread to the trauma and intensive care settings. US pneumothorax detection may appear paradoxical, as the air is an obstacle for US waves' propagation; however the artifacts produced through visceral and parietal pleura are indirect signs for its diagnosis. Structures to be identified during a chest examination are: pleural line (visceral plus parietal pleura), costal arcs and pulmonary parenchyma. The probe's positioning should be longitudinal to the chest wall, in the medium axillary line, between the third and fifth intercostal spaces, while the patient lays in horizontal decubitus or semi-seated, as in these positions lung

sliding detection is easier. The same FAST probe is used, i.e., convex 3.5 to 5 mHz or micro-convex ultrasound, aiming to reduce the test duration. Initially the costal arc shadow is identified, and next the intercostal space. The hypoechogenic structure just below the costal arcs is the pleural line (Figure 11).

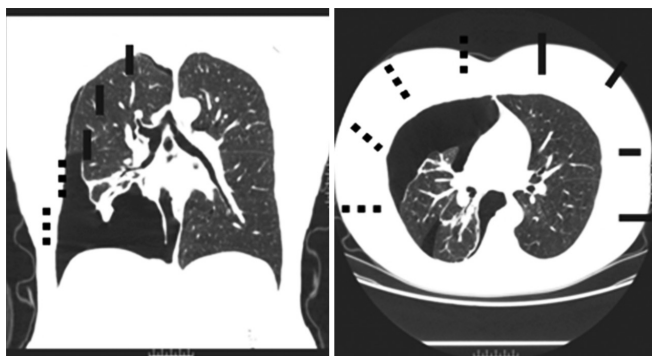
During this dynamic evaluation the pleural line movements may be observed, translated by the sliding between visceral and parietal pleura. Lacking LS is the main sign suggesting pneumothorax and in trauma and intensive care settings, others artifacts should be checked according to the algorithm (Figure 12). To complement the investigation, the presence of B lines (named comet tail artifact) should be evaluated, which represent a reverberation artifact from the visceral pleura and are derived from inter-lobules septa thickening.

The B lines can be identified in normal subjects in gravity-dependent pulmonary regions, such as the bases. In other disease situations, they may be found in aired regions, but this is out of the EFAST scope. To correctly understand the B lines and differentiate them from other pulmonary signs such as Z lines, they can be recognized according to the seven features described by Linchestein et al.: well-defined hyperechogenic sign, visible in the entire monitor, moving with LS (when present), erases A waves (artifacts), hydroaereal comet tail artifact, and originated from the pleural line. LS and B lines identification has a negative predictive value of 97%, meaning that in a chest region with LS and B lines, there is no pneumothorax.<sup>(32)</sup> The ultrasonography artifact A line are hypoechogenic horizontal lines parallel to the pleural line, formed from pleural ultrasound reverberation, which are equidistant to each other. One should have in mind that the pneumothorax may be anterior, posterior, apical or in the base.<sup>(32)</sup> In order to preclude pneumothorax one should scan



PNTX = pneumothorax.

Figure 11 - A- structures identification; B- pulmonary artifacts algorithm for pneumothorax detection.



····· Lung sliding -  
 — Lung sliding +

Figure 12 - Lung point (LP) ultrasound sign.

both lungs in the order anterior-lateral-posterior. In the EFAST sequence, the so called lung point (LP) ultrasound sign (Figure 12) can be searched, with a 98% sensitivity and 100% specificity for pneumothorax identification, as well to determine its volume and extension. LP is the dynamic identification of a chest cavity point, generally during the inspiration, where the LS transition is observed, along with B lines, A lines, identifying the probable pneumothorax. A practical way to perform this maneuver is to start from the posterior region, followed by anterior and lateral. The more lateral the LP is observed, the larger is the pneumothorax, as well as pneumothorax extending to the posterior region may show no LP. It should be underlined that in some situations LS may be absent, with present A lines and no LP, as in atelectasis and close to liver or spleen areas simulating LP in the absence of pneumothorax. These eight

segments ultrasound evaluation may bring relevant data for our patients' management. With the above described method, it is possible to extrapolate the EFAST for pulmonary evaluation,<sup>(33-37)</sup> rendering possible the evaluation of central venous lines insertion-related complications, such as pneumothorax.

### CONCLUSION

The ultrasonography use in the emergency and intensive care settings provides very relevant information which should be interpreted along with the patient's clinical data. Currently full-body CT (foot to head scan) is the preferential method in trauma centers and intensive care units, associated to its indiscriminate and liberal use. CT-related complications are increased risk of cancer and nephrotoxicity, widely described in the literature, and in case of extreme age patients, these frets should be kept in mind. New portable and self-sustaining technologies, such as US devices, are able to use solar energy and to be transmitted in real time to experts (telemedicine). Another advantage would involve its use in inhospitable places and even in intensive care units, where patients transportation is usually not advisable and the diagnosis agility is a plus. Its cost-effectiveness is very relevant, as some high cost tests used for injuries diagnosis add overhead costs to very limited resources regions. The training and certification of professionals involved in critically ill patients' care in Brazil is likely to be seen in a near future, as this tool is currently fully consolidated among European and North American emergency doctors for some years. Thus, the EFAST protocol may be an alternative

for these critical patients' bedside management, keeping in mind that the physical examination and medical reasoning should be connected with complementary methods, but never replaced.

## RESUMO

A principal causa de morte no Brasil, em pacientes com idade inferior a 45 anos, está relacionada ao trauma, sendo responsável por um terço das internações em unidades de terapia intensiva. Em virtude do crescente conhecimento e disponibilidade da ultrassonografia para o diagnóstico e monitoramento de lesões ameaçadoras à vida, como tamponamento cardíaco e ruptura de órgão sólido na cavidade abdominal com choque hemorrágico, foi desenvolvido um protocolo denominado FAST (*Focused Assessment with Sonography for Trauma*) no ambiente de emergência e terapia intensiva. Esta tecnologia está ganhando adeptos por sua reprodutibilidade, ausência de exposição à radiação ao paciente e facilidade

de beira leito. Uma nova complementação a este protocolo, denominada FAST-Estendido, proporciona informações valiosas na condução desses pacientes, ampliando o diagnóstico de doenças antes reservadas à cavidade abdominal e pericárdica, conjuntamente com doenças localizadas na cavidade torácica, em busca de hemotórax, derrame pleural e pneumotórax. Devemos salientar que esta modalidade de exame complementar substitui a tomografia computadorizada e o lavado peritoneal diagnóstico, mas não o retardo de intervenções cirúrgicas. Sua avaliação criteriosa, conjuntamente com dados clínicos, deve nortear as condutas terapêuticas, principalmente em locais inóspitos e/ou com limitações de recursos, como pré-hospitalar, unidades de terapia intensiva em zonas de conflito armado, áreas rurais e/ou geograficamente distantes, nas quais não há disponibilidade de outros métodos de imagem.

**Descritores:** Ultrassonografia/utilização; Trauma; Cuidados intensivos/tendências; Sistemas automatizados de assistência junto ao leito

## REFERENCES

- Centers for Disease Control and Prevention - CDC. National estimates of the ten leading causes of nonfatal injuries. Atlanta (GA): Centers for Disease Control and Prevention; 2004.
- Ten leading causes of death. Atlanta (GA): Centers for Disease Control and Prevention; 2003.
- Kirkpatrick AW, Sirois M, Laupland KB, Liu D, Rowan K, Ball CG, et al. Hand-held thoracic sonography for detecting post-traumatic pneumothoraces: The Extended Focused Assessment with Sonography for Trauma (EFAST). *J Trauma*. 2004;57(2):288-95.
- Lichtenstein DA. Pneumothorax and introduction to ultrasound signs in the lung. In: Lichtenstein DA, Pinsky MR, Jardin F. . General ultrasound in the critically ill. Berlin: Springer; 2002. p. 105-15.
- Peitzman AB, Billiar TR, Harbrecht BG, Kelly E, Udekwu AO, Simmons RL. Hemorrhagic shock. *Curr Probl Surg*. 1995;32(11):925-1002. Review.
- Scalea TM, Rodriguez A, Chiu WC, Brenneman FD, Fallon WF Jr, Kato K, et al. Focused Assessment with Sonography for Trauma (FAST): results from an international consensus conference. *J Trauma*. 1999;46(3):466-72.
- Kirkpatrick AW, Sustic A, Blaivas M. Introduction to the use of ultrasound in critical care medicine. *Crit Care Med*. 2007;35:S123-5.
- Wherrett LJ, Boulanger BR, McLellan BA, Brenneman FD, Rizoli SB, Culhane J, Hamilton P. Hypotension after blunt abdominal trauma: the role of emergent abdominal sonography in surgical triage. *J Trauma*. 1996;41(5):815-20.
- Rozycki GS, Ochsner MG, Schmidt JA, Frankel HL, Davis TP, Wang D, Champion HR. A prospective study of surgeon-performed ultrasound as the primary adjuvant modality for injured patient assessment. *J Trauma*. 1995;39(3):492-8; discussion 498-500.
- Hoff WS, Holevar M, Nagy KK, Patterson L, Young JS, Arrillaga A, Najarian MP, Valenziano CP; Eastern Association for the Surgery of Trauma. Practice management guidelines for the evaluation of blunt abdominal trauma: the EAST practice management guidelines work group. *J Trauma*. 2002;53(3):602-15.
- McElveen TS, Collin GR. The role of ultrasonography in blunt abdominal trauma: a prospective study. *Am Surg*. 1997;63(2):184-8.
- Bode PJ, Edwards MJ, Kruit MC, van Vugt AB. Sonography in a clinical algorithm for early evaluation of 1671 patients with blunt abdominal trauma. *AJR Am J Roentgenol*. 1999;172(4):905-11.
- Thomas B, Falcone RE, Vasquez D, Santanello S, Townsend M, Hockenberry S, et al. Ultrasound evaluation of blunt abdominal trauma: program implementation, initial experience, and learning curve. *J Trauma*. 1997;42(3):380-8; discussion 388-90.
- Gracias VH, Frankel HL, Gupta R, Malcynski J, Gandhi R, Collazzo L, et al. Defining the learning curve for the Focused Abdominal Sonogram for Trauma (FAST) examination: implications for credentialing. *Am Surg*. 2001;67(4):364-8.
- Sarkisian AE, Khondkarian RA, Amirbekian NM,



- Bagdasarian NB, Khojayan RL, Ogenesian YT. Sonographic screening of mass casualties for abdominal and renal injuries following the 1988 Armenian earthquake. *J Trauma*. 1991;31(2):247-50.
16. Beck-Razi N, Fischer D, Michaelson M, Engel A, Gaitini D. The utility of focused assessment with sonography for trauma as a triage tool in multiple-casualty incidents during the second Lebanon war. *J Ultrasound Med*. 2007;26(9):1149-56.
  17. Sargsyan EA, Hamilton DR, Jones JA, Melton S, Whitson PA, Kirkpatrick AW, et al. FAST at MACH 20: clinical ultrasound aboard the International Space Station. *J Trauma*. 2005;58(1):35-9.
  18. Farahmand N, Sirlin CB, Brown MA, Shragg GP, Fortlage D, Hoyt DB, Casola G. Hypotensive patients with blunt abdominal trauma: performance of screening US. *Radiology*. 2005;235(2):436-43.
  19. McKenney KL, McKenney MG, Cohn SM, Compton R, Nunez DB, Dolich M, Namias N. Hemoperitoneum score helps determine need for therapeutic laparotomy. *J Trauma*. 2001;50(4):650-4; discussion 654-6.
  20. Lee BC, Ormsby EL, McGahan JP, Melendres GM, Richards JR. The utility of sonography for the triage of blunt abdominal trauma patients to exploratory laparotomy. *AJR Am J Roentgenol*. 2007;188(2):415-21.
  21. Kirkpatrick AW. Clinician-performed focused sonography for the resuscitation of trauma. *Crit Care Med*. 2007;35(5 Suppl):S162-72. Review.
  22. World Interactive Network Focused on Critical Ultrasound. (WINFOCUS). Ultrasound in critical care medicine - Continuing medical education. [cited 2010 Jul 1]. Available from: <http://www.winfocus.org/usccm>.
  23. Blaivas M, Lyon M, Duggal S. A prospective comparison of supine chest radiography and bedside ultrasound for the diagnosis of traumatic pneumothorax. *Acad Emerg Med*. 2005;12(9):844-9.
  24. Ball CG, Kirkpatrick AW, Laupland KB, Fox DI, Nicolaou S, Anderson IB, et al. Incidence, risk factors, and outcomes for occult pneumothoraces in victims of major trauma. *J Trauma*. 2005;59(4):917-24; discussion 924-5.
  25. Ball CG, Kirkpatrick AW, Laupland KB, Fox DL, Litvinchuk S, Dyer DM, et al. Factors related to the failure of radiographic recognition of occult posttraumatic pneumothoraces. *Am J Surg*. 2005;189(5):541-6; discussion 546.
  26. Rozycki GS, Shackford SR. Ultrasound, what every trauma surgeon should know. *J Trauma*. 1996;40(1):1-4.
  27. Reardon R, Moscati R. Beyond the FAST Exam: additional applications of sonography in trauma. In: Jehle D, Heller M, editors. *Ultrasonography in trauma: the FAST exam*. Dallas, TX: American College of Emergency Physicians; 2003. p. 107-26.
  28. Moscati R, Reardon R. Clinical application of the FAST exam. In: Jehle D, Heller M, editors. *Ultrasonography in trauma: the FAST exam*. Dallas, TX: American College of Emergency Physicians; 2003. p. 39-60.
  29. Rozycki GS, Ochsner MG, Feliciano DV, Thomas B, Boulanger BR, Davis FE, et al. Early detection of hemoperitoneum by ultrasound examination of the right upper quadrant: a multicenter study. *J Trauma*. 1998;45(5):878-83.
  30. Lichtenstein DA, Mezière G, Lascols N, Biderman P, Courret JP, Gepner A, et al. Ultrasound diagnosis of occult pneumothorax. *Crit Care Med*. 2005;33(6):1231-8.
  31. Weinberger SE, Drazen JM. Diagnostic procedures in respiratory diseases. In: Kasper D, editor. *Harrison's principles of internal medicine*. 16th ed. New York: McGraw-Hill; 2005. p. 1505-8.
  32. Melniker LA, Leibner E, McKenney MG, Lopez P, Briggs WM, Mancuso CA. Randomized controlled trial of point-of-care, limited ultrasonography for trauma in the emergency department: the first sonography outcomes assessment program trial. *Ann Emerg Med*. 2006;48(3):227-35.
  33. Noble VE, Nelson B, Sutingco AN. *Manual of emergency and critical care ultrasound*. New York: Cambridge University Press; 2007.
  34. Jones R. Recognition of pneumoperitoneum using bedside ultrasound in critically ill patients presenting with acute abdominal pain. *Am J Emerg Med*. 2007;25(7):838-41.
  35. Lichtenstein DA, Mezière GA. Relevance of lung ultrasound in the diagnosis of acute respiratory failure: the BLUE protocol. *Chest*. 2008;134(1):117-25. 2010.
  36. Nicolaou S, Talsky A, Khashoggi K, Venu V. Ultrasound-guided interventional radiology in critical care. *Crit Care Med*. 2007;35(5 Suppl): S186-97. Review.
  37. Dyer D, Cusden J, Turner C, Boyd J, Hall R, Lautner D, et al. The clinical and technical evaluation of a remote telementored telesonography system during the acute resuscitation and transfer of the injured patient. *J Trauma*. 2008;65(6):1209-16.