

Viviane Cordeiro Veiga<sup>1</sup>, Júlio César de Carvalho<sup>1</sup>,  
Luis Enrique Campodonico Amaya<sup>1</sup>, Marcos  
Sérgio Martins<sup>1</sup>, Salomón Soriano Ordinola Rojas<sup>1</sup>

## Meningitis as a complication of infective endocarditis

*Meningite como complicação de endocardite infecciosa*

1. Neurological Intensive Care Unit, Hospital Beneficência Portuguesa - São Paulo (SP), Brazil.

### ABSTRACT

Although approximately 30% of patients with endocarditis present with neurological complications, the development of meningitis in these patients is rare. This case report describes a female patient who developed meningitis as a complication of mitral valve endocar-

ditis, and surgery was required for this patient due to acute heart failure resulting from the rupture of the chordae tendineae.

**Keywords:** Meningitis/etiology; Endocarditis, bacterial/complications; Cerebrovascular disorders; Case reports

### INTRODUCTION

Neurological complications occur in approximately 30% of patients with infective endocarditis and are often responsible for the high morbidity and mortality rates associated with this clinical condition.<sup>(1-3)</sup> The majority of these complications are associated with diseases of structures on the left side of the heart,<sup>(4)</sup> and many of the clinical manifestations are related to the affected area of the central nervous system.<sup>(4)</sup>

Meningitis in association with infective endocarditis occurs in approximately 2 to 20% of cases.<sup>(5,6)</sup>

### CASE REPORT

A 25-year-old female patient was admitted to the emergency department with signs of convulsive seizures accompanied by a poor general condition, headache, neck stiffness and fever. A complete blood count showed leukocytosis with a left shift. Chest radiography and computed tomography scans of the brain were performed but showed no significant changes. Cerebrospinal fluid was collected and shown to contain 243 leukocytes, 91% of which were neutrophils. Two sets of blood cultures were also collected, but the results were negative. The patient was admitted and administered intravenous antibiotics (ciprofloxacin). This patient had a history of dental treatment 40 days previously but did not receive prophylactic treatment for infective endocarditis.

After 2 days, the patient developed psychomotor agitation and a decreased level of consciousness and was transferred to the intensive care unit (ICU). Upon admission to the ICU, additional laboratory tests were conducted, which showed a persistent left shift in the complete blood count and elevated C-reactive protein levels without electrolyte abnormalities. Additional chest radiographs were performed,

This study was conducted at the Hospital Beneficência Portuguesa de São Paulo - São Paulo (SP), Brazil.

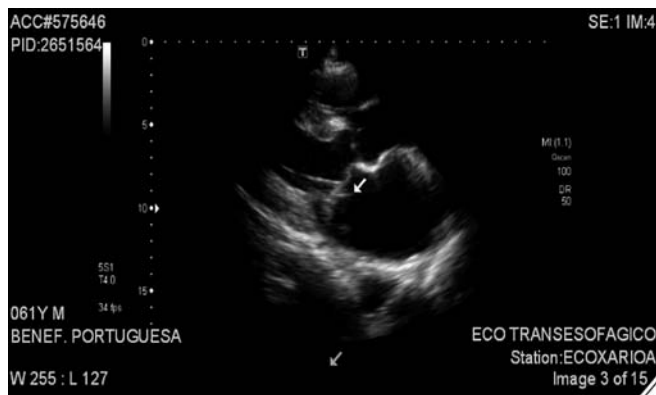
**Conflicts of interest:** None.

Submitted on February 10, 2012  
Accepted on August 1<sup>st</sup>, 2012

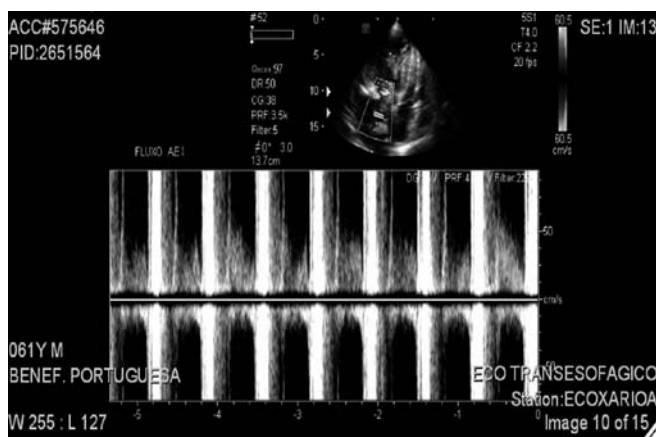
#### Corresponding author:

Viviane Cordeiro Veiga  
Rua Martiniano de Carvalho, 864, cj. 310 - Bela Vista  
Zip Code: 01321-000 - São Paulo (SP), Brazil  
E-mail: viviane.veiga@bpsp.org.br

but no changes were apparent. The neurology team requested nuclear magnetic resonance imaging of the brain and, because of the patient's psychomotor agitation, orotracheal intubation was required for the examination. After the examination was completed without complication, the patient was extubated, and the results demonstrated no significant changes. However, the patient experienced a sudden drop in oxygen saturation and was reintubated. Upon returning to the ICU, she was placed on mechanical ventilation. Pulmonary auscultation revealed crackles in both hemithoraces, and cardiac auscultation revealed a holosystolic murmur of the mitral valve. A chest radiograph showed bilateral interstitial infiltrate and myxomatous degeneration of the mitral valve leaflets with a rupture of the posterior leaflet (Figure 1), whereas transthoracic echocardiography showed severe valvular regurgitation (Figure 2). Clinical measures were introduced to stabilize the patient (a change in the antibiotic regimen by introducing ceftriaxone, gentamicin and vancomycin and removing ciprofloxacin; the introduction of diuretics and inotropics; and the introduction of adequate ventilation parameters), and surgery was indicated.

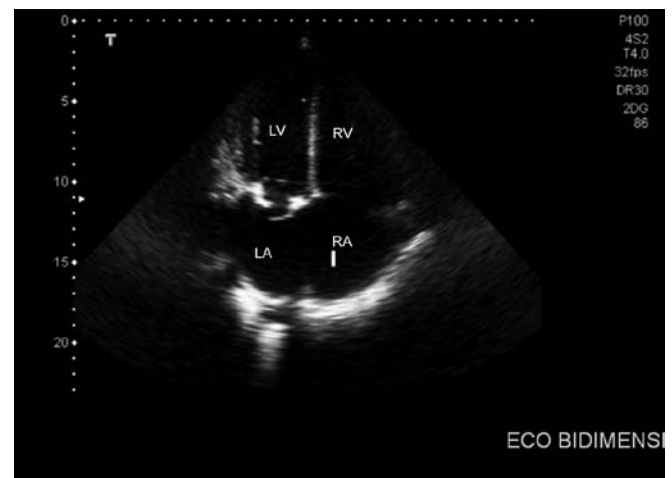


**Figure 1** - Transesophageal echocardiography visualizing the ruptured chordae (white arrow) associated with the posterior leaflet of the mitral valve.



**Figure 2** - Echocardiogram showing severe mitral valve regurgitation, which was related to the ruptured chordae of the posterior leaflet of the mitral valve.

During surgery, an abscess on the posterior mitral valve ring and rupture of the posterior leaflet were verified, and a no. 29 bioprosthetic mitral implant was inserted in the mitral position without any complications. Following the operation, the patient became hemodynamically stable, and an echocardiogram revealed a normofunctioning mitral bioprosthesis without central or periprosthetic regurgitation and preserved ventricular function (Figure 3). However, the patient still presented with symptoms of psychomotor agitation and remained under sedation for 24 hours with dexmedetomidine, which was then slowly withdrawn along with the mechanical ventilation.



**Figure 3** - Transthoracic echocardiogram performed after the operation, demonstrating the bioprosthetic in a normofunctioning mitral position. LV - left ventricle; RV - right ventricle; LA - left atrium; RA - right atrium.

Computed tomography of the brain was performed, which showed diffuse cerebral edema without any other changes, and the sedation was maintained until fifth day after surgery. The patient was extubated on the eighth day following surgery without any hemodynamic changes or neurologic sequelae and maintained a Glasgow Coma Scale score of 15 without any motor or behavioral changes.

## DISCUSSION

Neurologic complications are frequently observed in patients with infective endocarditis. These complications are present in approximately 30% of cases and are responsible for increased morbidity and mortality in these individuals.<sup>(1-3,6)</sup> The clinical presentation of these cases is related to the area of the nervous system affected.<sup>(4)</sup>

Several factors are known to predispose patients with infective endocarditis to embolic complications, including the presence of vegetations on the anterior leaflet of the mitral valve and vegetations larger than 10 mm detected

on an echocardiogram.<sup>(7,8)</sup> In addition, mitral valve lesions have been associated with higher rates of embolic complications compared to aortic valve vegetations (25 and 10%, respectively).

In this case report, the echocardiogram did not reveal the vegetation but instead revealed a related complication: the rupture of the posterior leaflet of the mitral valve, which was also observed in a location different from that frequently described in the literature.

In a recently published multicenter study, Sonnevile et al.<sup>(9)</sup> showed that 55% of patients with endocarditis of the left side presented with at least one neurological complication, the most prevalent of which was ischemic stroke. In addition, meningitis or meningeal reactions were present in 20.7% of cases. In this study, the independent factors associated with neurological complications included infectious endocarditis caused by infection with *Staphylococcus aureus*, endocarditis of the mitral valve and associations with other non-neurological embolic events.

For the patient in the current study, the abscess on the mitral valve ring was evident during surgery, although blood cultures were negative and there were no other embolic events.

Meningitis or the meningeal reaction, as a neurological complication of infective endocarditis, occurs in 2 to 20% of cases and is considered rare in comparison to other neurological complications.<sup>(5)</sup> Clinically, this complication is manifest in most cases by a poor overall condition, fever and neck stiffness. The clinical picture of meningitis may be related to its initial presentation in association with endocarditis, as observed with the current patient. However, this clinical picture may cause errors or delays in diagnosis if the attending physician is unaware of such a possibility.<sup>(5)</sup>

There is currently no consensus among studies as to the surgical indication for cardiac surgery in patients with infective endocarditis and neurological complications; however, many studies have considered heart surgery to be an independent

predictor of a decreased mortality risk.<sup>(6,8,10-12)</sup> Patients who often receive greater benefits from surgery included those with heart failure due to significant aortic or mitral valve regurgitation, valve obstruction or heart fistulas. However, surgery should also be considered in cases of uncontrolled infection and to prevent embolic events in high-risk patients.<sup>(6)</sup> Complications of cardiac surgery, such as the exacerbation of neurological deficits and the aggravation of cerebral edema, should be considered at the time surgery is indicated.<sup>(12)</sup>

According to the consensus of the European Society of Cardiology, published in 2009,<sup>(13)</sup> early surgery to treat endocarditis should be indicated in patients with heart failure (class 1B) or uncontrolled infection (class 1B) and to prevent embolic events (class 1B/C). In situations where transient ischemic attack or silent cerebral embolism is present, surgery should not be postponed (class 1B).

In the case described herein, the indications for early surgery included heart failure due to acute mitral regurgitation caused by a ruptured chordae, and this assessment was believed to be important for the prognosis of the patient.

Meningitis can be associated with the clinical picture of infective endocarditis and should therefore be investigated before acting on a clinical suspicion.

---

## RESUMO

As complicações neurológicas estão presentes em aproximadamente 30% dos pacientes com endocardite infecciosa; no entanto, a meningite apresenta-se como uma complicação rara. Apresenta-se aqui o caso de paciente do gênero feminino com quadro de meningite decorrente de endocardite em valva mitral, que necessitou de procedimento cirúrgico em razão de quadro agudo de insuficiência cardíaca por ruptura de cordoalha valvar.

**Descritores:** Meningite/etiologia; Endocardite bacteriana/complicações; Transtornos cerebrovasculares; Relatos de casos

---

## REFERENCES

- Jorge SV, Medeiros CS, Scuracchio PS, Assef JE, Amoni AS, Sousa JE. Meningite e outras complicações neurológicas na endocardite infecciosa. *Arq Bras Cardiol.* 1992;59(5):379-83.
- Ziment I. Nervous system complications in bacterial endocarditis. *Am J Med.* 1969;47(4):593-607. Review.
- Pruitt AA, Rubin RH, Karchmer AW, Duncan GW. Neurologic complications of bacterial endocarditis. *Medicine (Baltimore).* 1978;57(4):329-43.
- Tunkel AR, Kaye D. Neurologic complications of infective endocarditis. *Neurol Clin.* 1993;11(2):419-40. Review.
- Hermans PE. The clinical manifestations of infective endocarditis. *Mayo Clin Proc.* 1982;57(1):15-21.
- Sonneville R, Mourvillier B, Bouadma L, Wolff M. Management of neurological complications of infective endocarditis in ICU patients. *Ann Intensive Care.* 2011;1(1):10.
- Liphaus BL, Goldenstein-Schainberg C, Kitamura LM, Silva CAA. Aneurisma micótico abdominal e embolia cerebral associados à endocardite infecciosa em paciente com doença valvar reumática crônica. *Arq Bras Cardiol.* 2007;88(1):e7-e9.
- Murdoch DR, Corey GR, Hoen B, Miró JM, Fowler VG Jr, Bayer AS, Karchmer AW, Olaison L, Pappas PA, Moreillon P, Chambers ST, Chu VH, Falcó V, Holland DJ, Jones P, Klein JL, Raymond NJ, Read KM, Tripodi MF, Utili R, Wang A, Woods CW, Cabell CH; International Collaboration on Endocarditis-Prospective Cohort Study (ICE-PCS) Investigators. Clinical presentation, etiology, and outcome of infective endocarditis in the 21st century: the International Collaboration on Endocarditis - Prospective Cohort Study. *Arch Intern Med.* 2009;169(5):463-73.
- Sonneville R, Mirabel M, Hagege D, Tubach F, Vignon P, Perez P, Lavoué S, Kouatchet A, Pajot O, Mekontso Dessap A, Tonnelier JM, Bollaert PE,

- Frat JP, Navellou JC, Hyvernat H, Hssain AA, Tabah A, Trouilet JL, Wolff M; ENDOcardite en REAnimation Study Group. Neurologic complications and outcomes of infective endocarditis in critically ill patients: the ENDOcardite en REAnimation prospective multicenter study. *Crit Care Med*. 2011;39(6):1474-81.
10. Gillinov AM, Shah RV, Curtis WE, Stuart RS, Cameron DE, Baumgartner WA, et al. Valve replacement in patients with endocarditis and acute neurologic deficit. *Ann Thorac Surg*. 1996;61(4):1125-9; discussion 1130.
  11. Rossi M, Gallo A, De Silva RJ, Sayeed R. What is the optimal timing for surgery in infective endocarditis with cerebrovascular complications? *Interact Cardiovasc Thorac Surg*. 2012;14(1):72-80. Review.
  12. Fukuda W, Daitoku K, Minakawa M, Fukui K, Suzuki Y, Fukuda I. Infective endocarditis with cerebrovascular complications: timing of surgical intervention. *Interact Cardiovasc Thorac Surg*. 2012;14(1):26-30.
  13. Habib G, Hoen B, Tornos P, Thuny F, Prendergast B, Vilacosta I, Moreillon P, de Jesus Antunes M, Thilen U, Lekakis J, Lengyel M, Müller L, Naber CK, Nihoyannopoulos P, Moritz A, Zamorano JL; ESC Committee for Practice Guidelines. ESC Committee for Practice Guidelines. Guidelines on the prevention, diagnosis, and treatment of infective endocarditis (new version 2009): the Task Force on the Prevention, Diagnosis, and Treatment of Infective Endocarditis of the European Society of Cardiology (ESC). Endorsed by the European Society of Clinical Microbiology and Infectious Diseases (ESCMID) and the International Society of Chemotherapy (ISC) for Infection and Cancer. *Eur Heart J*. 2009;30(19):2369-413.