

Estevão Bassi<sup>1,2</sup>, Leandro Costa Miranda<sup>1</sup>, Paulo Fernando Guimarães Morando Marzocchi Tierno<sup>1</sup>, César Biselli Ferreira<sup>1</sup>, Filipe Matheus Cadamuro<sup>1</sup>, Viviane Rossi Figueiredo<sup>3</sup>, Maria Cecília de Toledo Damasceno<sup>4,5</sup>, Luiz Marcelo Sá Malbouisson<sup>1</sup>

## Assistance of inhalation injury victims caused by fire in confined spaces: what we learned from the tragedy at Santa Maria

*Atendimento às vítimas de lesão inalatória por incêndio em ambiente fechado: o que aprendemos com a tragédia de Santa Maria*

1. Intensive Care of Surgical Emergencies and Trauma Unit, Hospital das Clínicas, Faculdade de Medicina, Universidade de São Paulo - São Paulo (SP), Brazil.
2. Intensive Care Unit, Hospital Alemão Oswaldo Cruz - São Paulo (SP), Brazil.
3. Department of Bronchoscopy, Instituto do Coração, Hospital das Clínicas, Faculdade de Medicina, Universidade de São Paulo - São Paulo (SP), Brazil.
4. Emergency Department, Hospital das Clínicas, Faculdade de Medicina, Universidade de São Paulo - São Paulo (SP), Brazil.
5. Office of the Secretary, Secretaria de Estado da Saúde de São Paulo - São Paulo (SP), Brazil.

### ABSTRACT

On January 2013, a disaster at Santa Maria (RS) due to a fire in a confined space caused 242 deaths, most of them by inhalation injury. On November 2013, four individuals required intensive care following smoke inhalation from a fire at the *Memorial da América Latina* in São Paulo (SP). The present article reports the clinical progression and management of disaster victims presenting with inhalation injury. Patients ERL and OC exhibited early respiratory failure, bronchial aspiration of carbonaceous material, and carbon monoxide poisoning. Ventilation support was performed with 100% oxygen, the aspirated material was removed by bronchoscopy, and cyanide poisoning was empirically treated with sodium nitrite and sodium thiosulfate. Patient RP initially exhibited cough and retrosternal burning and subsequently progressed to respiratory failure due to upper airway swelling and early-onset

pulmonary infection, which were treated with protective ventilation and antimicrobial agents. This patient was extubated following improvement of edema on bronchoscopy. Patient MA, an asthmatic, exhibited carbon monoxide poisoning and bronchospasm and was treated with normobaric hyperoxia, bronchodilators, and corticosteroids. The length of stay in the intensive care unit varied from four to 10 days, and all four patients exhibited satisfactory functional recovery. To conclude, inhalation injury has a preponderant role in fires in confined spaces. Invasive ventilation should not be delayed in cases with significant airway swelling. Hyperoxia should be induced early as a therapeutic means against carbon monoxide poisoning, in addition to empiric pharmacological treatment in suspected cases of cyanide poisoning.

**Keywords:** Disasters; Respiratory insufficiency/etiology; Urban fires; Intoxication/etiology; Case reports

**Conflict of interest:** None.

Submitted on June 15, 2014  
Accepted on October 28, 2014

### Corresponding author:

Luiz Marcelo Sá Malbouisson  
Avenida Doutor Enéas de Carvalho Aguiar,  
255 - Cerqueira César  
Zip code: 05403-001 - São Paulo (SP), Brazil  
E-mail: luiz.malbouisson@hc.fm.usp.br

**Responsible editor:** Luciano César Pontes de Azevedo

DOI: 10.5935/0103-507X.20140065

### INTRODUCTION

On January 2013, a disaster at Santa Maria (RS) due to a fire in a confined space caused 242 deaths.<sup>(1,2)</sup> Good organization and rapid assistance were crucial to prevent an even worse tragedy. The experience and knowledge afforded by that event, particularly concerning inhalation injury due to fires in confined spaces, should be utilized to improve care under similar circumstances.

On November 29 of the same year, a fire occurred in a confined space at the *Memorial da América Latina* in São Paulo (SP); the fire arose from burned acoustic insulation foam, which evoked several characteristics of the tragedy

at Santa Maria. This time, however, the victims were the firemen called to extinguish the fire; none of them exhibited significant burns on the body surface, but four required intensive care due to inhalation injury. Various consequences of inhalation injury were detected and treated: carbon monoxide poisoning, cyanide poisoning, airway burns, and bronchospasm. In the present article, we report these cases and how they were managed, followed by a discussion on inhalation injury.

## CASE REPORTS

### Case 1

ERL, 43 years old, no significant past history, estimated length of exposure to inhalation injury 20 to 30 minutes, and loss of consciousness on the premises. Intubation was performed for airway protection before transport. Upon admission to the hospital, ERL was sedated; his pupils were equal and reactive to light, the oxygen saturation (SatO<sub>2</sub>) was 95% with fraction of inspired oxygen (FiO<sub>2</sub>) 100%, positive end-expiratory pressure (PEEP) 6 mmHg, bilaterally symmetric findings on auscultation, large amounts of carbonaceous tracheal secretion in the orotracheal tube, heart rate (HR) 75bpm, and blood pressure (BP) 100/60mmHg. Standardized life support was performed in the emergency department following the recommendations of Advanced Trauma Life Support (ATLS).<sup>(3)</sup> No signs of traumatic injury were found in any other organ, except for inhalation injury.

The results of the initial arterial blood gas (ABG) at FiO<sub>2</sub> 100% are described in table 1. No significant changes were revealed on the chest radiograph. The problems detected were possible airway burn, inhalation of coarse particulate material (soot), and poisoning by carbon monoxide (the product of which is carboxyhemoglobin - COHb). Relative to the investigation of cyanide poisoning, serum measurement was not promptly feasible and available, as treatment had to be started as soon as possible to maximize its clinical benefits. The neurological symptoms associated with cyanide poisoning could not be assessed because the patient was sedated and undergoing invasive mechanical ventilation. The chosen therapeutic strategies were partially based on the experience of the staff members who assisted the victims of the tragic fire at Santa Maria as follows:

Catheter placement for invasive blood pressure (IBP) monitoring; frequent arterial blood gases (ABG) assessment (every three hours during the first 24 hours

and then at longer intervals according to the clinical progression). The estimated SatO<sub>2</sub>, fraction of COHb in the total hemoglobin (expressed as a percentage - FCOHb) and fraction of methemoglobin (MetHb) in the total hemoglobin (expressed as a percentage - FmetHb) were continually recorded at the bedside using a specific oximeter, the Masimo Radical-7®. The initial ABG showed that the FCOHb was 27% (reference values - RV: 0.5-2.5%) and the FmetHb was 0.02% (RV <3%) (Table 1).

Hyperoxia with FiO<sub>2</sub> 100% to treat the carbon monoxide (and possible cyanide) poisoning and protective ventilation restricted to a tidal volume of 6 mL/kg and permissive hypercapnia if necessary to avoid additional lung damage were used. Normobaric hyperoxia was discontinued approximately 12 hours after the onset of treatment (the FCOHb became <5% six hours after the onset of treatment).

Daily bronchoscopy was performed during the first days at the hospital to remove the large amount of coarse carbonaceous material in the airways, which contributes to perpetuate inflammation and facilitates lung infection.<sup>(1,4,5)</sup> This strategy was continued until the amount of the material was significantly reduced.

As the risk of cyanide poisoning was high, due to the burning of wood and plastic at the fire site, prolonged exposure to smoke, the presence of particulate material in the airways, and hyperlactatemia, empirical treatment was started immediately after admission to the ICU. The treatment consisted of sodium nitrite 300mg per intravenous (IV route) for 20 minutes + sodium thiosulfate 12.5 IV for 10 minutes. The plasma level of cyanide in the sample collected at the ICU admission was 1.1mg/mL (RV: <0.1mg/L), which confirmed the hypothesis. Administration of sodium nitrite might induce or aggravate methemoglobinemia in patients at risk. For this reason, administration was begun only after concomitant methemoglobinemia was ruled out based on the ABG results. This aspect of treatment should be systematically taken into account before its infusion.

On day three, the patient exhibited bilateral basilar infiltrates on the chest radiograph, worsening of the lung secretion, fever, leukocytosis, and elevated C-reactive protein. The diagnosis was early-onset ventilator-associated pneumonia (VAP), and ceftriaxone and clindamycin were started; the patient was weaned from mechanical ventilation and extubated. On day six, the antibiotic regimen was changed to oxacillin and ciprofloxacin based on the microorganisms isolated from the bronchoalveolar

**Table 1** - Patients' arterial blood gases

Patient/ $\Delta$ T	pH	PO <sub>2</sub>	FiO <sub>2</sub>	PO <sub>2</sub> /FiO <sub>2</sub>	SatO <sub>2</sub>	FO <sub>2</sub> Hb	FCOHb	FmethHb	Lactate
ERL 0 h	7.29	76	100	76	96	68	27	0	43
ERL 6 h	7.38	344	100	344	100	96	2	0	22
ERL 12 h	7.42	302	100	302	99	98	1	0	22
ERL 24 h	7.47	154	60	256	99	98	0	0	17
OC 0 h	7.39	352	100	352	100	73	26	2	70
OC 6 h	7.29	250	100	250	99	96	2	1	10
OC 12 h	7.34	303	100	303	100	98	1	1	12
OC 24 h	7.40	151	40	377	99	98	0	1	24
RP 0 h	7.45	135	100	135	99	91	7	1	16
RP 6 h	7.26	234	100	234	98	96	2	2	11
RP 12 h	7.40	249	100	249	100	98	1	1	14
RP 24 h	7.35	173	55	315	100	97	1	1	20
MA 0 h	7.39	70	21	333	95	85	10	5	10
MA 6 h	7.38	65	21	309	92	89	1	8	9
MA 12 h	7.38	67	21	319	92	91	0	8	11
MA 24 h	7.40	145	35*	414*	99	97	1	1	17

$\Delta$ T - estimated time elapsed between admission to intensive care unit and sample collection; PO<sub>2</sub> - partial pressure of oxygen (reference values: 80-100 mmHg); FiO<sub>2</sub> - fraction of inspired oxygen; PO<sub>2</sub>/FiO<sub>2</sub> - PO<sub>2</sub>/FiO<sub>2</sub> ratio; SatO<sub>2</sub> - oxygen saturation (reference values: 95-98%); FO<sub>2</sub>Hb - fraction of oxyhemoglobin in total hemoglobin (reference values: 95-99%); FCOHb - fraction of carboxyhemoglobin in total hemoglobin (reference values: 0.5-2.5%); FmethHb - fraction of methemoglobin in total hemoglobin (reference values: <3%); Lactate (reference values: 4.5-14.4mg/dL). \* Oxygen supplied by means of Venturi-like mask.

lavage (BAL) fluid (oxacillin-sensitive *Staphylococcus aureus* and gram-negative bacilli difficult to identify by conventional methods). The patient exhibited progressive improvement in his clinical status and inflammatory parameters and was discharged from the ICU on day nine; he was discharged from the hospital after a 10-day stay with full functional recovery.

## Case 2

OC, 33 years old, no significant past history, estimated length of exposure to inhalation injury 20 to 30 minutes and loss of consciousness in the scene. The patient was intubated before transport, as signs of airway burns were already identified on the premises. Upon admission to the hospital, he was sedated, pupils were equal and reactive to light, SatO<sub>2</sub> 98%, with FiO<sub>2</sub> 100% and PEEP 8mmHg. Large amounts of carbonaceous tracheal secretion were observed in the orotracheal tube. The patient exhibited hypotension and tachycardia, for which reason 1.500mL of Ringer's solution was infused and norepinephrine (0.10mcg/kg/minute) was begun to achieve hemodynamic stabilization. Following standardized life support according to the ATLS, no other trauma injury was detected.

The initial ABG at FiO<sub>2</sub> 100% revealed FCOHb 26% and FmethHb 1.5% (Table 1). The initial chest radiograph did not evidence significant abnormalities.

Based on the accident characteristics and clinical manifestations similar to those of patient ERL, the management was the same as in the case above, including empirical treatment of cyanide poisoning (subsequently, the serum cyanide level was found to be 0.1mg/L, RV: <0.1mg/L) and frequent bronchoscopy to remove the carbonaceous material from the airway. FCOHb fell to 2%, and the lactate levels returned to normal six hours after the onset of treatment; FCOHb fell to 1% 12 hours after admission (Table 1).

Although the patient's ventilation exhibited progressive improvement, intubation was maintained until day six, when significant improvement of the upper airway swelling caused by inhalation injury was observed on bronchoscopy. Systemic corticosteroids were administered over three days to reduce the upper airway swelling. On day seven, growth of oxacillin-sensitive *S. aureus* was reported in the BAL fluid (>100,000 CFU). Although the patient was stable, he had hyperthermia, and his lungs still exhibited bilateral opacity and purulent secretion. Therefore, treatment with oxacillin was started. As an additional complication during his ICU stay, the patient exhibited hyperactive *delirium* requiring pharmacological control using dexmedetomidine and haloperidol. He was discharged to a general ward on day 10 and from the hospital on day 14, with full functional recovery.

### Case 3

RP, 37 years old, without history of disease, was exposed for 15 minutes while not wearing a protective gas mask in a confined space while rescuing colleagues. On the initial assessment, the airway was patent, and the patient was not wearing a cervical collar and exhibited good oxygenation at room air, no abnormalities on lung auscultation, BP 110/70mmHg, HR 64bpm, good peripheral perfusion, full responsiveness, no motor deficits, and no signs of traumatic injury. He complained of "sooty" sputum, oropharyngeal discomfort, and retrosternal burning, which were worse upon swallowing liquids. A few hours after admission to the hospital for observation, he exhibited stridor, together with signs of upper airway obstruction and a requirement for orotracheal intubation. Bronchoscopy detected grade I diffuse erythema of the mucous membrane and no carbonaceous material. Bilateral basilar opacity was found on the chest radiograph, being more severe in the right lung. The ABG results are described in table 1; the initial FCOHb was 7%.

Because the length of exposure was shorter and not attended by loss of consciousness, there were no signs of severe carbon monoxide poisoning or coarse particulate material in the bronchia. The main problems exhibited by the patient were due to airway swelling and lung injury ( $PO_2/FiO_2$  ratio: 135). In addition to the abovementioned findings, after two days on mechanical ventilation, a large amount of purulent secretion was eliminated through the orotracheal tube and the inflammatory markers increased. Treatment for early-onset VAP was started with ceftriaxone and clindamycin. These antibiotics were maintained because community pathogens were isolated from the culture (multi-drug sensitive *Streptococcus pneumoniae* >1,000,000 CFU/mL and *Haemophilus influenzae* >1,000,000 CFU/mL). The patient was also given systemic corticosteroids for approximately 72 hours to reduce the airway swelling. Exhibiting clinical improvement, the patient was extubated on day four and discharged from the ICU on day six and from the hospital on day seven, with full functional recovery.

### Case 4

MA, 46 years old, smoker with a history of asthma (irregularly using formoterol and budesonide inhalation puffs). He participated in the rescue of colleagues and was exposed to smoke for approximately five minutes. Initial care followed the ATLS protocol as follows: airway patency, without a cervical collar,  $SatO_2$  96% at room air,

respiratory rate 16 breaths per minute, no abnormalities on heart and lung auscultation, HR 78bpm, BP 150/70mmHg, and Glasgow Coma Scale score of 15, without deficits, without excoriations, without signs of smoke inhalation, and without complaints.

During the period of observation at the emergency department, the patient began to complain of dyspnea and presented signs of considerable bronchospasm, without significant findings on the chest radiograph.

The patient was admitted to the ICU to achieve stabilization. He was treated for severe bronchospasm with systemic corticosteroids and inhaled bronchodilators (fenoterol and ipratropium), in addition to a short period of oxygen therapy to induce hyperoxia as treatment for high FCOHb (10% on the initial ABG). The respiratory problems improved quickly, and the FCOHb fell to 2% six hours after admission to the ICU. MA was discharged from the ICU on day four and from the hospital on day five, with full functional recovery. The ABG progression is described in table 1.

Figure 1 summarizes the progression of the COHb and lactate levels in all four patients.

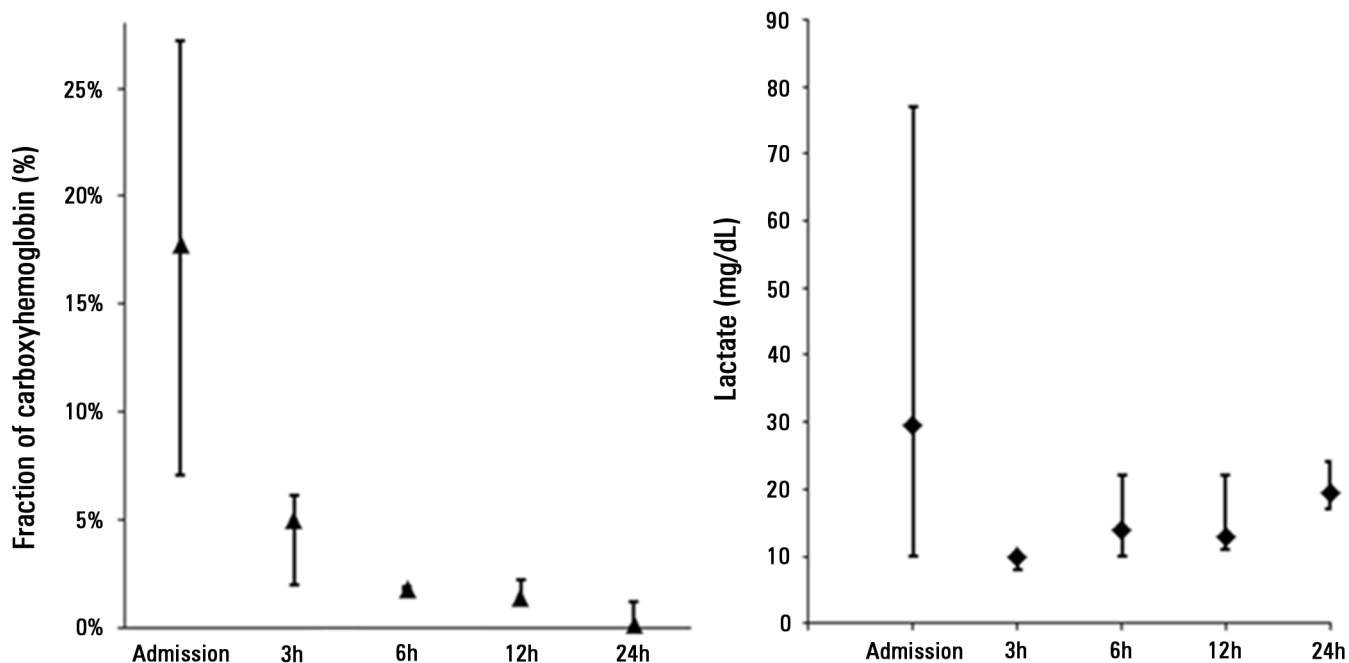
## DISCUSSION

All the patients exhibited inhalation injury after exposure to the fire and recovered well following pre-hospital and intensive support care. Nevertheless, inhalation injury is a severe complication in burned individuals or victims of fires in confined spaces and is a relevant cause of morbidity and mortality. One of the factors that contribute to such problems is lung dysfunction, which might rapidly lead to hard-to-manage hypoxemia and poisoning by inhaled toxic subproducts, such as carbon monoxide and cyanide. Early recognition and treatment of poisoning are crucial for the patients' recovery.

Here, we briefly discuss certain aspects relative to the diagnosis and treatment of inhalation injury. In Brazil, DATASUS reported more than 14,000 admissions to hospitals (from November 2012 to October 2013) due to fires or burns, with 4% mortality and costs of over BRL 32 millions.<sup>(6)</sup> Fires in confined spaces might be associated with additional complications because they can easily induce systemic poisoning. A recent study detected inhalation injury in 45% of individuals with severe burns admitted to a specialized Brazilian ICU.<sup>(7)</sup>

The pathophysiology includes three different types of lesions:<sup>(1)</sup> (1) Thermal lesions, which consist of direct cell injury associated with considerable swelling and complicate the first 24 hours of treatment. The presence of soot and





**Figure 1** - Progression of the fraction of carboxyhemoglobin and the serum lactate concentration in the studied patients. Results are expressed as the median  $\pm$  variation (minimum and maximum values). The fraction of carboxyhemoglobin decreased quickly once hyperoxia was established, returning to the normal values approximately six hours after admission. The lactate clearance was also rapid, followed by discrete elevation beginning 24 hours after admission; one of the probable causes of the latter is secondary aggression due to pulmonary infectious insult, which occurred in three of the four patients. FCOHb - fraction of carboxyhemoglobin in the total hemoglobin (%); lactate (mg/dL).

face burns are suggestive of a thermal lesion; the upper airways are frequently affected. (2) Chemical lesions, which appear when particles are aspirated and reach the lower airways (bronchia and bronchioles), where they cause inflammation with consequent neutrophilic infiltration and release of proteases and free radicals. As an inflammatory condition, a thermal lesion tends to appear within 12 to 36 hours; it is manifested by bronchorrhea and bronchospasm. Desquamation of the airway mucosa secondary to chemical lesions causes atelectasis and increases the odds of infection, in addition to airway obstruction, and leads to barotrauma in rare occasions. (3) Systemic poisoning, which is the main and most lethal problem. The most common causes of poisoning are carbon monoxide and cyanide, which occur frequently in confined spaces.

At the time of the initial assessment, early intubation should be considered when signs of considerable airway swelling are present,<sup>(3,4)</sup> including stridor, use of accessory muscles, respiratory distress, hypoventilation, and face or neck burns. During the assessment of breathing, the  $\text{FiO}_2$  should be kept at 100% to correct the hypoxemia resulting from the low oxygen concentration in the inspired air in fire environments (in confined spaces, the  $\text{FiO}_2$  might be as low as 15%).

Assessment of circulation should be performed according to the ATLS protocol; hemodynamic instability should be treated aggressively, and fluid resuscitation should follow the guidelines for burned individuals based on the body surface. In addition, service routines (e.g., the Parkland formula) may be used.<sup>(8)</sup>

Victims of fires with inhalation injury require intensive observation during the first 24 hours. Particular attention should be paid to neurological examination because the level of consciousness is frequently reduced by hypoxemia/hypercapnia or poisoning (carbon monoxide/cyanide/methemoglobin). Bronchospasm may occur, especially in individuals with bronchial hyperreactivity.<sup>(4)</sup> The laboratory assessment should include ABG with measurement of the saturation of oxyhemoglobin and carboxyhemoglobin, presence of methemoglobin, and lactate level. Chest radiographs are crucial to assess the damage to the lung parenchyma and the eventual occurrence of obstruction by foreign bodies or of pulmonary secretions with plugs.

Following the initial assessment, the patient should be admitted to the ICU for continuous monitoring. Airway swelling usually occurs within the first 24 hours, but it might appear as late as five days after the accident.

Two of the patients described here (cases 2 and 3) exhibited considerable airway swelling on bronchoscopy and were treated with corticosteroids for approximately 72 hours to accelerate the resolution of edema, thus allowing for early extubation. Although corticosteroids prove efficacious to reduce some types of airway swelling under definite clinical conditions, such as post-extubation edema,<sup>(9)</sup> we should emphasize that there is no evidence in the literature supporting routine application of this strategy in cases with inhalation injury or burns.

Chemical injury causes increased pulmonary secretions during the first days, which might result in bronchorrhea, bronchospasm, cough, and dyspnea. Physical therapy and inhaled beta-agonists combined with ipratropium bromide represent the choice treatment. When soot or particles are detected at the initial assessment (and consequent intubation), bronchoscopy is usually recommended to remove those materials, thus minimizing inflammation and possibly lung infection.<sup>(1,4,5)</sup>

Recovery of the lung function might be slow in patients with inhalation injury; late complications due to the loss of the bronchial epithelium are frequent. Some of the complications that might occur within the first 10 days are atelectasis, pulmonary infection, and acute respiratory distress syndrome. These complications should be treated with physical therapy and antibiotics and according to the recommended guidelines for mechanical ventilation.<sup>(10)</sup>

### Carbon monoxide poisoning

Any patients suspected of airway burns due to inhalation should be assumed to have carbon monoxide poisoning; carbon monoxide is a sub-product of incomplete combustion. As mentioned above, the main treatment for this condition consists of administering complementary oxygen (at FiO<sub>2</sub> 100%) whenever possible.

The affinity of hemoglobin for carbon monoxide is approximately 200 times higher than that for oxygen. Therefore, the oxygen-hemoglobin dissociation curve shifts to the left, with reduction of the oxygen supply to the tissues due to impairment of the oxygen-carrying capacity of hemoglobin and inefficient release of the O<sub>2</sub> molecule at the tissue level.<sup>(1)</sup>

The symptoms of carbon monoxide poisoning include headache, nausea, nonspecific discomfort, cognitive impairment, dyspnea, *angina pectoris*, seizures, coma, arrhythmia, and eventually heart failure. The presence of signs and symptoms of hypoxemia and of low cardiac output with normal oximetry values is striking. The reason

for that paradox is that pulse oximeters cannot distinguish between carboxyhemoglobin and oxyhemoglobin. Moreover, the partial pressure of oxygen (pO<sub>2</sub>) in ABG is usually normal because it does not reflect the amount of oxygen-saturated hemoglobin, which is mainly responsible for the amount of oxygen in the plasma. Consequently, in cases of suspected inhalation injury, ABG must include the value of carboxyhemoglobin saturation, which has a normal range of up to 3% in healthy individuals and increases to as high as 15% among smokers.<sup>(1,11)</sup>

The half-life of carboxyhemoglobin in the plasma is effectively reduced four to six times by administering oxygen at FiO<sub>2</sub> 100%, which should be maintained until the carboxyhemoglobin level becomes close to normal (<3%).<sup>(12)</sup>

Use of a hyperbaric chamber might further reduce the carboxyhemoglobin half-life because many authors advocate this therapy to minimize the late neurological sequelae often induced by carbon monoxide poisoning.<sup>(13)</sup> The benefits of this procedure appear to be greatest in the cases with carboxyhemoglobin levels above 25%, especially within the first six hours after exposure.<sup>(1)</sup> Nevertheless, currently, there is no sound evidence favorable for routine use,<sup>(11,14)</sup> and a meta-analysis conducted in 2011 was unable to report definitive conclusions on this matter.<sup>(15)</sup>

Therefore, most experts recommend that the indication of hyperbaric oxygen therapy should always be considered or discussed in cases of carbon monoxide poisoning.<sup>(1,4,11)</sup>

### Cyanide poisoning

The experience afforded by the events at Santa Maria in 2013, where 242 deaths occurred on the premises,<sup>(1,2)</sup> shows that cyanide poisoning should strongly be suspected in fires in confined spaces, as early treatment is crucial under those conditions. Cyanide is produced when nitrogen-containing products, such as synthetic polymers, paper, polyurethane and wool, are burned.<sup>(1,4)</sup>

The initial symptoms are headache, nausea, and tachypnea, which might be followed by bradycardia, shock, altered state of consciousness, coma, and central apnea. Different from carbon monoxide, which impairs the oxygen supply, cyanide causes hypoxia by blocking the mitochondrial respiratory chain (complex IV), severely limiting the production of high-energy phosphate compounds. The result is severe tissue hypoxia, with lactic acidosis and increased central venous oxygen saturation. The lactate levels are correlated with the severity of poisoning.<sup>(16)</sup>

Measurement of the serum cyanide levels provides diagnostic confirmation; however, this test requires much time and is poorly available. Consequently, empirical treatment should be begun whenever poisoning is suspected. Treatment consists of providing oxygen at 100% (as an attempt to correct the tissue hypoxia) and administering antidotes.<sup>(1,4,12,17)</sup> Hyperbaric hyperoxia may be used, particularly within the first 24 hours. Hydroxocobalamin combines with cyanide to form cyanocobalamin (vitamin B12), which is excreted in the urine; it should be used at a dose of 100mg/kg IV (or 5g, when the body weight is unknown). Hydroxocobalamin is not commercially available in Brazil in formulations adequate for treating cyanide poisoning.

Sodium nitrite induces the formation of methemoglobin, for which the affinity of cyanide is greater compared with complex IV cytochrome c oxidase. Administration of sodium nitrite seeks to reduce cyanide binding to the mitochondria. This agent should be cautiously administered to fire victims due to the obvious risk of methemoglobinemia aggravating the tissue hypoxia. Sodium nitrite should be used at a dose of 300mg (in adults); a second dose of 150mg might be administered 30 minutes later. Sodium thiosulfate behaves as a sulfur donor in the conversion of cyanide into thiocyanate, which is excreted in the urine. The usual dose of this agent is 12.5g IV (maximum speed: 1.25g/minute). The onset of action is slow, and the drug penetration through the blood-brain barrier and into the mitochondria is poor, for which reason its action is limited. A further possibility is dicobalt edetate, which is chemically similar to the iron ions to which cyanide binds. However, this drug is poorly tolerated and is associated with considerable side effects; therefore, its use is restricted to confirmed and severe cases of cyanide poisoning. The usual dose is 300mg and might be repeated based on the clinical response.

### Methemoglobinemia

Methemoglobin (MetHb) is an oxidized form of hemoglobin, in which iron is in the ferric state ( $Fe^{3+}$ ). MetHb exhibits two functional alterations: inability to carry oxygen and shifting of the hemoglobin-oxygen dissociation curve to the left. Both alterations result in tissue hypoxia, with the severity of the complications proportional to the serum MetHb levels.<sup>(12,18)</sup> Values less than 3% are considered normal. With values of 3 to 15%, patients are asymptomatic, but the skin might have grayish

hue, or the color of the blood might change. With levels of 15 to 70%, symptoms appear progressively parallel to the increase in the MetHb concentration and include cyanosis, dyspnea, headache, metabolic acidosis, seizures, and coma. When the levels exceed 70%, the outcome is usually fatal.

Any oxidant might induce MetHb formation, including drugs, pesticides, chemicals and smoke inhalation. The latter is a rather uncommon cause of methemoglobinemia and seldom requires specific treatment.

Treatment is oriented by the patient's symptoms and the MetHb levels. In mild cases, treatment consists of the administration of supplemental oxygen in high concentrations. Once the causal agent disappears, the MetHb returns to normal in approximately 36 hours. In patients with severe symptoms or MetHb >30%, treatment with methylene blue or transfusion of packed red blood cells may be recommended. The initial dose of methylene blue is 1 to 2mg/kg IV for five minutes. Exceptional treatments include exchange transfusion, ascorbic acid, and hyperbaric oxygen therapy.<sup>(12,18)</sup> None of the cases reported here exhibited methemoglobinemia.

Table 2 summarizes the treatments suggested for the types of inhalation injury that are most commonly associated with fires in confined spaces.

**Table 2** - Summary of specific treatments suggested for inhalation injury from fires in confined spaces

Airway swelling: intubation and invasive ventilation support. There is no evidence for routine use of corticosteroids to accelerate resolution of edema in this condition.
Inhalation of particulate material: bronchoscopy for diagnostic purposes and to remove carbonaceous material. <sup>(1,4,5)</sup> Repeat this treatment according to clinical judgment.
Carbon monoxide poisoning: oxygen at 100% until the carboxyhemoglobin level returns to normal (<3%) and the patient becomes asymptomatic (six hours are usually sufficient). Consider hyperbaric therapy as a function of the site where care is provided and the availability of this resource, especially for patients with carboxyhemoglobin >25%, severe metabolic acidosis, neurological symptoms, or signs of acute coronary ischemia <sup>(1,4,11)</sup>
Cyanide poisoning: oxygen at 100% when suspected. Pharmacological treatment options include the following: hydroxocobalamin 100mg/kg IV; sodium nitrite 300mg (in the absence of suspected or confirmed methemoglobinemia); sodium thiosulfate 12.5g IV, usually after sodium nitrite infusion; and dicobalt edetate 300mg, less used due to side effects. Use of hyperbaric therapy is still controversial. <sup>(1,4,12,17)</sup>
Methemoglobinemia: Severe methemoglobinemia is rare in inhalation injury from fires in confined spaces. Treatment consists of supplemental oxygen at 100% in mild cases; in symptomatic cases or when the methemoglobin is >30%, methylene blue 1-2mg/kg IV over 5 minutes is indicated. Exceptional therapeutic options for refractory cases include hyperbaric oxygen therapy and exchange transfusion. <sup>(12,18)</sup>

## Long-term follow up

Neurological sequelae, such as memory disorders, depression, anxiety, paresthesia, and extrapyramidal syndromes, are described in cases with severe exogenous poisoning due to inhalation of the aforementioned subproducts, particularly carbon monoxide and cyanide.<sup>(13,19)</sup> Because respiratory sequelae are also frequent, long-term follow up and the rehabilitation of patients have paramount importance.<sup>(2)</sup>

Assessment after a three-month follow-up did not detect significant cognitive or respiratory sequelae in any

of the four patients reported in the present article, as they all exhibited satisfactory functional recovery.

## CONCLUSION

Inhalation injury has a preponderant role in fires in confined spaces. Invasive ventilation should not be delayed in cases with significant airway swelling. Hyperoxia should be induced early as a therapeutic means against carbon monoxide poisoning, as should empiric pharmacological treatment of suspected cases of cyanide poisoning.

## RESUMO

Em janeiro de 2013, uma catástrofe ocorrida em Santa Maria (RS), decorrente de um incêndio em ambiente fechado, resultou em 242 mortes, a maioria por lesões inalatórias. Em novembro de 2013, quatro vítimas necessitaram de suporte intensivo após inalação de fumaça em incêndio no Memorial da América Latina, em São Paulo (SP). Este artigo relata a evolução clínica e o manejo dos pacientes com lesão inalatória vítimas de uma catástrofe. Os pacientes ERL e OC apresentaram insuficiência respiratória precoce com broncoaspiração de material carbonáceo e intoxicação por monóxido de carbono. Foi instituído suporte ventilatório com oxigênio a 100%, retirada do material aspirado por broncoscopia, e terapia empírica com nitrato de sódio e tiossulfato de sódio para intoxicação por cianeto. O paciente RP apresentou tosse e queimação retroesternal. Evoluiu com insuficiência respiratória por edema de via aérea alta e infecção pulmonar precoce, manejados com ventilação pulmonar

protetora e antimicrobianos. Foi extubado após melhora do edema no seguimento broncoscópico. O paciente MA, asmático, apresentou intoxicação por monóxido de carbono e broncoespasmo, sendo tratado com hiperóxia normobárica, broncodilatadores e corticoterapia. A estadia na unidade de terapia intensiva variou de 4 e 10 dias, e todos os pacientes apresentaram boa recuperação funcional no seguimento. Em Conclusão, nos incêndios em ambientes fechados, as lesões inalatórias têm papel preponderante. O suporte ventilatório invasivo não deve ser postergado em caso de edema significativo de via aérea. A hiperóxia deve ser instituída precocemente como terapêutica para intoxicação por monóxido de carbono, bem como terapia farmacológica empírica para intoxicação por cianeto em caso de suspeita.

**Descritores:** Desastres; Insuficiência respiratória/etiologia; Incêndios urbanos; Intoxicação/etiologia; Relatos de casos

## REFERENCES

- Antonio AC, Castro PS, Freire LO. Smoke inhalation injury during enclosed-space fires: an update. *J Bras Pneumol*. 2013;39(3):373-81.
- Martins de Albuquerque I, Schmidt Pasqualoto A, Trevisan ME, Pereira Gonçalves M, Viero Badaró AF, Potiguara de Moraes J, et al. Role of physiotherapy in the rehabilitation of survivors of the Kiss nightclub tragedy in Santa Maria, Brazil. *Physiotherapy*. 2013;99(4):269-70.
- ATLS Subcommittee; American College of Surgeons' Committee on Trauma; International ATLS working group. Advanced trauma life support (ATLS®): the ninth edition. *J Trauma Acute Care Surg*. 2013;74(5):1363-6.
- Dries DJ, Endorf FW. Inhalation injury: epidemiology, pathology, treatment strategies. *Scand J Trauma Resusc Emerg Med*. 2013;21:31. Review.
- Carr JA, Phillips BD, Bowling WM. The utility of bronchoscopy after inhalation injury complicated by pneumonia in burn patients: results from the National Burn Repository. *J Burn Care Res*. 2009;30(6):967-74.
- Ministério da Saúde. DATASUS. Informações de Saúde (TABNET). Disponível em: <http://www2.datasus.gov.br/DATASUS/index.php?area=02>. Acesso em 03 de junho de 2014.
- de Campos EV, Park M, Gomez DS, Ferreira MC, Azevedo LC. Characterization of critically ill adult burn patients admitted to a Brazilian intensive care unit. *Burns*. 2014 pii: S0305-4179(14)00122-3. [Epub ahead of print]
- Greenhalgh DG. Burn resuscitation: the results of the ISBI/ABA survey. *Burns*. 2010;36(2):176-82.
- McCaffrey J, Farrell C, Whiting P, Dan A, Bagshaw SM, Delaney AP. Corticosteroids to prevent extubation failure: a systematic review and meta-analysis. *Intensive Care Med*. 2009;35(6):977-86.
- Barbas CS, Isola AM, Farias AM, Cavalcanti AB, Gama AM, Duarte AC, et al. Brazilian recommendations of mechanical ventilation 2013. Part I. *Rev Bras Ter Intensiva*. 2014;26(2):89-121.
- Hampson NB, Piantadosi CA, Thom SR, Weaver LK. Practice recommendations in the diagnosis, management, and prevention of carbon monoxide poisoning. *Am J Respir Crit Care Med*. 2012;186(11):1095-101.
- Brooks DE, Levine M, O'Connor AD, French RN, Curry SC. Toxicology in the ICU: Part 2: specific toxins. *Chest*. 2011;140(4):1072-85.
- Kudo K, Otsuka K, Yagi J, Sanjo K, Koizumi N, Koeda A, et al. Predictors for delayed encephalopathy following acute carbon monoxide poisoning. *BMC Emerg Med*. 2014;14:3.



14. Annane D, Chadda K, Gajdos P, Jars-Guincestre MC, Chevret S, Raphael JC. Hyperbaric oxygen therapy for acute domestic carbon monoxide poisoning: two randomized controlled trials. *Intensive Care Med.* 2011;37(3):486-92
15. Buckley NA, Juurlink DN, Isbister G, Bennett MH, Lavonas EJ. Hyperbaric oxygen for carbon monoxide poisoning. *Cochrane Database Syst Rev.* 2011;(4):CD002041. Review.
16. Baud FJ, Borron SW, Mégarbane B, Trout H, Lapostolle F, Vicaud E, et al. Value of lactic acidosis in the assessment of the severity of acute cyanide poisoning. *Crit Care Med.* 2002;30(9):2044-50.
17. Lawson-Smith P, Jansen EC, Hyldegaard O. Cyanide intoxication as part of smoke inhalation--a review on diagnosis and treatment from the emergency perspective. *Scand J Trauma Resusc Emerg Med.* 2011;19:14.
18. Nascimento TS, Pereira RO, Mello HL, Costa J. Metemoglobinemia: do diagnóstico ao tratamento. *Rev Bras Anesthesiol.* 2008;58(6):651-64.
19. Mohan A, Lee T, Sachdev P. Surviving acute cyanide poisoning: a longitudinal neuropsychological investigation with interval MRI. *BMJ Case Rep.* 2014;2014. pii: bcr2013203025.