

Comparative Study of MTA and Other Materials in Retrofilling of Pulpless Dogs' Teeth

Pedro Felício Estrada BERNABÉ
Roberto HOLLAND
Ricardo MORANDI
Valdir de SOUZA
Mauro Juvenal NERY
José Arlindo OTOBONI FILHO
Eloi DEZAN JUNIOR
João Eduardo GOMES-FILHO

*Discipline of Endodontics, Department of Restorative Dentistry, Faculty of Dentistry of Araçatuba,
São Paulo State University (UNESP), Araçatuba, SP, Brazil*

This *in vivo* study compared the effect of mineral trioxide aggregate (MTA), IRM, Super EBA and ZOE in a puttylike consistency, used as retrofilling materials, in the healing process of periapical tissue of pulpless dogs' teeth submitted to a conventional retrofilling technique. Twenty-four premolars obtained from three dogs were used. At the first intervention, the animals were anesthetized, coronal access was obtained and pulpectomy was done. Root canals were kept open to the oral environment for 180 days to induce the formation of apical lesions. After surgical removal of the lesions with curettes, 2 mm of the apical root was cut out perpendicular to the long axis of the teeth, and root-end cavities were shaped with a low-speed round bur. The bone cavities were irrigated and dried, and the root-end cavities were filled with MTA, IRM, Super EBA and ZOE in a puttylike consistency. The bone cavities were passively filled with blood and flaps were sutured. The coronal access openings were cleaned and double-sealed with ZOE and amalgam. After 180 days, the animals were killed by anesthetic overdose, maxilla and mandible were removed and the pieces were processed for histomorphologic analysis. Data were evaluated blindly on the basis of several histopathologic events and the scores obtained were analyzed statistically using the Kruskal Wallis test. No significant differences were observed among MTA, Super EBA and IRM ($p > 0.05$). However, ZOE had a significantly more negative influence on the apical healing ($p < 0.05$). In conclusion, MTA, Super EBA and IRM had similar histopathologic effects among each other and better performance than ZOE used in a puttylike consistency. Furthermore, only MTA stimulated hard tissue deposition in direct contact with the retrofilling material, even when it was inserted under critical conditions.

Key Words: mineral trioxide aggregate, apical surgery, retrofilling.

INTRODUCTION

The objective of endodontic treatment is to eliminate microorganisms from the root canal system and to fill the intracanal space with proper materials to prevent a new bacterial colonization that could maintain or evoke an apical pathosis.

In modern dentistry, cleaning and shaping of the root canal system can be efficiently performed. Due to improvements on instruments and techniques, it is now possible to obtain a success rate of nearly 90% with conventional root canal therapy (1). However, several

factors inherent to the endodontic procedures, such as perforations, instrument breakage, calcifications and anatomic anomalies can lead to treatment failure. In some cases, conventional endodontic treatment is not sufficient to solve the problem and a surgical endodontic intervention is required (2,3).

The ideal root-end filling material must be non-toxic, non-mutagenic, biocompatible and insoluble (4). Amalgam, gutta-percha, zinc oxide and eugenol (ZOE), IRM, Super EBA, glass ionomer cement, composite and mineral trioxide aggregate (MTA) have been used for such purpose (2-8).

Correspondence: Prof. Dr. Pedro Felício Estrada Bernabé, Departamento de Odontologia Restauradora, Faculdade de Odontologia de Araçatuba, UNESP, Rua José Bonifácio 1193, 1605-050 Araçatuba, SP, Brasil. e-mail: bernabe@foa.unesp.br

MTA was developed at the Loma Linda University with the specific goal of sealing communications between the tooth and the external surface (9). Studies evaluating MTA as a retrofilling material have shown less periapical inflammation, presence of a fibrous capsule and formation of new cementum layer in contact with the material surface in many cases (5). Similar findings were reported by Holland et al. (8) in a study in dogs. When MTA was used for treatment of furcation perforations in dogs' premolars, deposition of new cementum in contact with the material was also observed (10). A dentin bridge was also found covering the pulp tissue remaining after pulp capping with MTA (8,11).

On the other hand, previous *in vivo* studies have utilized MTA only in non-infected or decontaminated root canals (5,6). These conditions benefited the material sealability by eliminating a large amount of microorganisms, which feed the inflammatory response. It is important to evaluate the behavior of the materials in critical situations, i.e., when the canals are not completely decontaminated and the cavities are bur-prepared instead of being obtained by ultrasonic preparation. Under these conditions, material sealability would actually be assessed as an important factor accounting to the healing process.

In the light of the results of several studies that have investigated the behavior of MTA under different circumstances (2-9), the purpose of this *in vivo* study was to compare the periapical tissue healing induced by MTA and other retrofilling materials - IRM, Super EBA and ZOE in a puttylike consistency - inserted in bur-prepared apical cavities in non-decontaminated root canals of dogs' teeth.

MATERIAL AND METHODS

Twenty-four upper and lower premolars from three male adult mongrel dogs (8 teeth *per* animal) aged 2-3 years old were used in this study. An initial sample size of 48 roots was obtained. The animals were preanesthetized with 2 mL of the association of xylazine (Rompum; Bayer do Brasil S/A, São Paulo, SP, Brazil) and ketamine hydrochloride (Ketalar; Park Davis - Aché Laboratórios Farmacêuticos S/A, São Paulo, SP, Brazil), in a 1:1 ratio, administered intramuscularly. Anesthesia was obtained with 3% sodium pentobarbital (1 mL/kg, *iv*) (Hypnol, Cristália Produtos Farmacêuticos Ltda, Itapira, SP, Brazil) and maintained with subsequent

anesthetic injections.

At the first intervention, coronal access and pulpectomy were performed without the use of rubber dam isolation. The root canals were left open to the oral environment for 180 days to induce the formation of apical lesions, which was confirmed radiographically (12). Afterwards, the animals were anesthetized, debris were removed from the pulp chamber with saline irrigation and Hedstrom files were used to remove debris from the root canals without any irrigation prior to the surgery.

Surgery began with use of topic antiseptic solutions (iodine solution and 0.12% chlorhexidine gluconate). Flap design consisted of two releasing incisions connected by a sulcular incision. After flap elevation, ostectomy was done with chisel and complemented with a Zekrya bur (Maillefer Instruments S/A, Ballaigues, Switzerland). After removal of the apical lesion with #85 Lucas surgical curettes (Hufriedy, Chicago, IL, USA) and #35 and #36 curettes (Maillefer Instruments S/A), 2 mm of apical root were cut out with a Zekrya bur (Maillefer Instruments S/A) at high speed, in a way that the cut surface was perpendicular to the long axis of the root. The root-end cavities were shaped with 008 stainless steel round burs (KAVO do Brasil Ind. Com., Joinville, SC, Brazil) at low-speed handpiece (29A; KAVO do Brasil Ind. Com.). Saline was used as irrigant during the procedures.

The root-end cavities were irrigated with saline, aspirated and dried with absorbent paper points. Cavities were filled with either IRM (Dentsply/Caulk, Milford, DE, USA), Super EBA (Harry J. Bosworth Co., Skokie, IL, USA) and MTA (Loma Linda University, Loma Linda, CA, USA), according to the manufacturers' instructions or ZOE (SS White Artigos Dentários Ltda., Rio de Janeiro, RJ, Brazil) in a puttylike consistency (1.0 g of zinc oxide and 0.2 g of eugenol), according to Bernabé (1994). Twelve roots were used for each tested material. After the apical procedures, the bone cavities were filled with blood and the flaps were sutured. Coronal access openings were cleaned with a bur and saline and were double-sealed with ZOE and amalgam (SS White). Root canals were maintained contaminated and were not filled. After surgical procedures, the animals were kept on a standard diet.

After 180 days, the animals were killed by anesthetic overdose. Maxillas and mandibles were removed, fixed in 10% buffered formalin solution and

decalcified in formic acid and sodium citrate solution. The specimens were embedded in paraffin wax, serially sectioned at 6 µm intervals and stained with hematoxylin-eosin (H&E) and the Brown and Brenn staining technique.

The specimens were examined by one of the authors, in a blind analysis, on the basis of 17 histopathologic events. Each event was scored 1 to 4, 1 being the best result and 4 the worst. At least 10 serial sections were examined from each sample to establish an average and data were recorded. It is important to mention that PDL thickness in each section examined was calculated based on the average of six different positions along the resected root surface. In addition, for PDL analysis, the resected root surface was considered as two parts separated by the root canal space. Data were analyzed statistically using the Kruskal Wallis test.

RESULTS

During histological preparation, 8 roots were lost, reducing the sample size to 40 specimens. Therefore, only 10 roots were evaluated for each retrofilling material.

ZOE in a Puttylike Consistency

Only 2 of 10 specimens showed complete repair without inflammatory infiltrate, presence of new cement covering the cut dentin sites and cavities filled with bone and periodontal fibers. A well-organized fibrous capsule was observed with no inflammatory cells in contact with the root-end filling material. In these cases, no debris, which could lead to treatment failure, was detected (Figs. 1 and 2). Two cases had similar characteristics but a mild chronic inflammatory response was observed in the periodontal ligament. Debris was present on the root-end cavity walls. Similarly, 6 cases showed thickened apical PDL space, as well as severe and extensive chronic inflammatory infiltrate with lymphocytes, plasma cells, macrophages and microabscesses. Great amount of debris and dentinal resorption were seen. Brown & Brenn staining technique showed gram-negative microorganisms in 6 cases.

IRM

Only 4 of 10 cases showed complete repair without inflammatory infiltrate, filling of bone cavities

by new bone tissue and cut dentin sites covered with new eosinophilic cementum. PDL rebuilding, with a fibrous capsule between the retrofilling material and bone tissue, was observed. No debris was detected (Fig. 3). Six cases showed an intense and extensive chronic inflammatory infiltrate with macrophages, lymphocytes, plasma cells, leukocytes and microabscesses. Sealing of the root-end cavities was compromised by the presence of debris and dentin resorption. Gram-negative microorganisms were detected on dentinal walls using Brown & Brenn staining technique. Microorganisms were also noted within the dentinal tubules and in the debris adhered to the dentinal walls in contact with the apical tissue. New eosinophilic cementum, covering partially or totally the exposed root-end dentin was present in 8 cases.

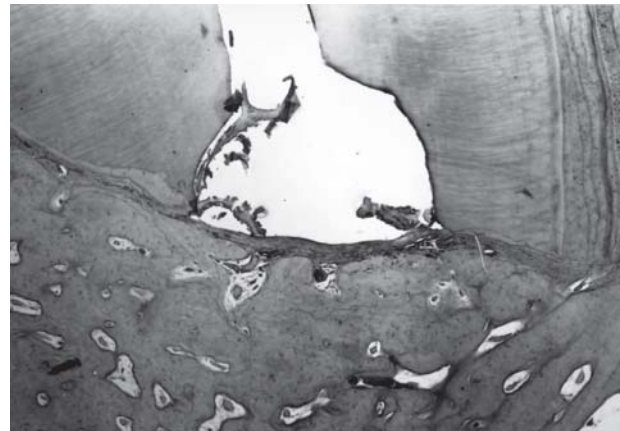


Figure 1. ZOE. Complete bone healing and presence of a thin capsule between bone tissue and retrofilling material. H&E. (original magnification X40).

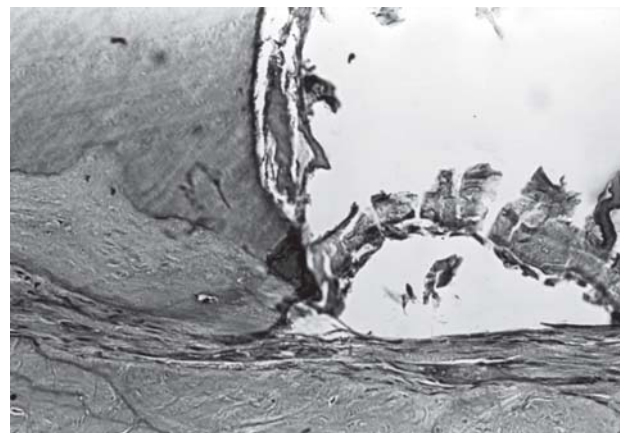


Figure 2. ZOE. Presence of debris and dentinal chips. H&E. (original magnification X200).

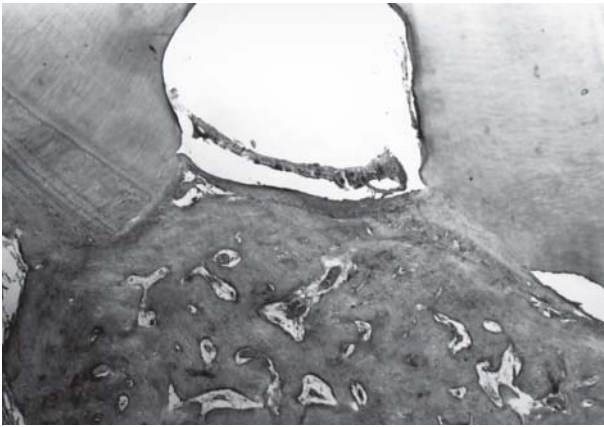


Figure 3. IRM. Complete healing. H&E (original magnification X40).

Super EBA

Complete healing was observed in 6 of 10 roots, with the bone cavities filled with reorganized PDL fibers, no inflammatory cells, new eosinophilic cement covering the exposed dentin and root-end filling material. In these cases, osseous tissue and well-organized fibrous capsules without inflammatory cells were observed, but with dark particles even inside the macrophage cytoplasm. One of these specimens showed a bone-like tissue in contact with root-end filling material and the presence of particles of the material and mild chronic inflammatory infiltrate (Fig. 4). Gram-negative microorganisms were also detected on dentinal walls of 3 specimens using Brown & Brenn staining technique. Four cases had an intense and extensive chronic inflammatory infiltrate with macrophages, lymphocytes,

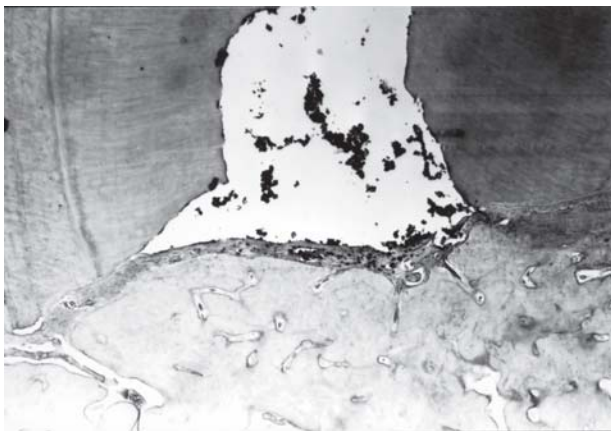


Figure 4. Super EBA. New bone tissue in complete healing close to the retrofilling material. Connective tissue between the structures. H&E (original magnification X40).

plasma cells, leukocytes and microabscesses. New cementum was noted in only one case, but with exposed root surface dentin. Debris was also noted.

MTA

Five of 10 roots showed complete healing without inflammatory infiltrate and filling of bone cavities with new bone tissue. There was new eosinophilic cementum, new PDL and a fibrous capsule separating the retrofilling material and osseous tissue (Figs. 5, 6 and 7). No debris, which could lead to treatment failure, was observed. In these cases, the presence of cementum covering the root-end filling material surface and the incidence of well-organized fibrous capsules without inflammatory cells were also evident, but with dark particles even inside the macrophage cytoplasm. Only 1 case exhibited

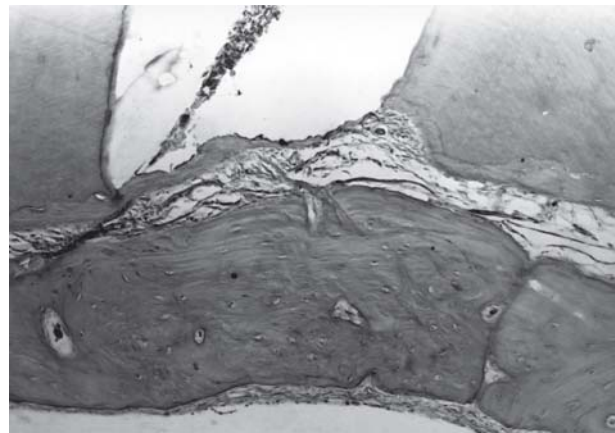


Figure 5. MTA. Complete healing. H&E (original magnification X40).

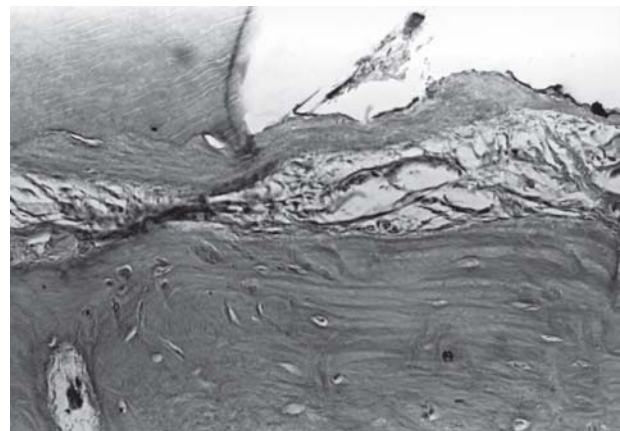


Figure 6. MTA New cement deposited upon both cut dentin surface and retrofilling material. H&E (original magnification X200).

Table 1. Average of the scores attributed to the histomorphologic events, for the four each experimental groups.

Material	MTA	Super EBA	IRM	ZOE
Cementum				
Type	1.0	1.6	2.2	1.9
Extension	1.6	1.9	2.4	2.1
Thickness	2.8	2.8	3.1	2.7
Lateral Resorption	1.5	1.7	2.1	1.9
Lateral Deposition	1.0	1.4	2.1	1.8
Dentinal Resorption				
Active	1.0	1.1	1.2	1.1
Inactive	2.5	2.4	2.3	2.2
Bone Resorption				
	1.7	1.5	1.6	2.0
Acute Inflammation				
Internal	2.4	2.8	2.7	2.2
External	2.3	2.8	2.5	2.0
Chronic Inflammation				
Internal	2.5	2.8	3.0	2.2
External	2.5	2.8	3.0	2.3
Periodontal Ligament				
Thickness	2.5	2.8	3.1	2.5
Organization	2.5	2.8	2.9	2.2
Bacteria	2.2	1.9	2.8	2.8
Debris	2.0	1.7	2.1	3.1
Giant Cells	1.0	1.1	1.0	1.2
Total	1.94a	1.95a	2.18a	2.45b

Different letters indicate statistically significant differences ($p < 0.05$). Materials from best to worst: MTA, Super EBA, IRM, ZOE.

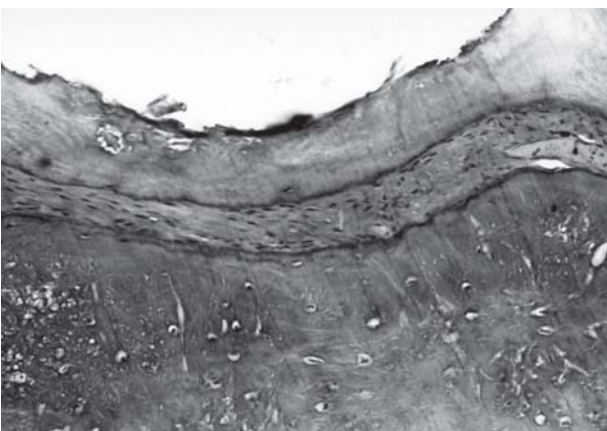


Figure 7. MTA. New cement close to the retrofilling material, PDL without inflammatory response and bone tissue. H&E (original magnification X200).

extensive dentin resorption, and debris was found in another case. Five specimens had an intense and extensive chronic inflammatory infiltrate with macrophages, lymphocytes, plasma cells, leukocytes and microabscesses. In these areas, PDL was completely disorganized and new cementum was noted partially covering the cut dentin sites on root surfaces. Dentin resorption and debris were observed on cavity wall. One specimen presented a cementum bridge almost totally covering the root-end filling material. This was a fibrous capsule intensely infiltrated by inflammatory cells. Using Brown & Brenn staining technique, gram-negative microorganisms were detected in the dentinal tubules and at the interface between root-end material and dentinal wall

The histopathologic events and scores are given on Table 1. It should be pointed out that all events had the same importance for statistical analysis. The materials, displayed from best to worst, should be listed as follows: MTA, Super EBA, IRM and ZOE in a puttylike consistency. MTA, Super EBA and IRM presented statistically similar results ($p > 0.05$) among each other and had significantly better results than ZOE ($p < 0.05$).

DISCUSSION

The experimental model of lesion induction used in this study was based on previously established criteria (12), according to which the teeth were kept exposed to oral environment for 180 days to induce the lesions. Statistical analysis was made based on objective scores obtained from histomorphologic examination to classify the tested materials from best to worst.

Using this methodology, material sealability was assessed under adverse conditions because the cavities were bur-prepared instead of being obtained by ultrasonic root-end preparation, which produced shallow cavities to be filled. Additionally, the root canals were kept contaminated and were not filled, which required better sealability from the root-end filling materials to aid the healing process. This situation was created intentionally to establish a critical model to test the materials. Moreover, an unfilled space was left to simulate a clinical-surgical situation in which the canal could not be properly filled and bacteria would remain. It was possible to keep the canals unfilled because there are no lateral canals in the coronal and middle thirds of dogs' teeth. Therefore, the residual infection inside root canals could

not reach the PDL space to evocate an inflammatory response, unless bacteria and their products had passed through the root-end filling materials and dentinal walls.

Although ultrasonic devices are better indicated for preparation of apical cavities (13), this study aimed to evaluate MTA in comparison to other retrofilling materials after insertion in bur-prepared cavities to create more critical and adverse conditions.

Bernabé (2), in a study in dogs, reported several histopathologic events that can interfere with the healing process after use of burs in root-end preparations. The presence of infected debris resulting from drilling compromised the apical sealing and allowed the maintenance of the apical lesion. Apical dentin resorption is another event that can strongly influence the results, regardless of the retrofilling material used. Apical resorption intensity should be considered because shallow root ends are obtained with bur preparation and therefore the root-end filling materials reached only a short depth. Depending on the resorption extension, the root-end filling material can be partially or completely exposed and damage the apical sealing, allowing the passage of bacteria and their products to the apical tissues. The resorption observed could be related to an auto-immune reaction (14), as well as to the presence of bacteria in the dentinal tubules (15).

In this study, statistically similar results were found for MTA, Super EBA and IRM, and these sealers induced better healing than ZOE in a puttylike consistency. However, it is important to point out that the ZOE group had the greatest number of specimens with debris. These data are consistent with the findings by Cook and Taylor (16), who observed lesser inflammatory response with use of IRM than conventional ZOE. In our study, ZOE was used in a puttylike consistency with the purpose of improving its biocompatibility (3).

Super EBA sealer has aluminum oxide and ortho-ethoxybenzoic acid in its formulation, which produces eugenol reduction and makes the material more tolerable in contact with tissues (17). On the other hand, eugenol in IRM formulation has affinity for polymethacrylate, which limits its release (18). Olsen et al. (19), using IRM and Super EBA, observed that bone repair evolved adequately after the initial periods of evaluation and, in some cases, bone tissue was deposited in contact with the retrofilling material. The authors attributed this healing to the eugenol and ethoxybenzoic acid that had

been diluted by the sore and absorbed by extracellular protein. Formation of a fibrous barrier has been shown to reduce the initial toxicity after use of ZOE sealer enhancing tissue repair (19).

Only MTA presented a cementum-like tissue in close contact with its surface. Deposition of a continuous new cementum layer upon MTA surface has been previously described (10). Dentinal bridge formation after direct pulp capping (11), pulpotomy (8) and perforation treatment (7,10) also support our results. Torabinejad et al. (6) reported that cementum deposition against MTA may be due to several factors, such as sealing ability, biocompatibility or alkaline pH on setting. It is possible that calcium oxide, in MTA formulation, reacts with water or tissue fluids, forming calcium hydroxide and stimulating hard tissue deposition (20). This assumption is supported by the presence of granulations birefringent to polarized light, found with use of MTA, which are similar to the calcite crystals observed with use of calcium hydroxide (20).

Torabinejad et al. (6) and Torabinejad et al. (5) evaluated the response of MTA and amalgam as retrofilling materials in pulpless teeth of monkeys and dogs. However, differently from this study, they instrumented and filled the root canals before retrofilling, which provided non-contaminated canals and no development of apical lesions. Although different methodologies were used and despite the fact that MTA was set under more critical conditions in the present study, our results were similar to theirs (5,6) with respect to cementum deposition on material surface and presence of mild inflammation. These data show that MTA was able to induce apical healing even when placed in infected canals. It may be assumed that neoformed cementum deposition on the entire material surface (biological sealing), as observed with MTA, was an important histopathologic event to be considered because it isolated the content remaining within the intracanal space and root-end filling material from the apical tissues. Same biological sealing was not observed with the other retrofilling materials evaluated.

According to the methodology proposed and based on the results of this study, it may be concluded that MTA, Super EBA and IRM had similar histopathologic results and presented better performance than ZOE in a puttylike consistency. Furthermore, only MTA stimulated deposition of neoformed cementum in direct contact with the retrofilling material, in spite of

being used under adverse conditions, such as in non-instrumented root canals and in bur-prepared cavities.

RESUMO

O presente estudo *in vivo* comparou os efeitos do agregado de trióxido mineral (MTA), IRM, Super EBA e OZE na consistência de massa de vidraceiro, usados como material para obturação retrógrada, no processo de reparo dos tecidos periapicais de dentes despulpados de cães submetidos à técnica de retrobturação convencional. Vinte e quatro pré-molares obtidos de três cães foram usados. Na primeira intervenção, os animais foram anestesiados, e a abertura coronária e a pulpectomia foram realizadas. Os canais radiculares foram mantidos abertos ao meio oral por 180 dias para induzir a formação de lesão periapical. Após a remoção cirúrgica das lesões com curetas, 2 mm apicais da raiz foram seccionados perpendicularmente ao longo eixo do dente e uma cavidade apical foi preparada com broca esférica em baixa-rotação. As cavidades ósseas foram irrigadas e secas, e as cavidades apicais obturadas com MTA, IRM, Super EBA e OZE na consistência de massa de vidraceiro. As cavidades ósseas foram passivamente preenchidas com sangue e os retalhos suturados. As aberturas coronárias foram limpas e seladas duplamente com OZE e amálgama. Após 180 dias, os animais foram sacrificados por super-dosagem de anestésico, a maxila e a mandíbula foram removidas e as peças processadas para análise histomorfológica. Os dados foram avaliados cegamente com base nos vários eventos histomorfológicos e os escores obtidos foram analisados estatisticamente usando o teste Kruskal Wallis. Nenhuma diferença estatisticamente significativa foi observada entre MTA, Super EBA e IRM ($p > 0,005$). Entretanto, o OZE teve influência negativa significativamente maior no reparo apical ($p < 0,005$). Estes resultados indicam que MTA, Super EBA e IRM tiveram efeitos histopatológicos similares entre eles e melhor performance que o OZE utilizado na consistência de massa de vidraceiro. Além disso, somente o MTA estimulou a deposição de tecido duro em contato direto com o material retrobturador, mesmo quando inserido sob condições críticas.

REFERENCES

- Guttman JL, Harrison JW. Surgical Endodontics. 1st ed. Boston: Blackwell Scientific Publications; 1991.
- Bernabé PFE. Healing process after apicotomy and retrofilling. Influence of the material and root canal conditions: dogs' teeth study. [Doctoral Thesis]. São Paulo, Brazil: Faculty of Dentistry of Bauru, University of São Paulo; 1981. 124 p.
- Bernabé PFE. Pulp less dogs' teeth study after apicotomy and retrograde treatment: influence of filling level and retrofilling material [Master's Degree Thesis]. Araçatuba, Brazil: Faculty of Dentistry of Araçatuba, Sao Paulo State University; 1994. 352 p.
- Gartner AH, Dorn SO. Advances in endodontic surgery. Dent Clin North Am 1992;38:357-378.
- Torabinejad M, Hong CU, Lee SJ, Monsef M, Pitt Ford TR. Investigation of mineral trioxide aggregate for root-end filling in dogs. J Endod 1995;21:603-608.
- Torabinejad M, Pitt Ford TR, McKendry DJ, Abedi HR, Miller DA, Kariyawasan SP. Histologic assessment of mineral trioxide aggregate as a root-end filling in monkeys. J Endod 1997;23:225-228.
- Holland R, Souza V, Nery MJ, Otoboni Filho JÁ, Bernabé PFE, Dezan Jr E. Reaction of dogs' teeth to root canal filling with mineral trioxide aggregate or a glass ionomer sealer. J Endod 1999;25:728-730
- Holland R, de Souza V, Murata SS, Nery MJ, Bernabé PF, Otoboni Filho JA, Dezan Junior E. Healing Process of dog dental pulp after pulpotomy and pulp covering with mineral trioxide aggregate or portland cement. Braz Dent J 2001;12:109-113.
- Lee SJ, Monsef M, Torabinejad M. Sealing ability of a mineral trioxide aggregate for repair of lateral root perforations. J Endod 1993;19:541-544.
- Pitt Ford TR, Torabinejad M, McKendry DJ, Hong CU, Kariyawasan SP. Use of mineral trioxide aggregate for repair of furcal perforations. Oral Surg Oral Med Oral Pathol 1995;79:756-762.
- Faraco Jr IM, Holland R. Response of the pulp of dogs to capping with mineral trioxide aggregate or a calcium hydroxide cement. Dent Traumatol 2001;17:163-166.
- Holland R, Souza V, Nery MJ, Mello W, Bernabé PFE, Otoboni Filho JA. A histological study of the effect of calcium hydroxide in the treatment of pulpless teeth of dogs. J Br Endod Soc 1979;12:15-23
- Gutmann JL, Saunders WP, Nguyen L, Guo IY, Saunders EM. Int Endod J 1994;27:318-324.
- King G, Courts F. Changes in the titer of root antibodies accompanying traumatic root resorption. In: Biological Mechanism of Tooth Eruption and Root Resorption. Davidovitch Z. (Editor). 1st ed. Ohio, USA: The Ohio State University; 1988. p. 365-370.
- Nair PNR, Sjögren U, Krey G, Kahnberg K-E, Sundqvist G. Intraradicular bacteria and fungi in root-filled, asymptomatic human teeth with therapy-resistant periapical lesions: a long term light and electron microscopic follow-up study. J Endod 1990;16:580-588.
- Cook D, Taylor P. Tissue reactions to improved zinc-oxide eugenol cements. J Dent Child 1973;40:199-207.
- Fitzpatrick EL, Steiman HR. Scanning electron microscopic evaluation of finishing techniques on IRM and EBA retrofillings. J Endod 1997;23:423-427.
- Chong BS, Owadally ID, Pitt Ford TR, Wilson RF. Antibacterial activity of potential retrograde root filling materials. Endod Dent Traumatol 1994;10:66-70.
- Olsen FK, Austin P, Walia H. Osseous Reaction to implanted ZOE retrograde filling materials in the tibia of rats. J Endod 1994;20:389-394.
- Holland R, Souza V, Nery MJ, Otoboni Filho JA, Bernabé PFE, Dezan Jr E. Reaction of rat connective tissue to implanted dentin tubes filled with mineral trioxide aggregate or calcium hydroxide. J Endod 1999;25:161-166.

Accepted January 24, 2005