

Importance of the Diagnosis in the Pulpotomy of Immature Permanent Teeth

Ronaldo Araújo SOUZA¹
Suely COLOMBO Nelli Gomes²
João da Costa Pinto DANTAS²
Yara Terezinha SILVA-SOUSA¹
Jesus Djalma PÉCORÁ³

¹*School of Dentistry, University of Ribeirão Preto, Ribeirão Preto, SP, Brazil*

²*School of Dentistry, Bahia State Foundation for Science Development, Salvador, BA, Brazil*

³*School of Dentistry of Ribeirão Preto, University of São Paulo, Ribeirão Preto, SP, Brazil*

Pulpotomy is a conservative therapy performed to remove the inflamed coronal portion of the pulp and preserve the vitality of the remaining radicular pulp. This article reports two cases of immature permanent mandibular molars with clinical signs of pulp vitality and radiographic images of periapical bone rarefaction, which were treated with calcium hydroxide pulpotomy. In Case 1, pulpotomy was performed in a single session, while in Case 2 two sessions were required to complete the treatment. Clinical and radiographic follow up within 13 and 9 months, respectively, showed hard tissue barrier and new bone formation as well as progression of root development. These outcomes are confirmatory that an accurate clinical/radiographic assessment of pulp vitality is of paramount importance for the correct diagnosis and indication of pulpotomy in cases of young permanent teeth with incomplete root formation.

Key Words: pulpotomy, diagnosis, calcium hydroxide, periapical lesion.

INTRODUCTION

The dental pulp is an innervated and vascularized tissue that is able to react to physical, chemical and biological stimuli and promote an adequate healing, with formation of a hard tissue barrier (1). If the stimulus or damage is severe, the pulp healing capacity may be exceeded and it may progress to an irreversibly inflamed condition and to necrosis. However, if pulp exposure is discrete in primary or young permanent teeth, some procedures may be performed in an attempt to reestablish pulpal health and maintain its vitality (1-3).

Pulp exposure is defined in the MeSH (Index Medicus: Medical Subject Headings) as "the result of pathological changes in the hard tissue of a tooth caused by carious lesions, mechanical factors or trauma, which render the pulp susceptible to bacterial invasion from the external environment". The treatment of pulp exposure

should aim at its complete repair and formation of a mineralized barrier that covers the exposed area completely (4).

Pulpotomy comprises coronal pulp amputation and placement of a protective agent over the remaining viable root pulp in order to preserve its vitality and function (2,3). It is indicated for primary or young permanent teeth with inflamed and/or infected coronal pulp. However, the presence of periapical rarefaction has been presented as a condition that contraindicates pulpotomy.

By presenting two cases of immature permanent mandibular molars with radiographic image of periapical lesion submitted to calcium hydroxide pulpotomy, the purpose of this article is to discuss, based on the treatment outcomes and on the literature, whether periapical bone rarefaction is actually a contraindication for this type of therapy.

CASE REPORT

Case 1

A 7-year-old female patient was referred for treatment of the mandibular left first molar that presented a deep caries and radiographic image suggestive of periapical lesion (Fig. 1A). Pulp vitality test was not performed because of the clinical aspect of the carious lesion associated with the well-defined image of periapical bone rarefaction.

After anesthesia, rubber dam placement and carious tissue excavation, access to pulp chamber was gained. A vital pulp tissue was observed with normal consistence and bleeding characteristics. The coronal pulp was excised with sharp curettes under copious irrigation with calcium hydroxide solution alternated with aspiration. After hemostasis, the area of the exposed root pulp tissue was dried pressureless with sterile cotton pellets and the pulp chamber floor was capped with a calcium hydroxide/saline paste, sealing root canal entrances. A sterile cotton mesh was placed over the paste and the pulp chamber was sealed with a quick-setting zinc oxide and eugenol-based cement (Fig. 1B).

The periapical radiographs taken 13 months after pulpotomy revealed complete regression of the periapical lesion with periradicular bone tissue formation, normal root development and recovery of the apical periodontal ligament space and lamina dura (Figs. 1B and 1C).

Case 2

A 6-year-old male patient was referred by the periodontist with a dressing on the lower right side of the

face due to the drainage of an extraoral fistula. The preoperative radiograph showed a furcation lesion communicating with the a periapical lesion associated with the distal root of that tooth (Fig 2A). After anesthesia, rubber dam placement and carious tissue excavation, access to pulp chamber was gained. A vital pulp tissue was observed with normal consistence and bleeding characteristics.

As the patient was uncooperative, pulpotomy was scheduled as two-session procedure. In the first session, the coronal pulp was partially excised with sharp curettes under copious irrigation with calcium hydroxide solution alternated with aspiration. After hemostasis, the remaining coronal pulp tissue was dried pressureless with sterile cotton pellets and protected with a calcium hydroxide/saline paste. The pulp chamber was provisionally sealed with the quick-setting zinc oxide and eugenol-based cement (Fig. 2B).

At the second session, the patient was anesthetized, a rubber dam was placed, the provisional restoration was removed and pulpotomy was completed in the same way as performed in the first session. The distal root canal presented darkened bleeding and the pulp tissue was less resistant to cutting with the curettes. Thus, pulp amputation proceeded 2 mm beyond the canal entrance, at which point normal live red bleeding and resistance to cutting were observed.

After hemostasis, the area of the exposed root pulp tissue was dried pressureless with sterile cotton pellets and the pulp chamber floor was covered with a calcium hydroxide/saline paste, sealing root canal entrances. A sterile cotton mesh was placed over the paste and the pulp chamber was sealed with the quick setting

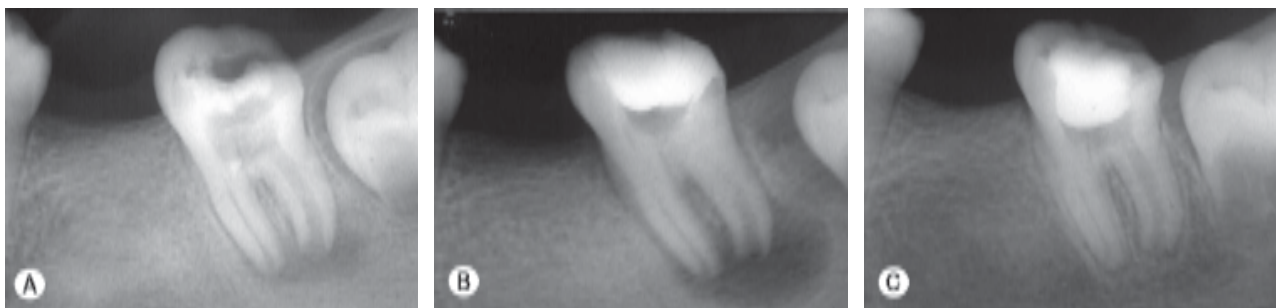


Figure 1. Radiographic follow-up of a pulpotomized immature permanent mandibular left first molar with vital pulp. (A) Preoperative periapical radiograph showing periapical bone rarefaction. (B) Radiographic aspect after calcium hydroxide pulpotomy. (C) Thirteen-month control radiograph, showing resolution of the periapical lesion, normal root development, recovery of the apical periodontal ligament space and lamina dura on both roots.

zinc oxide and eugenol-based cement (Fig. 2C).

The periapical radiographs taken 9 months after pulpotomy revealed complete regression of the periapical and furcation lesions, formation of a hard tissue barrier and normal root development (Fig. 2D).

DISCUSSION

Caries progression and pulp exposure permit microbial invasion into the pulp chamber and vascular and tissue alterations become strongly evident. The severity of the inflammatory response increases progressively, leading to pulp necrosis and formation of micro-abscesses. Pulp alterations are, however, local events (5). As the inflammatory reaction becomes stronger, a greater amount of chemical mediators and enzymes is released, which causes the inflammatory

response to persist and extend to a more apical portion of the pulp tissue. This process is repeated successively until the entire pulp tissue is affected (5).

In some cases, especially in immature teeth, before pulp necrosis is completed, chemical mediators of bone resorption, enzymes and products from protein decomposition may cross the remaining healthy pulp tissue and cause periradicular alterations (6). Thus, in spite of their vitality, these teeth develop periapical lesions, as shown in both cases reported in this article.

Therefore, a correct diagnosis is of paramount importance for institution of the most indicated treatment modality. Clinical examination, comprising caries excavation and observation of sensitivity on tissue removal, palpation of vestibules and pulp vitality tests should precede the radiographic examination in the diagnosis of pulp alterations.

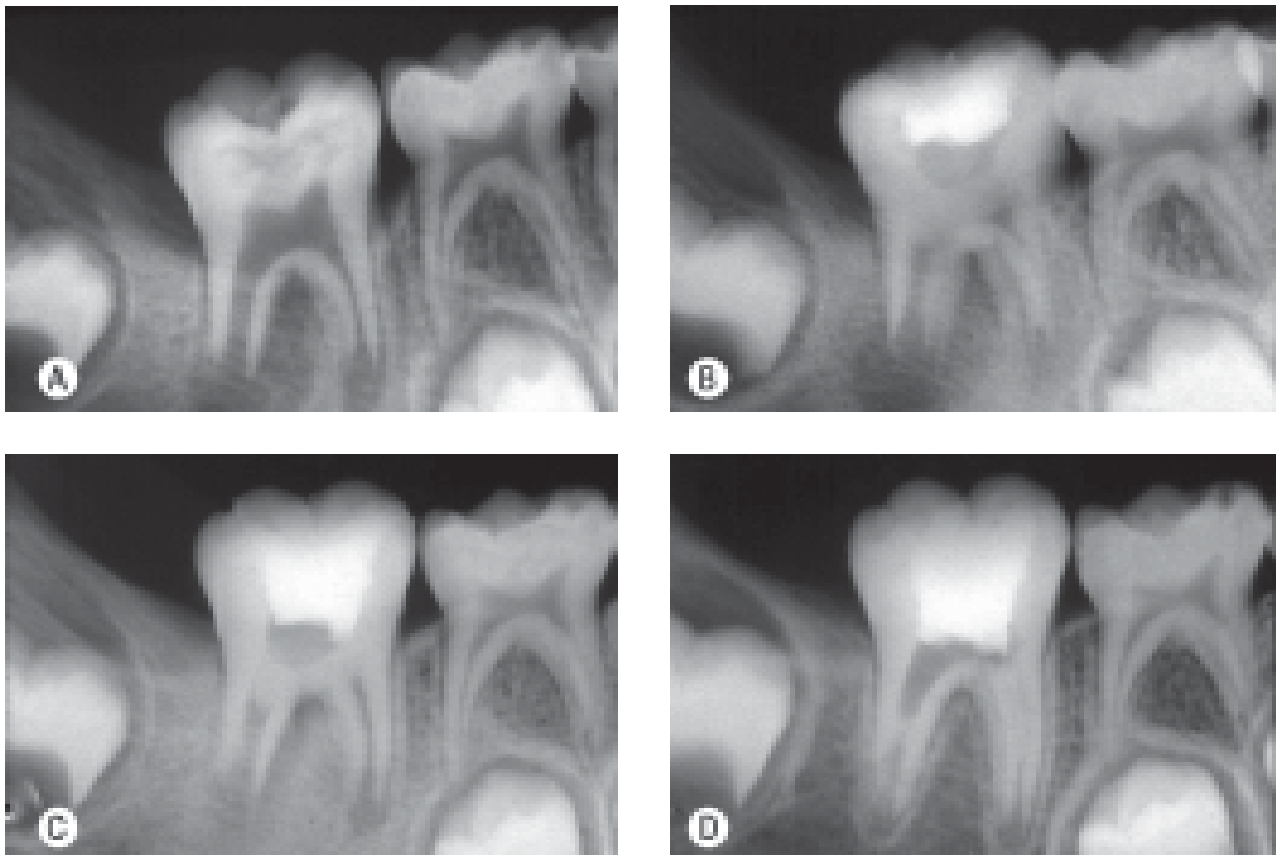


Figure 2. Radiographic follow-up of a pulpotomized immature permanent mandibular right first molar with vital pulp. (A) Preoperative periapical radiograph showing furcation lesion communicating with a periapical lesion on the distal root. (B and C) Radiographic aspect after calcium hydroxide pulpotomy (note that the deeper level of pulp amputation in the distal root). (D) Nine-month control radiograph, showing resolution of the furcation and periapical lesion and normal root development.

Several materials have been used as pulp-capping agents in pulpotomized teeth, among which formocresol, calcium hydroxide, ferrous sulfate and more recently mineral trioxide aggregate (1,3,4,7,8). Some of these materials, like calcium hydroxide, are able to induce the formation of a hard-tissue barrier (1,3,8). In addition to this property, calcium hydroxide is also capable of stimulating pulp tissue repair and presents the best pulp capping outcomes (1,8-12).

When calcium hydroxide is placed in direct contact with the pulp tissue, there is an immediate and short-term tissue reaction supposedly caused by its high alkalinity. This alkaline effect is due to the release of hydroxyl ions, which, in contact with the vital tissue, produce morphological changes that are histologically characterized by the presence of self-limiting superficial necrosis in their early stage (13). Moreover, it has been reported (14) that the alkaline environment avoids bacterial proliferation, which is of paramount importance because tissue repair and mineralized tissue deposition only occur in the absence of an infectious process.

In vivo studies (1,8) have demonstrated that calcium hydroxide is an excellent choice for cases of pulpotomy, present high rates of hard tissue barrier formation and sealing of pulp exposure, maintaining the integrity and vitality of the remaining root pulp. Accordingly, in both cases reported in this article, hard-tissue barrier and periapical new bone formation was observed in addition to normal root development.

In view of this, it may be concluded that the diagnosis of pulp and/or periradicular alterations in immature permanent teeth should not rely exclusively on radiographic findings. A detailed clinical examination, comprising pulp vitality, percussion and palpation tests, should be complemented by the evaluation of characteristics such as pulp firmness (resistance to cutting with cures), color and type of bleeding. With proper case selection and indication, calcium hydroxide pulpotomy may be a feasible and valuable treatment modality for immature permanent teeth, even those associated with a radiographic image suggestive of periapical lesion.

RESUMO

A pulpotomia é uma terapia conservadora indicada para dentes vitais com alterações inflamatórias da polpa dental coronária. Esse artigo relata dois casos de molares inferiores com rizogênese incompleta e imagem radiográfica de rarefação periapical que, clinicamente, apresentavam vitalidade pulpar e foram tratados

pela técnica da pulpotomia com hidróxido de cálcio. No caso 1 a pulpotomia foi realizada em sessão única e no caso 2 em duas sessões. A preservação clínica e radiográfica com 13 e 9 meses, respectivamente, evidenciou formação de barreira mineralizada, neoformação óssea e desenvolvimento radicular. Conclui-se que a avaliação clínica da vitalidade pulpar, complementada pela análise radiográfica, é fundamental para o correto diagnóstico e indicação de pulpotomia em casos de dentes permanentes jovens com rizogênese incompleta.

REFERENCES

1. Albuquerque DS, Gominho LF, Santos RA. Histologic evaluation of pulpotomy performed with ethyl-cyanoacrylate and calcium hydroxide. *Braz Oral Res* 2006;20:226-230.
2. Markovic D, Zivojinovic V, Vucetic M. Evaluation of three pulpotomy medicaments in primary teeth. *Eur J Paediatr Dent* 2005;6:133-138.
3. Huth KC, Paschos E, Hajek-Al-Khatir N, Hollweck R, Crispin A, Hickel R, Folwaczny M. Effectiveness of 4 pulpotomy techniques-randomized controlled trial. *J Dent Res* 2005;84:1144-1148.
4. Olsson H, Petersson K, Rohlin M. Formation of a hard tissue barrier after pulp capping in humans. A systematic review. *Int Endod J* 2006;39:429-442.
5. Ricucci D. Apical limit of root canal instrumentation and obturation, part 1. Literature review. *Int Endod J* 1998;31:384-393.
6. Langeland K. Management of the inflamed pulp associated with deep carious lesion. *J Endodon* 1981;7:169-181.
7. Cengiz SB, Batirbaygil Y, Onur MA, Atilla P, Asan E, Altay N, Cehreli ZC. Histological comparison of alendronate, calcium hydroxide and formocresol in amputated rat molar. *Dental Traumatol* 2005;21:281-288.
8. Tunç ES, Saroglu I, Sari S, Günhan Ö. The effect of sodium hypochlorite application on the success of calcium hydroxide pulpotomy in primary teeth. *Oral Surg Oral Med Oral Pathol Oral Radiol Endod* 2006;102:22-26.
9. Trope M, McDougal R, Levin L, May KN, Swift EJ. Capping the inflamed pulp under different clinical conditions. *J Esthet Restor Dent* 2002;14:349-357.
10. Hörsted-Bindslev P, Vilkinis V, Sidlauskas A. Direct capping of human pulps with a dentin bonding system or with calcium hydroxide. *Oral Surg Oral Med Oral Pathol Oral Radiol Endod* 2003;96:591-600.
11. Conrado CA. Remineralization of carious dentin. I: *In vitro* microradiographic study in human teeth capped by calcium hydroxide. *Braz Dent J* 2004;15:59-62.
12. Briso AL, Rahal V, Mestreneur SR, Dezan Junior E. Biological response of pulps submitted to different capping materials. *Braz Oral Res* 2006;20:219-225.
13. Schröder U. Effects of calcium hydroxide-containing pulp-capping agents on pulp cell migration, proliferation, and differentiation. *J Dent Res* 1985;64:541-548.
14. Cvek M. Treatment of non-vital permanent incisors with calcium hydroxide. *Odont Rev* 1972;23:27-44.
15. Caliskan MK. Pulpotomy of carious vital teeth with periapical involvement. *Int Endod J* 1995;28:172-176.

Accepted October 18, 2006