

# Bilateral Mandibular Canines with Two Roots and Two Separate Canals - Case Report

Fausto Rodrigo VICTORINO  
Ricardo Affonso BERNARDES  
Jarcio Victorio BALDI  
Ivaldo Gomes de MORAES  
Norberti BERNARDINELLI  
Roberto Brandão GARCIA  
Clovis Monteiro BRAMANTE

*Department of Restorative Dentistry, Endodontics and Dental Materials,  
Bauru Dental School, University of São Paulo, Bauru, SP, Brazil*

The mandibular canine is usually considered a single-rooted tooth with a single root canal. However, two canals and more rarely two roots may also occur. This paper reports the case of a patient with bilateral mandibular canines with two roots and two root canals. The initial periapical radiographs of the mandibular right and left canines for endodontic treatment revealed the presence of two roots in each tooth. After coronal opening, the cervical third was prepared with a SX file of the ProTaper® system and root canal length was confirmed using Root ZX electronic apex locator. Root canal preparation was completed with the series of ProTaper® instruments and the root canal was filled with gutta-percha and an epoxy resin-based endodontic sealer according to Tagger's hybrid technique. The final radiographs showed two well-obtured canals ending at the electronically located apexes. The 6-month posttreatment follow-up showed apparent clinical and radiographic success. Clinicians should always consider the presence of anatomical variations in the teeth during endodontic treatments. Despite the low prevalence, variations may occur in the number of roots and root canals of mandibular canines, as demonstrated in this case report.

Key Words: mandibular canine, internal anatomy, root canal.

## INTRODUCTION

Knowledge of root canal anatomy is mandatory for the success of endodontic treatment. In most cases, the mandibular canines present only one root (1-5). The occurrence of two roots and even more two root canals is rare, ranging from 1% (4) to 5% (5). Despite the low prevalence, clinicians should consider the possible variations in the number of roots and root canals of mandibular canines. This paper reports the case of a patient with bilateral mandibular canines with two roots and two root canals.

## CASE REPORT

A healthy 40-year-old Caucasian female was

referred to the Clinic of Endodontics of Bauru Dental School, University of São Paulo for endodontic treatment of the mandibular canines and a mandibular lateral incisor for prosthetic rehabilitation. Initial periapical radiographic examination revealed the presence of two roots on both mandibular canines (Fig. 1).

Endodontic treatment was performed in a single session because the teeth presented pulp vitality on clinical examination. After local anesthesia bilaterally, a rubber dam was placed and endodontic access was performed with a #1014 round diamond bur (KG Sorensen, São Paulo, SP, Brazil) and an Endo Z tapered safe-end bur (Dentsply/Maillefer, Ballaigues, Switzerland). Location and negotiation of root canals were done with a size 10 K-file (Maillefer, Ballaigues, Switzerland). The cervical and middle thirds were prepared with a

SX file of the ProTaper® system (Dentsply/Maillefer). Root canal length was determined radiographically and confirmed with an electronic apex locator (Root ZX; J Morita Co, Kyoto, Japan). Chemomechanical preparation was performed with hand Flexofile files (Maillefer) and irrigation with 1% sodium hypochlorite at each change of file. The instrumented root canals were filled with gutta-percha cones and an epoxy resin-based root canal sealer (Sealer 26; Dentsply/Maillefer) according to Tagger's hybrid technique (Figs. 2a and 2b). The final radiographs showed two well-obtured canals ending at the electronically located apices. The 6-month posttreatment follow-up showed apparent clinical and radiographic success.

## DISCUSSION

Diagnosis and identification of the number of roots and root canals are key factors for endodontic treatment. The initial radiograph is extremely important because it allows for the identification or suspicion of root and root canal anatomical variations. Bifurcations in the cervical and middle thirds may be observed ra-

diographically when the x-ray incidence angle does not cause superimposition of images. In mandibular canines, bifurcation at these sites has been shown to occur in 43.1% of the situations (6). In the present case, identification of the second root was evident, especially due to absence of some teeth. However, it does not always occur. Identification of the second root is even more difficult in the presence of tooth crowding. Therefore, the radiographic image should be carefully analyzed in order to interpret and identify details that may suggest the presence of bifurcations or trifurcations, such as sudden root canal discontinuity (7).

Endodontists should always search for two canals in mandibular canines during endodontic treatment, even in single-rooted teeth. Green (2) observed two canals in a single root in 13 out of 100 mandibular canines examined. This is consistent with the findings of Hess (8), who observed two canals in 15% of the cases. Vertucci (9) reported the presence of two canals in 18% of the mandibular canines. Mandibular canines with two separated canals also demonstrated in a recent case report (10).

However, the presence of two roots in mandibular canines is rarely observed (11,12). Quellet (5) described the occurrence of two roots and two canals in mandibular canines in only 5% of all analyzed teeth. Laurichesse et al. (4) described the second root of mandibular canines in only 1% of cases. A previous study that investigated the internal anatomy, direction and number of roots and

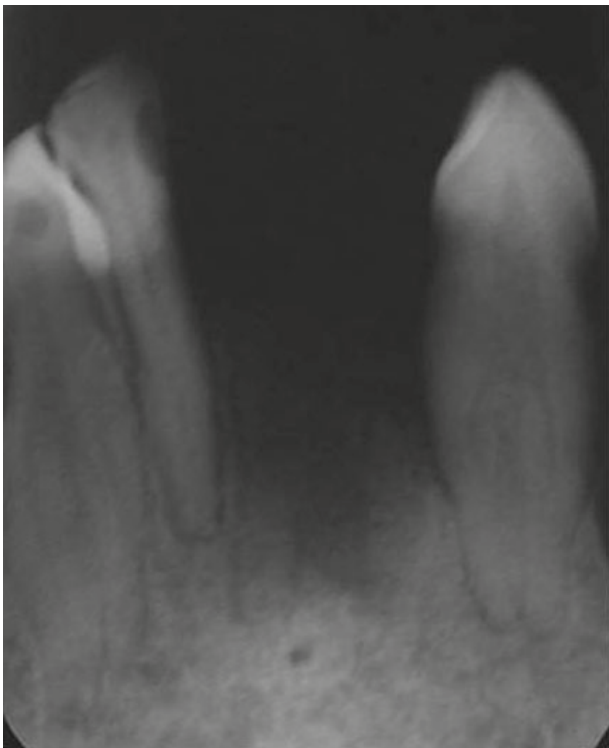

Figure 1. Initial radiograph.

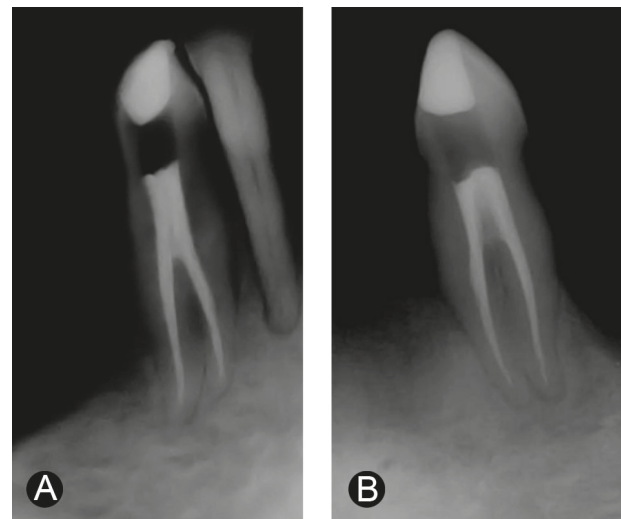


Figure 2. Final radiographs. A: Mandibular right canine; B: Mandibular left canine.

size of 830 extracted human mandibular canines found only 1.7% of the teeth with two roots and separate two canals (13). D'Arcangelo et al. (14) reported two cases of endodontic treatment of mandibular canines with two roots. A case report of two roots in mandibular canine was also presented by Heling et al. (15), yet the tooth exhibited three root canals. To the best of our knowledge, the occurrence of bilateral mandibular canines with two roots and two separate canals, as described in the present case, has not yet been published.

Even though the most common anatomy of mandibular canines comprises a single root and a single root canal, clinicians should consider the possible variations and always search for the second root canal in teeth with either one or two roots.

## RESUMO

O canino inferior é tido como um dente unirradicado e com apenas um canal. Todavia, pode ocorrer o aparecimento de dois canais e, mais raramente, duas raízes. Este artigo apresenta o caso clínico de uma paciente com ambos os caninos inferiores apresentando duas raízes e dois canais radiculares. A radiografia inicial periapical dos caninos mandibulares inferiores direito e esquerdo para tratamento endodôntico revelou a presença de duas raízes em cada um deles. Uma vez realizada a abertura coronária, o preparo do terço cervical foi feito com a lima SX do sistema ProTaper® e a odontometria foi determinada e confirmada eletronicamente com o localizador apical eletrônico Root ZX. O preparo foi finalizado com a série de instrumentos do sistema ProTaper® e a obturação foi realizada com cones de guta-percha e cimento obturador resinoso sob a técnica Híbrida de Tagger. As radiografias finais mostraram dois canais bem obturados terminando nos limites apicais estabelecidos pelos localizadores apicais eletrônicos. O controle de 6 meses mostrou sucesso clínico e radiográfico do tratamento endodôntico. Os clínicos devem sempre considerar a presença de variações anatômicas em todo tratamento endodôntico. Apesar da baixa prevalência, pode haver variações no número de raízes e canais de caninos inferiores, como demonstrado neste caso clínico.

## REFERENCES

1. Pineda F, Kuttler Y. Mesiodistal and buccolingual. Roentgenographic investigation of 7275 root canals. *Oral Surg, Oral Med and Oral Pathol* 1972;33:101-110.
2. Green D. Double canal in single roots. *Oral Surg, Oral Med and Oral Pathol* 1973;35:689-696.
3. Vertucci FJ. Root canal anatomy of the human permanent teeth. *Oral Surg, Oral Med and Oral Pathol* 1984;58:589-599.
4. Laurichesse JM, Maestroni J, Breillat J. *Endodontie Clinique*. 1st ed. Paris, France: CdP;1986:64-66.
5. Ouellet R. Mandibular permanent cuspids with two roots. *J Can Dent Assoc* 1995;61:159-61.
6. Sharma R, Pécora JD, Lumley PJ, Walmsley AD. The external and internal anatomy of human mandibular canine teeth with two roots. *Endod Dent Traumatol* 1998;14:88-92.
7. Ingle JI, Walton RE, Malamed SF, Coil JM, Khademi JA, Kahn FH et al. Preparation for endodontic treatment. In: *Endodontics*. Ingle JI, Bakland LK (Editors). 5th ed. Hamilton: BC Decker Inc., 2002:357-404.
8. Hess W. The anatomy of the root canals of teeth of the permanent dentition. New York: Williams Wood Co.; 1925.
9. Vertucci FJ. Root canal anatomy of the mandibular anterior teeth. *J Am Dent Assoc* 1974;89:369-371.
10. Ghoddsi J, Zarei M, Vatanpour M. Mandibular canine with two separated canals. *N Y State Dent J* 2007;73:52-53.
11. Green D. Morphology of the pulp cavity of the permanent teeth. *Oral Surg* 1955;8:743-759.
12. Kutler Y. Anatomia topografica de la cavidad pulpar. In: *Endodontia Prática*. Kutler Y. Mexico: Alpha; 1961, p. 29.
13. Pécora JD, Sousa Neto MD, Saquy PC. Internal anatomy, direction and number of roots and size of human mandibular canines. *Braz Dent J* 1993;4:53-57.
14. D'Arcangelo C, Varvara G, De Fazio P. Root canal treatment in mandibular canines with two roots: a report of two cases. *Int End J* 2001;34:331-334.
15. Heling I, Gottlieb-Dadon I, Chandler NP. Mandibular canine with two roots and three root canals. *Endod Dent Traumatol* 1995;11:301-302.

*Accepted February 4, 2009*