

# Repair of Critical-Size Defects with Autogenous Periosteum-Derived Cells Combined with Bovine Anorganic Apatite/Collagen: An Experimental Study in Rat Calvaria

Anderson de Oliveira PAULO<sup>1</sup>  
Igor Iuco CASTRO-SILVA<sup>2</sup>  
Davi Ferreira de OLIVEIRA<sup>3</sup>  
Manoel Eduardo de Lima MACHADO<sup>4</sup>  
Idomeo BONETTI-FILHO<sup>5</sup>  
José Mauro GRANJEIRO<sup>2,6</sup>

<sup>1</sup>Graduate Program in Dentistry, Araraquara Dental School, UNESP - Univ. Estadual Paulista, Araraquara, SP, Brazil

<sup>2</sup>Clinical Research Unit, University Hospital Antônio Pedro, UFF - Fluminense Federal University, Niterói, RJ, Brazil

<sup>3</sup>Nuclear Instrumentation Laboratory - PEN/COPPE, Federal University of Rio de Janeiro, Rio de Janeiro, RJ, Brazil

<sup>4</sup>Department of Dentistry, Dental School, USP - University of São Paulo, São Paulo, SP, Brazil

<sup>5</sup>Department of Restorative Dentistry, Araraquara Dental School, UNESP - Univ. Estadual Paulista, Araraquara, SP, Brazil

<sup>6</sup>Directory of Programs, INMETRO - National Institute of Metrology, Standardization and Industrial Quality, Duque de Caxias, RJ, Brazil

The aim of this study was to evaluate the bone repair using autogenous periosteum-derived cells (PDC) and bovine anorganic apatite and collagen (HA-COL). PDC from Wistar rats (n=10) were seeded on HA-COL discs and subjected to osteoinduction during 6 days. Critical-size defects in rat calvarias were treated with blood clot (G1), autogenous bone (G2), HA-COL (G3) and HA-COL combined with PDC (G4) (n=40), and then analyzed 1 and 3 months after surgeries. Radiographic analysis exhibited no significant temporal change. G1 and G2 had discrete new marginal bone, but the radiopacity of graft materials in G2, G3 and G4 impaired the detection of osteogenesis. At 3 months, histopathological analysis showed the presence of ossification islets in G1, which was more evident in G2, homogeneous new bone around HA-COL in G3 and heterogeneous new bone around HA-COL in G4 in addition to moderate presence of foreign body cells in G3 and G4. Histomorphometric analysis showed no change in the volume density of xenograft ( $p>0.05$ ) and bone volume density in G2 was twice greater than in G1 and G4 after 3 months ( $p<0.05$ ), but similar to G3. The PDC did not increase bone formation *in vivo*, although the biomaterial alone showed biocompatibility and osteoconduction capacity.

Key Words: critical size defects, periosteum-derived cells, xenograft, hydroxyapatite, collagen.

## INTRODUCTION

Tissue bioengineering appears as a tool capable of using cells, growth factors and scaffolds to create autogenous tissues in laboratory and apply them as therapeutic agents (1).

Periosteum-derived cells (PDC) have osteogenic potential (2-5). They are an alternative cell source in comparison with bone marrow in the tissue engineering field since they require less invasive and safer techniques

to obtain the osteogenic cells. Also, PDC show greater proliferation, which decreases the time of cell culture, contamination risks and experiment costs. It could be a favorable alternative for dentists as a regenerative therapy for alveolar bone to treat periodontitis and dental implant dehiscences, due to the easy handling, expansion and re-implantation of cells (2).

Cell culture is done upon scaffolds to simulate the 3D structure of bone tissue. Demineralized and acellular bovine xenograft matrices are predominantly composed

Correspondence: Prof. Dr. José Mauro Granjeiro, Instituto Nacional de Metrologia, Normalização e Qualidade Industrial (INMETRO), Avenida Nossa Senhora das Graças, 50, prédio 6, 1o Andar, DIPRO / Programa de Bioengenharia, Xerém 25250-020, Duque de Caxias, RJ, Brasil. Tel: +55-21-2145-3320. Fax: +55-21-2679-9837. e-mail: jmgranjeiro@inmetro.gov.br

by collagen (COL), biocompatible (6), biodegradable and allow adhesion, growing and cellular differentiation (7). On the other hand, anorganic xenograft free of cells and organic matter is mainly constituted of a natural hydroxyapatite (HA), which can be biocompatible, osteoconductive and osteoinductive (8). Combination of both has shown spreading of human osteoblasts after eleven days *in vitro* (9) and new bone formation in femur (10) and rat skull (11) after 2-3 months. In a previous study, PDC-COL showed hundred times more bone in central area of rat calvaria critical-size defects (rcCSD) in comparison with the control group (5). PDC-HA implanted in subcutaneous tissue induced heterotopic ossification (4).

Combination of HA and COL could enhance the ability to carry progenitor cells to bone defects, since the agglutinating capacity of COL will be combined with the osteoconduction property of HA (6). Thus, the aim of this study was evaluate the bone repair in rcCSD using autogenous PDC and a bovine xenograft.

## MATERIAL AND METHODS

### Cellular Isolation and Expansion

Male adult Wistar rats (*Rattus norvegicus albinus*, n=10) under systemic anesthesia with hydrochloride ketamine (60 mg/kg, Francotar; Virbac do Brasil Ltda., São Paulo, SP, Brazil) and hydrochloride xylazine (12 mg/kg, Rompum, Bayer S.A., São Paulo, SP, Brazil) had the frontal-parietal region incised in half-moon to create partial flap to harvest the intact periosteum. Each biopsied tissue sample measuring 1 cm<sup>2</sup> was digested in 0.25% collagenase (Sigma-Aldrich Corp., St. Louis,

MO, USA) for 2 h and cell suspension incubated with DMEM:HAMF12 and 10% bovine fetal serum (Cultilab, São Paulo, SP, Brazil) at 37°C, 5% CO<sub>2</sub> and 95% wet atmosphere. The PDC exhibited adherence to tissue culture acrylic plate after 4 h, typical fibroblast-like morphology within 3 days and constituted a cellular monolayer, which had medium replacement every 2 days. Cells were continuously cultivated until passage 2 for the bioengineering studies. Von Kossa staining and alkaline phosphatase (ALP) assay confirmed the osteogenic potential of PDC (data not shown).

### Cellular Seeding in HA-COL Scaffold

Disks (8 x 1.5 mm) of natural bovine xenograft (75% HA, 25% COL) were incubated in 24-well plates in the same conditions for 24 h, considering the crucial importance of protein adsorption in the initial cellular adhesion step, previously to seeding of 1.0x10<sup>5</sup> autogenous PDC in passage 2 onto xenograft. The medium was supplemented with 20 nM dexamethasone, 50 µg/mL ascorbic acid and 10 mM β-glycerophosphate (Sigma-Aldrich Corp.), replaced every 2 days, and the set was maintained in cell culture for 6 days (2) until surgery. Additional samples (n=3) were processed for ultrastructural morphological evaluation of cell-material interface following the protocol: fixation in Karnovsky's solution for 1 h, washing with cacodilate buffer 0.1 M pH 7.2, fixation in 1% osmium tetroxide for 1 h, dehydration in an increasing ethanol series (30, 50, 70, 90 and 100%, 10 min each), critical point drying (CPD.030; BAI-Tec AG, Liechtenstein), sputter-coating with gold and analysis with a scanning electron microscope (JSM-5800LV; JEOL, Tokyo, Japan) (Fig. 1).




Figure 1. Incubation of PDC with HA-COL graft (A). SEM micrograph showing cell adhesion on HA granules in 6 days after seeding (B).

### Critical-Size Defects in Rat Calvaria

Adult rats (n=40, including the 10 donor/host animals of autogenous PDC) were put under systemic anesthesia, incised in the skull for a total flap and creation of rcCSD with an 8-mm diameter trephine bur (SIN, São Paulo, SP, Brazil). The osteotomized fragment was removed thoroughly and the defect was full filled with: blood clot (Group 1 - G1 - negative control), autogenous particulate bone from skull (Group 2 - G2 - positive control), HA-COL xenograft (Group 3 - G3) and HA-COL xenograft with autogenous PDC (Group 4 - G4). Afterwards, the flap was replaced and sutured. Euthanasia by anesthetic overdose occurred at 1 (n=20) and 3 months (n=20) after surgery and the skull samples were fixed with 4% buffered formalin for 48 h.

### Radiographic Processing and Evaluation

The parameters for digital radiographs of skulls with a microfocus x-ray machine (FXS-100.10; Feinfocus USA Inc., Trenton, NJ, USA) were 40 kV tension, 125  $\mu$ A electric chain, exposure time of 600 s, source-detector distance of 2 m, source-object of 40 cm,  $\times 5$  factor of magnification, 50  $\mu$ m pixel size and x-ray focal size of  $\sim 10$   $\mu$ m. Phosphorous plate detected latent image (Image Plate IPX; GE Inspection Technologies GmbH, Huerth, Germany) using a desk scanner (CR-50P; GE Inspection Technologies GmbH).

### Histopathological Processing and Evaluation

The excisional necropsies of skulls were decalcified in fast bone demineralization solution (Alkimia Comércio de Materiais para Laboratórios Ltda., Campinas, SP, Brazil) for 48 h, washed for 1 h, dehydrated in ethanol (Vetec Química Fina Ltda., Duque de Caxias, RJ, Brazil), clarified in xylol (Vetec Química Fina Ltda.), impregnated and included in paraffin (Vetec Química Fina Ltda.). Five-micrometer-thick sections were stained by hematoxylin-eosin and examined by an experienced pathologist. Descriptive analysis, comparative of intra- and inter-group biological response, was based on the type and intensity of inflammatory alterations and repair processes (fibrosis, new blood vessels and osteogenesis). Photomicrographs were obtained with a digital camera (Cybershot DSC-W300; Sony, Manaus, AM, Brazil) connected to an optical microscope (FWL-1000; Feldman Wild Leitz, Manaus, AM, Brazil).

### Histomorphometric and Statistical Analyses

Digital images of non-superimposed contiguous fields (6-8 *per* slide,  $\times 170$  magnification) covered the extension of rcCSD allowed the analysis using Image Pro-Plus 6.0 (Media Cybernetics, San Diego, CA, USA), calibrated in micrometers/pixel and with a 100 points grade (12). Determination of number of points upon connective tissue, blood tissue, new bone tissue, old bone tissue and graft biomaterial permitted the calculation of volume density of each parameter. Two independent and calibrated researchers evaluated the images (maximum media variation lower than 0.01%, paired *t* test (InStat 3.01; Graphpad Software Inc., San Diego, CA, USA). Mean volume density and standard deviation data were subjected to ANOVA and Tukey's test, considering significant differences if  $p < 0.05$ .

## RESULTS

Rat PDC on passage 2 cultivated in an osteogenic medium were capable of differentiating and producing mineralized nodules after 21 days (data not shown), confirmed by ALP assay and von Kossa staining, respectively. Ultrastructural analysis of PDC after 6 days culture over HA-COL showed cell attachment on apatite granules (Fig. 1). The rcCSD were filled with blood clot, autogenous bone, HA-COL and HA-COL plus PDC.

### Radiographic Analysis

At 1 month, there was no bone formation at the center of the rcCSD. G1 and G2 had mild peripheral alteration suggesting bone growing toward the middle of the rcCSD, while G3 and G4 showed xenograft filling the rcCSD with lower level of gray than old bone.

At 3 months, G1 showed suggestive image of new bone from border to center of the lesion presenting sharp margins and levels of gray similar to old bone. G2 showed rcCSD almost full filled of irregular autograft fragments presenting levels of gray similar to old bone. In G3 and G4, the xenograft was in close contact to the bone margin of the rcCSD, but still with a low level of gray in comparison with old bone.

### Histopathological Analysis

Histopathological analysis of the middle of the rcCSD at 1 month showed in G1 (Fig. 2A) presence of



loose to dense connective tissue, surrounding islets of bone tissue originated by intramembranous ossification. In G2 (Fig. 2B), presence of distinct fragments of old bone, interposed by connective tissue, blood vessels and reversion lines indicating the beginning of new bone formation were observed. The findings in G3 (Fig. 2C) were presence of granules of HA in different sizes interposed by loose connective tissue with moderate presence of multinucleated foreign body giant cells

(MGC), new blood vessels and areas of intramembranous ossification. In G4 (Fig. 2D), there was intense presence of cells around the HA, still surrounded by some MGC.

At 3 months, G1 (Fig. 2E) was filled with connective tissue and new amorphous bone in greater density. In G2 (Fig. 2F), fragments of fused autogenous bone inducing new and well-cellularized bone formation with blood vessels could be seen. In G3 (Fig. 2G), there was ossification around and directly in contact to HA in

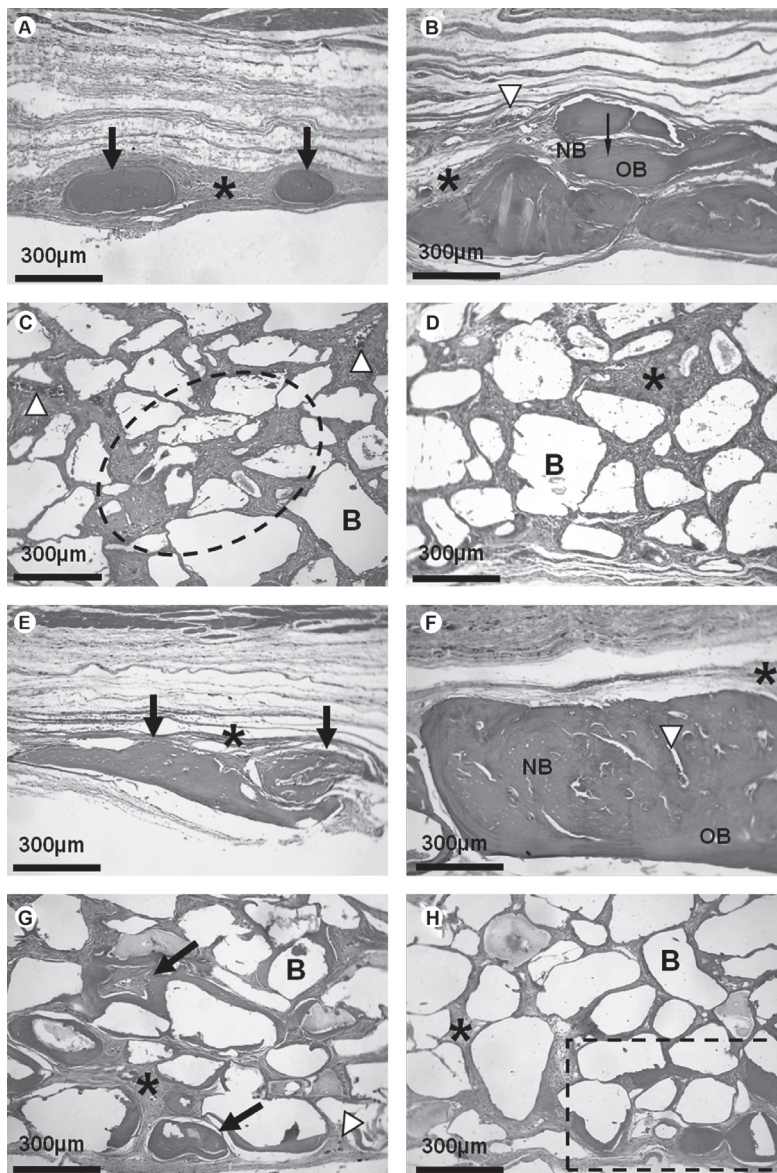


Figure 2. Histopathological analysis. After 1 month: Bone islets (arrow) in the middle of defect surrounded by fibrous connective tissue (\*,A); New bone (NB) in contact to old bone (OB) with fibrous tissue (\*) and blood vessel (white arrow head, B); Different size particles of biomaterial (B, HA-COL) without (C) or with cells (D) surrounded by loose connective with blood vessels (white arrow head). After 3 months. Discrete increase in the size of new bone in G1 (E) in opposition to large amount of bone in G2 containing blood vessels (white arrow head, F); New bone in contact to xenograft biomaterial (G and H, black arrow) surrounded by fibrous connective tissue (\*).

a moderate intensity (substitution of granule by bone) and homogenous way, though areas of dense connective tissue with some MGC were found. In G4 (Fig. 2H), there were HA granules interposed by dense connective tissue with focal or heterogeneous areas of ossification

and some MGC, from mild to moderate intensity.

**Histomorphometric Analysis**

Histomorphometric analysis (Fig. 3A) showed

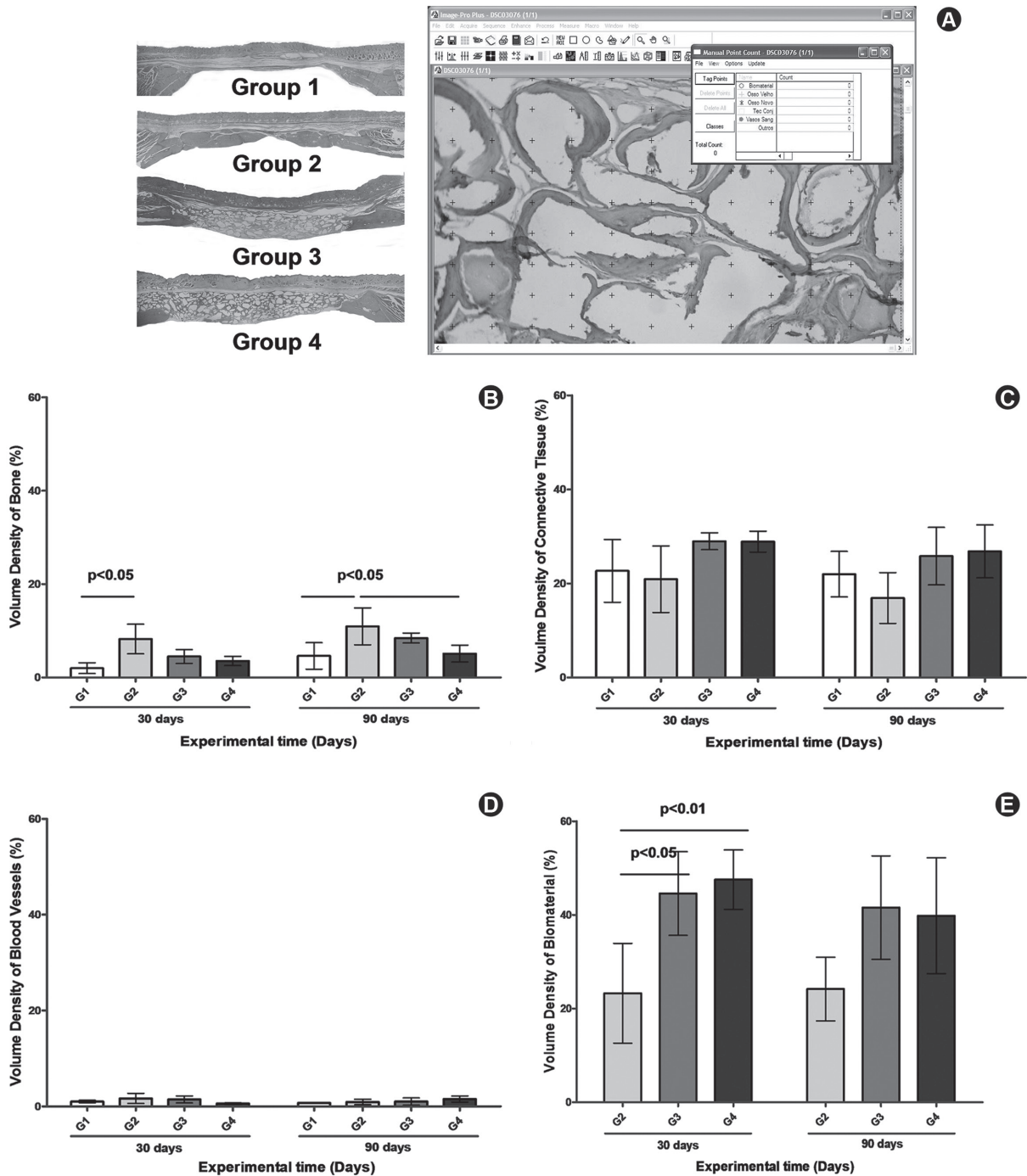


Figure 3. Images from border to border in each experimental group obtained from histomorphometric analysis (A). Volume density was determined for new bone (B), connective tissue (C), blood vessel (D) and residual biomaterial (E). Bars represent the 95% confidence interval of five animals per group.

that there was greater bone formation in G2 similar to G3 in comparison to G1 and G4, but similar levels in G4 and G1, after 3 months (Fig. 3B). No significant difference was found for connective tissue (Fig. 3C) and blood vessels density volume among groups at either of the evaluation times (Fig. 3D). The presence of biomaterial (G3 and G4) throughout the experimental period suggested absence of degradation (Fig. 3E).

## DISCUSSION

Cell-based therapy of bone loss has been increasingly studied but gaps still remains. The results of this study showed that PDC used in combination with a xenograft composite (HA-COL) did not enhance bone repair of rcCSD.

Primary cultures have limitations because they can present a mixture of osteoblast cells in different stages of differentiation besides other lineages. On the other hand, well-differentiated cells are difficult to expand and they could lose their osteogenic potential. Mesenchymal stem cells can easily proliferate, but directing them to osteogenic differentiation still is a greater challenge. Co-culture of both cells have shown later mineralization (13). Bone marrow is an usual source of bone cells (14), but harvesting these cells are frequently related to pain and morbidity. Alternatively, periosteum has been reported as a reliable source of osteogenic cells (15,16) allowing bone reconstruction around dental implants (17).

The rcCSD is a good model to study bone therapies due to its morphological similarity to maxillofacial region, allowing radiographic and histological analyses. Also, the fact that no complete repair occurs during the animal life allows evaluating the biomaterial functionality (6).

Although digital radiography produces enhanced images than conventional processing (11), it was not possible to discriminate bone and biomaterial structures, due to the very similar intensity in their gray scale, impairing counting of the area of new bone in G3 and G4. On the other hand, histological analysis confirmed that the rcCSD did not regenerate during the experimental period observed as previously reported, presenting a fibrous tissue fulfilling the bone defect (6,11,18,19). In addition, the inflammatory reaction to HA enables the recruitment of MGC around the biomaterials particles and, on the other hand, the use of autograft induces the almost complete closing of bone defect (6,11,18,19).

The normal bone repair of rcCSD varies from

7.6% (18) in 8 weeks to 12% in 12 weeks (20). The use of biomaterials increases these values, from 15.8% (18) to 40% in 8 weeks and from 24% (20) to 53.54% (15) in 12 weeks. Cell therapy has shown positive results using PDC and carriers, producing 3 times more bone augmentation with poly (glycolic-co-lactic acid) (PLGA) (3) or 6 times with COL (5) compared to untreated groups. In comparison with the carrier alone, the combination reaches twice the efficacy with PGLA (3).

PDC have been shown to present osteogenic potential and adherence to COL carrier, but they did not show greater new bone formation rcCSD than the material alone (21). Cell behavior is influenced by topography of the material (22). HA with regular surfaces stimulate proliferation, protein synthesis, ALP activity and presence of mineralization nodules (23). However, long-term contact (6 months) between trabecular bone-derived cells and natural apatite (anorganic bovine bone) grafted in human maxilla inhibits osteoblast-like phenotype *in vitro* (24). Further longer pre-culture periods have a critical role in differentiation process for lead to a progressively diminishing of osteoinductivity (25). In this way, the worst performance of the xenograft with cells could be explained by (i) unfavorable adhesion and the challenge to differentiate PDC upon inappropriate material as cell carrier during the experimental period or (ii) inhibition of cellular proliferation and osteoinductive potential due to long pre-culture period in osteogenic media *in vitro* (6 days) before implantation into an orthotopic site (rcCSD) for *in vivo* study. New strategies must be developed to improve the synergistic success of cell therapy with PDC and the composite carrier.

Within the limitations of this study, it may be concluded that combination of PDC with xenograft based on HA-COL did not enhance osteogenesis in rcCSD, despite biomaterial biocompatibility and osteoconduction capacity. The biomaterial alone showed similar efficiency as that of autogenous bone and appears as a good choice for bone loss therapies.

## RESUMO

O objetivo deste estudo foi avaliar o reparo ósseo usando células derivadas de periosteio (PDC) e apatita inorgânica e colágeno bovinos (HA-COL). PDC de ratos Wistar (n=10) foram semeadas sobre discos de HA-COL e osteoinduzidas por 6 dias. Defeitos de tamanho crítico em calvárias de ratos foram tratados com coágulo sanguíneo (G1), osso autógeno (G2), HA-COL (G3) ou HA-COL associado a PDC (G4) (n=40) e analisados em 1 e 3 meses após as cirurgias. Análise radiográfica não exibiu mudança temporal significativa, G1 e G2 tiveram aumento discreto de novo osso



marginal, entretanto a radiopacidade dos materiais de enxerto em G2, G3 e G4 prejudicou a detecção de osteogênese. Análise histopatológica mostrou em 3 meses ilhotas de ossificação em G1 que foi maior em G2, novo osso homogêneo ao redor de HA-COL em G3 e novo osso heterogêneo ao redor de HA-COL em G4 além da presença moderada de células gigantes de corpo estranho em G3 e G4. Análise histomorfométrica mostrou a densidade de volume inalterada do xenoenxerto ( $p > 0,05$ ) e a densidade de volume de novo osso em G2 duas vezes maior que G1 e G4 após 3 meses ( $p < 0,05$ ), mas similar a G3. PDC não aumentaram a formação óssea *in vivo* apesar do biomaterial sozinho ter apresentado biocompatibilidade e capacidade osteocondutora.

## ACKNOWLEDGEMENTS

The authors acknowledge the Brazilian Funding Agencies that supported this research: CNPq (Grant number 552644/05-6), FAPERJ and FINEP. Thanks to Silvestre Labs by xenograft donation. We acknowledge the technicians Lidia Agata de Sena (INMETRO) and Adriana Brandao Ribeiro Linhares (UFF) for the SEM analysis, the professors Inaya Correa Barbosa Lima and Ricardo Tadeu Lopes (UFRJ) for radiographic analysis and the professors Mario Tanomaro Filho and Renato de Toledo Leonardo for the scientific collaboration.

## REFERENCES

- Langer R, Vacanti JP. Tissue engineering. *Science* 1993;260:920-926.
- Agata H, Asahina I, Yamazaki Y, Uchida M, Shinohara Y, Honda MJ, et al.. Effective bone engineering with periosteum-derived cells. *J Dent Res* 2007;86:79-83.
- Breitbart AS, Grande DA, Kessler R, Ryaby JT, Fitzsimmons RJ, Grant RT. Tissue engineered bone repair of calvarial defects using cultured periosteal cells. *Plast Reconstr Surg* 1998;101:567-574.
- Hayashi O, Katsube Y, Hirose M, Ohgushi H, Ito H. Comparison of osteogenic ability of rat mesenchymal stem cells from bone marrow, periosteum, and adipose tissue. *Calcif Tissue Int* 2008;82:238-247.
- Sakata Y, Ueno T, Kagawa T, Kanou M, Fujii T, Yamachika E, et al.. Osteogenic potential of cultured human periosteum-derived cells - a pilot study of human cell transplantation into a rat calvarial defect model. *J Craniomaxillofac Surg* 2006;34:461-465.
- Silva IIC, Pimentel-Soares S, Bittencourt RC, Granjeiro JM. Natural bovine anorganic apatite and collagen presents osteoconductivity and contribute to bone repair of rat calvaria critical size defect. *Key Eng Mater* 2009;396-398:249-252.
- Ber S, Torun KG, Hasirci V. Bone tissue engineering on patterned collagen films: an *in vitro* study. *Biomaterials* 2005;26:1977-1986.
- Habibovic P, Krut MC, Juhl MV, Clyens S, Martinetti R, Dolcini L, et al.. Comparative *in vivo* study of six hydroxyapatite-based bone graft substitutes. *J Orthop Res* 2008;26:1363-1370.
- Rodrigues CV, Serricella P, Linhares AB, Guerdes RM, Borojevic R, Rossi MA, et al.. Characterization of a bovine collagen-hydroxyapatite composite scaffold for bone tissue engineering. *Biomaterials* 2003;24:4987-4997.
- Vidal BC. The use of a complex of collagen Type I with hydroxyapatite from bone, as a bone implant substitute: an experimental approach. *Tissue Eng* 1996;2:151-160.
- Marins LV, Cestari TM, Sottovia AD, Granjeiro JM, Taga R. Radiographic and histological study of perennial bone defect repair in rat calvaria after treatment with blocks of porous bovine organic graft material. *J Appl Oral Sci* 2004;21:62-69.
- Mandarim-De-Lacerda CA. Stereological tools in biomedical research. *An Acad Bras Cienc* 2003;75:469-486.
- Kim H, Lee JH, Suh H. Interaction of mesenchymal stem cells and osteoblasts for *in vitro* osteogenesis. *Yonsei Med J* 2003;44:187-197.
- Ribeiro FV, Suaid FF, Ruiz KG, Salmon CR, Paparotto T, Nociti FH Jr, et al.. Periosteum-derived cells as an alternative to bone marrow cells for bone tissue engineering around dental implants. A histomorphometric study in beagle dogs. *J Periodontol* 2010;81:907-916.
- Chen D, Shen H, Shao J, Jiang Y, Lu J, He Y, et al.. Superior mineralization and neovascularization capacity of adult human metaphyseal periosteum-derived cells for skeletal tissue engineering applications. *Int J Mol Med* 2011;27:707-713.
- Kawase T, Okuda K, Kogami H, Nakayama H, Nagata M, Sato T. Human periosteum-derived cells combined with superporous hydroxyapatite blocks used as an osteogenic bone substitute for periodontal regenerative therapy: an animal implantation study using nude mice. *J Periodontol* 2010;81:420-427.
- Ribeiro FV, Suaid FF, Ruiz KG, Rodrigues TL, Carvalho MD, Nociti FH, et al.. Peri-implant reconstruction using autologous periosteum-derived cells and guided bone regeneration. *J Clin Periodontol* 2010;37:1128-1136.
- Cardoso AK, Barbosa Jr AA, Miguel FB, Marcantonio Jr E, Farina M, Soares GD, et al.. Histomorphometric analysis of tissue responses to bioactive glass implants in critical defects in rat calvaria. *Cells Tissues Organs* 2006;184:128-137.
- Oliveira RC, Oliveira FH, Cestari TM, Taga R, Granjeiro JM. Morphometric evaluation of the repair of critical-size defects using demineralized bovine bone and autogenous bone grafts in rat calvaria. *Clin Oral Implants Res* 2008;19:749-754.
- Messora MR, Nagata MJ, Dornelles RC, Bomfim SR, Furlaneto FA, de Melo LG, et al.. Bone healing in critical-size defects treated with platelet-rich plasma activated by two different methods. A histologic and histometric study in rat calvaria. *J Periodontol Res* 2008;43:723-729.
- Keskin M, Kelly CP, Moreira-Gonzalez A, Loboocki C, Yarim M, Kaplan S, et al.. Repairing critical-sized rat calvarial defects with a periosteal cell-seeded small intestinal submucosal layer. *Plast Reconstr Surg* 2008;122:400-409.
- Bueno RBL, Adachi P, Castro-Raucci LMS, Rosa AL, Nanci A, Oliveira PT. Oxidative nanopatterning of titanium surfaces promotes production and extracellular accumulation of osteopontin. *Braz Dent J* 2011;22:179-184.
- Rosa AL, Beloti MM, van Noort R. Osteoblastic differentiation of cultured rat bone marrow cells on hydroxyapatite with different surface topography. *Dent Mater* 2003;19:768-772.
- Beloti MM, Martins Jr W, Xavier SP, Rosa AL. *In vitro* osteogenesis induced by cells derived from sites submitted to sinus grafting with anorganic bovine bone. *Clin Oral Implants Res* 2008;19:48-54.
- Castano-Izquierdo H, Alvarez-Barreto J, van der Dolder J, Jansen JA, Mikos AG, Sikavitsas VI. Pre-culture period of mesenchymal stem cells in osteogenic media influences their *in vivo* bone forming potential. *J Biomed Mater Res A* 2007;82:129-138.

Received January 25, 2011

Accepted June 10, 2011