

Non-Surgical Retreatment of a Failed Apicoectomy without Retrofilling Using White Mineral Trioxide Aggregate as an Apical Barrier

Spyridon Stefopoulos¹
Giorgos N. Tzanetakis²
Evangelos G. Kontakiotis²

¹Private Practice limited to Endodontics, Patras, Greece

²Department of Endodontics, Dental School, University of Athens, Athens, Greece

Root-end resected teeth with persistent apical periodontitis are usually retreated surgically or a combination of non-surgical and surgical retreatment is employed. However, patients are sometimes unwilling to be subjected to a second surgical procedure. The apical barrier technique that is used for apical closure of immature teeth with necrotic pulps may be an alternative to non-surgically retreat a failed apicoectomy. Mineral trioxide aggregate (MTA) has become the material of choice in such cases because of its excellent biocompatibility, sealing ability and osseoinductive properties. This case report describes the non-surgical retreatment of a failed apicoectomy with no attempt at retrofilling of a maxillary central incisor. White MTA was used to induce apical closure of the wide resected apical area. Four-year follow-up examination revealed an asymptomatic, fully functional tooth with a satisfactory healing of the apical lesion. White MTA apical barrier may constitute a reliable and efficient technique to non-surgically retreat teeth with failed root-end resection. The predictability of such a treatment is of great benefit for the patient who is unwilling to be submitted to a second surgical procedure.

Key Words: Apicoectomy, non-surgical retreatment, white mineral trioxide aggregate, apical barrier.

INTRODUCTION

Calcium hydroxide apexification has been the treatment of choice for immature teeth with necrotic pulps and open apices since the mid-1960's (1). However, the technique has certain disadvantages such as prolonged treatment time, need for multiple treatment visits, patient compliance problems, concerns about coronal microleakage, and an increased risk of root fractures (2-4).

In order to overcome the disadvantages of the apexification technique, an apical barrier technique or a so-called "one-visit apexification" has been proposed (5-7). Mineral trioxide aggregate (MTA) is currently considered the material of choice for apical closure due to its excellent biocompatibility, sealing ability and osseoinductive properties (5,8,9). The MTA apical barrier technique is becoming increasingly popular nowadays. The results from clinical prospective and/or retrospective studies along with case series and case

reports show that it is a reliable and efficient method of treating immature teeth with necrotic pulps with favorable results (10-15).

MTA was originally marketed in a gray formulation but it has been replaced by a white formulation due to tooth discoloration problems. The white formulation has a lower amount of iron, aluminum and magnesium compared to the gray one (16). At first there were some concerns about the clinical performance of white MTA compared with gray MTA. Clinical research, however, has confirmed the validity of its use. In particular, the use of white MTA as an apical plug has been confirmed by case reports (17) and clinical studies (10,12,15).

Apart from immature teeth with necrotic pulps, there are cases of mature teeth with complete root formation that need to be treated with an apexification technique as there is a lack of apical constriction. This may be due to apical resorption, perforation, overinstrumentation or failed apicoectomy without

placement of a retrofilling.

In the past, teeth with failed apicoectomies without retrofillings were retreated surgically or a combination of non-surgical and surgical procedures was employed. A predictable definitive non-surgical endodontic retreatment in such cases would be of great benefit to the patients. The use of the MTA apical barrier technique has been demonstrated in a case of failed apicoectomy of mandibular central incisors that were retreated non-surgically with a 2-year favorable recall examination (18). Similarly, a root-end resected mandibular lateral incisor with a large periradicular lesion was retreated with the use of the MTA plug, and a 30-month follow-up revealed normal periapical tissues as a result of treatment (19). Favorable results have been demonstrated for non-surgical retreatment of teeth with failed surgeries and amalgam root-end fillings, after orthograde removal of the retrofillings and placement of MTA apical plug (20).

To the best of our knowledge this is the first case report that validates the use of white MTA apical barrier technique to non-surgically retreat a failed root-end resected tooth as in previous reports gray MTA was used (19) or the MTA type (gray or white) was not specified (18,20).

CASE REPORT

A 28-year-old man was referred to our office for an evaluation of the maxillary left central incisor. His medical history was non-contributory and the patient reported an apicoectomy at that tooth 9 years before and a recent appearance of a fistula without any pain or tenderness. The intraoral examination revealed a tooth with multiple old composite resin restorations and a sinus tract at the apex of the tooth. A gutta-percha cone was used to trace the sinus tract and the radiograph disclosed an apical lesion and a resected apex without any attempt at retrofilling (Fig. 1).

The treatment plan was all-ceramic veneers in all four maxillary incisors and the referring dentist called for space for intraradicular retention of the restoration. The patient strongly rejected the idea of a second surgery so a non-surgical retreatment with the use of an MTA apical plug was chosen.

In the first visit, the root canal was accessed and the filling materials were removed using large Hedström files without the use of a solvent. Working length determination was a difficult task as the apex

locators gave contradictory results due to the open apex and the radiograph with a #140 Hedström in place was inconclusive due to the bevelling of the apex during root end resection (Fig. 2). Determination of the working length was done by placing a thick paper point in contact with the periapical tissues, under observation with the operating microscope (SOM62; Karl Kaps, Asslar/Wetzlar, Germany). The paper point was secured with tweezers and measured. Mechanical preparation was done using a #140 Hedström with brushing motions exerting very mild pressure. Chemical preparation was of utmost importance and abundant irrigation with 2.5% NaOCl was employed. Pure calcium hydroxide mixed with saline was placed as intracanal dressing using a lentulo spiral and canal entrance was sealed with an eugenol-free temporary filling (Cavit G; 3M ESPE, AG Seefeld, Germany).

Two weeks later the patient returned with no apparent sinus tract and the calcium hydroxide dressing was removed with light filling and abundant irrigation with 2.5% NaOCl. The canal was dried with sterile paper points and as there was no exudate, white MTA (ProRoot; Dentsply-Maillefer, Ballaigues, Switzerland) was placed at the apical region. MTA was mixed according to the manufacturer's instructions and was delivered as close to the apex as possible using a premeasured special MTA carrier (Micro-Apical Placement, Produits Dentaires, Vevey, Switzerland). The material was condensed using the thick end of a sterile large paper point under constant observation with the microscope, exerting very mild pressure to avoid extrusion of the material into the periapical tissues. The delivery and condensation steps were repeated 4 times until a 4 mm thickness of the plug was achieved. The result was confirmed radiographically (Fig. 3). An irregularly global appearance of the most apical part of the material was evident. A wet paper point was placed in contact with the MTA to ensure its proper setting and the patient was rescheduled for completion of treatment after 48 h.

In the third visit, the paper point was removed and the material was checked for proper setting and push-out strength with a large file. The rest of the canal was backfilled with thermoplasticized gutta-percha (Obtura II; Obtura Spartan, Fenton, MO, USA) and a resin-based root canal sealer (AH26; Dentsply DeTrey Konstanz, German). Gutta-percha level was maintained apically to the crestal bone to provide space for intraradicular retention and reinforcement of the tooth's fracture resistance by a deep bonded composite restoration by

the referring dentist.

The 4-year recall revealed that the tooth was fully functional and asymptomatic, with no sinus tract.

Radiographically, healing of the lesion and an induction of a hard tissue barrier apically to the MTA plug was evident (Fig. 4).

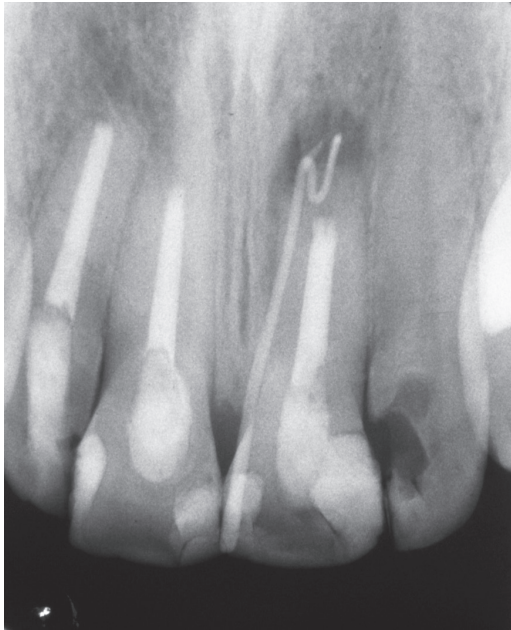

Figure 1. Preoperative radiograph. The root canal filling seems to be short of the apex probably due to an extensive beveling of the root tip during apex resection. No attempt at retrofilling is evident.

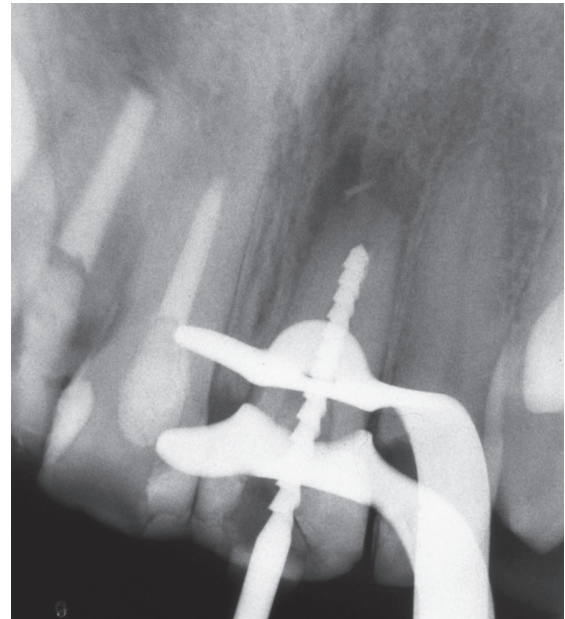

Figure 2. A #140 Hedström file was secured in place with the use of apex locators, but the estimation of the working length was inconclusive.

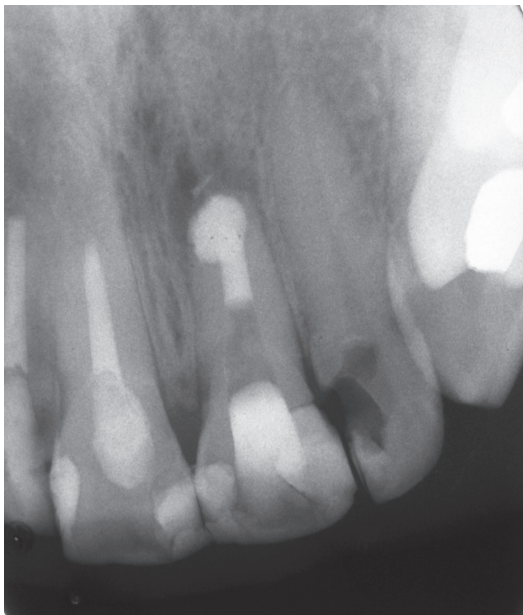


Figure 3. Radiograph of the apical barrier placement. An irregularly global apical part of the barrier is evident.

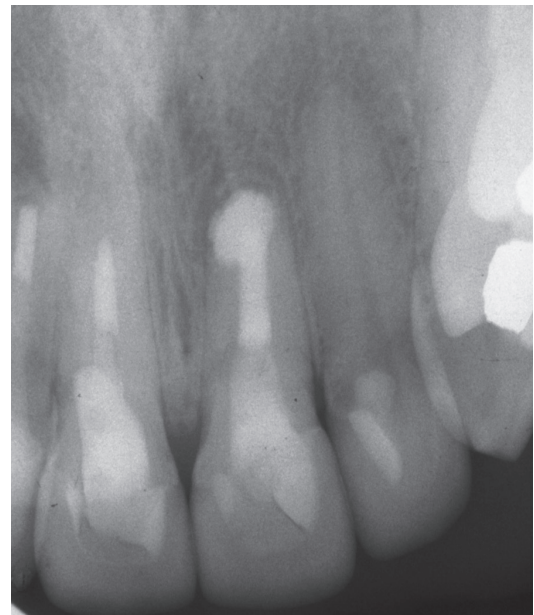

Figure 4. Four-year follow-up radiograph in which healing of the apical lesion is evident.

DISCUSSION

The treatment of choice for apicectomized teeth that lack a retrofilling and present persistent apical periodontitis is a second surgery following contemporary principles of endodontic microsurgery, or a combination of non-surgical and surgical retreatment can be employed. However, patients are often unwilling to be subjected to a second surgical procedure despite the fact that contemporary microsurgery has improved the success rates dramatically (21). The only alternative treatment is an attempt at nonsurgical retreatment with the use of an apexification technique to address the problem of the open apex at the apical region of such teeth. The disadvantages of the long-lasting calcium hydroxide apexification technique are well known. An apical barrier technique that would allow a predictable definitive treatment with long-term favourable results for failed apicectomized teeth would be of great benefit for both patient and doctor.

MTA is the material of choice for apical barrier techniques and in this case white ProRoot MTA was used for apical closure of the apicectomized central maxillary incisor. The beveling of the root tip during the apex resection made the working length determination an extremely difficult task. Although both radiographic and electronic methods were used, the results were unsatisfactory. In truth, the working length was calculated by placing a thick paper point in contact with the periapical tissues under the surgical microscope and then the paper point was measured from the reference point. An accurate estimation of the working length is essential for proper MTA placement and condensation at the apical part of the root (avoiding short placement or great overextension of the material).

To avoid MTA extrusion into the periapical tissues, the placement of an extraradicular matrix of resorbable materials (calcium sulfate or collagen type materials) has been proposed (22). In our case such a matrix was not used. The constant visualization of the procedure under the microscope coupled with very mild condensation pressure allowed satisfactory confinement of the material within the root canal. The strange, irregularly global shape of the barrier at its most apical part may be attributed to the bevelling of the root apex during primary surgery and a possible resorption at a later time due to the apical lesion. This barrier shape has been cited before, especially in cases of a complex wide apical root form (20).

The 4-year recall is considered the cut-off point to classify a root canal treatment as successful (normal periapical tissues, absence of signs and symptoms) or failed (persistent apical periodontitis and/or signs or symptoms) (23,24). To establish the most accurate estimation of the result of the described treatment, the 4 year recall is demonstrated. The patient was asymptomatic, the tooth was functional and radiographically there was satisfactory healing. More clinical case reports and clinical researches are needed in order to confirm the validity and predictability of the use of white MTA as an apical barrier for non-surgical retreatment of failed apicectomies.

The use of white MTA as an apical barrier to successfully retreat a failed apicectomy was demonstrated. If the results of such a treatment are proved reliable and predictable the avoidance of a second surgery would be a great benefit for the patient.

RESUMO

Dentes com periodontite persistente após apicectomia são comumente tratados cirurgicamente ou pela combinação de cirurgia e tratamento não-cirúrgico. Porém, alguns pacientes não aceitam se submeter a um segundo procedimento cirúrgico. A técnica da barreira apical, utilizada para fechamento apical de dentes com ápice aberto com necrose pulpar, pode ser uma alternativa não-cirúrgica para retratamento de casos de apicectomia mal sucedida. O agregado de trióxido mineral (MTA) tornou-se o material de escolha para estes casos devido a sua excelente biocompatibilidade, capacidade de selamento e propriedades osseointegrativas. O relato de caso aqui apresentado descreve o retratamento não-cirúrgico de uma apicectomia mal sucedida, sem retrobturação, de um incisivo central superior. Foi utilizado o MTA branco para induzir o fechamento apical da ampla área de ressecção radicular. O exame de acompanhamento quatro anos após o tratamento mostrou um dente assintomático e totalmente funcional com reparo satisfatório da lesão apical. A barreira apical com MTA branco pode ser uma técnica segura e eficaz para o retratamento não-cirúrgico de dentes com apicectomia mal sucedida. A previsibilidade de tal tratamento é um grande benefício para o paciente que não deseja ser submetido a um novo procedimento cirúrgico.

REFERENCES

1. Frank AL. Therapy for the divergent pulpless tooth by continued apical formation. *J Am Dent Assoc* 1966;72:87-93.
2. Rafter M. Apexification: a review. *Dent Traumatol* 2005;21:1-8.
3. Andreasen JO, Farik B, Munksgaard EC. Long-term calcium hydroxide as a root canal dressing may increase risk of root fracture. *Dent Traumatol* 2002;18:134-137.
4. Andreasen JO, Munksgaard EC, Bakland LK. Comparison of fracture resistance in root canal of immature sheep teeth after filling with calcium hydroxide or MTA. *Dent Traumatol* 2006;22:154-156.

5. Shabahang S, Torabinejad M, Boyne PP, Abedi H, McMillan P. A comparative study of root end induction using osteogenic protein-1, calcium hydroxide, and mineral trioxide aggregate in dogs. *J Endod* 1999;25:1-5.
6. Hachmeister DR, Schindler WG, Walker WA III, Thomas DD. The sealing ability and retention characteristics of mineral trioxide aggregate in a model of apexification. *J Endod* 2002;28:386-390.
7. Witherspoon DE, Ham K. One-visit apexification: technique for inducing root end barrier formation in apical closures. *Pract Proced Aesthet Dent* 2001;13:455-460.
8. Torabinejad M, Parirokh M. Mineral trioxide aggregate: a comprehensive literature review-Part II: Leakage and biocompatibility investigations. *J Endod* 2010;36:190-202.
9. Torabinejad M, Parirokh M. Mineral trioxide aggregate: a comprehensive literature review-Part III: Clinical applications, drawbacks, and mechanism of action. *J Endod* 2010;36:400-413.
10. Simon S, Rilliard F, Berdal A, Machtou P. The use of mineral trioxide aggregate in one-visit apexification treatment: a prospective study. *Int Endod J* 2007;40:186-197.
11. Pace R, Giuliani V, Pini Prato L, Baccetti T, Pagavino G. Apical plug technique using mineral trioxide aggregate: results from a case series. *Int Endod J* 2007;40:478-484.
12. Holden DT, Schwartz SA, Kirkpatrick TC, Schindler WG. Clinical outcomes of artificial root-end barriers with mineral trioxide aggregate in teeth with immature apices. *J Endod* 2008;34:812-817.
13. Witherspoon DE, Small JC, Regan JD, Nunn M. Retrospective analysis of open apex teeth obturated with mineral trioxide aggregate. *J Endod* 2008;34:1171-1176.
14. Sarris S, Tahmassebi JF, Duggal MS, Cross IA. A clinical evaluation of mineral trioxide aggregate for root-end closure of non-vital immature permanent incisors in children - a pilot study. *Dent Traumatol* 2008;24:79-85.
15. Moore A, Howley MF, O'Connell AC. Treatment of open apex teeth using two types of white mineral trioxide aggregate after initial dressing with calcium hydroxide in children. *Dent Traumatol* 2011;27:166-173.
16. Torabinejad M, Parirokh M. Mineral trioxide aggregate: a comprehensive literature review-Part I: Chemical, physical, and antibacterial properties. *J Endod* 2010;36:16-27.
17. D'Arcangelo C, D'Amaro M. Use of MTA for orthograde obturation of nonvital with open apices: report of two cases. *Oral Surg Oral Med Oral Pathol Oral Radiol Endod* 2007;104:e98-e101.
18. Hayashi M, Shimizu A, Ebisu S. MTA for obturation of mandibular central incisors with open apices: case report. *J Endod* 2004;30:120-122.
19. Kusgoz A, Yildirim T, Er K, Arslan I. Retreatment of a resected tooth associated with a large periradicular lesion by using a triple antibiotic paste and mineral trioxide aggregate: a case report with a thirty-month follow-up. *J Endod* 2009;35:1603-1606.
20. Pannkuk TF. A new technique for nonsurgical retreatment of teeth with amalgam root end fillings: case series. *J Endod* 2011;37:414-419.
21. Setzer FC, Shah SB, Kohli MR, Karabucak B, Kim S. Outcome of endodontic surgery: a meta-analysis of the literature - part I: comparison of traditional root - end surgery and endodontic microsurgery. *J Endod* 2010;36:1757-1765.
22. Trope M. Treatment of the immature tooth with a non-vital pulp and apical periodontitis. *Dent Clin North Am* 2010;54:313-324.
23. Strindberg LZ. The dependence of the results of pulp therapy on certain factors. An analytic study based on radiographic and clinical follow-up examination. *Acta Odontol Scand* 1956;14:Suppl. 21.
24. European Society of Endodontology. Quality guidelines for endodontic treatment: consensus report of the European Society of Endodontology. *Int Endod J* 2006;39:921-930.

Received November 29, 2011

Accepted February 10, 2012