

# Reestablishment of Occlusion through Overlay Removable Partial Dentures: A Case Report

César BATAGLION<sup>1</sup>  
 Takami Hirono HOTTA<sup>2</sup>  
 Wilson MATSUMOTO<sup>2</sup>  
 Carlos Ventura de Oliveira RUELLAS<sup>3</sup>

<sup>1</sup>Department of Restorative Dentistry, Ribeirão Preto Dental School,  
 USP - University of São Paulo, Ribeirão Preto, SP, Brazil

<sup>2</sup>Department of Dental Materials and Prosthesis, Ribeirão Preto Dental School,  
 USP - University of São Paulo, Ribeirão Preto, SP, Brazil

<sup>3</sup>Paulista Association of Dental Surgeon of Ribeirão Preto, SP, Brazil

Loss of posterior teeth may cause an imbalance in the stomatognathic system. Overlay removable partial dentures (ORPD) are a reversible and relatively inexpensive treatment for patients with severely worn teeth. This paper presents a treatment with ORPD in a 55-year-old male patient who had severe attrition in the maxillary and mandibular teeth, temporomandibular joint pain and reduced vertical dimension of occlusion (VDO). The treatment consisted in the reestablishment of the VDO using Lucia's jig, fabricating removable partial denture with reconstruction of the worn teeth without preparation. This therapy can be used as an alternative treatment to provide esthetic, function and stable occlusion in patients with severely worn teeth.

Key Words: overlay removable partial dentures, occlusal vertical dimension, stable occlusion.

## INTRODUCTION

Failure to replace a missing posterior tooth is assumed to disrupt the balance of the stomatognathic system (1) with a consequent alteration in the vertical dimension of occlusion (VDO) (2). Loss of VDO may be caused by physiological tooth wear and it is usually compensated for by continuous tooth eruption and alveolar bone growth (3), as well as in situations where tooth wear exceeds compensatory mechanisms (4).

A treatment option may be the overlay removable partial denture (ORPD), which is a prosthesis that covers and rests on one or more natural teeth, the roots of the natural teeth (5-10). This paper reports a clinical situation in which an ORPD was used to treat teeth with severe wear and absence posterior occlusal support.

## CASE REPORT

A 55-year-old Black male patient came to the

Course of Occlusion, Temporomandibular Dysfunction and Orofacial Pain in Special Needs Patients at the Ribeirão Preto Dental School - USP, Brazil, complaining of the worn appearance of his teeth. He was informed about the procedure and his consent was obtained. The investigation was approved by the instructional Ethics Committee (Protocol #2004.1.620.58.6).

Clinical examination revealed severe tooth wear and some missing posterior teeth (Fig.1A). Maxillary and mandibular impressions were made with irreversible hydrocolloid (Jeltrate Plus; Dentsply Ind. e Com. Ltda., Petrópolis, RJ, Brazil) in autopolymerizing acrylic resin custom trays (Clássico Artigos Odontológicos, São Paulo, SP, Brazil). The angles of a semi-adjustable articulator were registered at the means values (15 degrees for the Bennett angle and 30 degree for the path condylar angle). The maxillary cast was mounted on a semi adjustable articulator using a face-bow record. The mandibular cast was mounted in centric relation using Lucia's jig. Clinical determination of the VDO was

achieved by the use Willis compass and registered on Lucia's jig (7). The interocclusal space measured was 10 mm, hence, the worn teeth were restored in such a way as to increase the VDO by 7.0 mm and thereby leaving 3.0 mm of interocclusal space.

Then, the re-establishment of the clinical crown size of the missing teeth was started, according to the appropriate vertical dimension of occlusion, using overlay removable partial dentures (5,6). For this, rest seat preparations were needed, the frameworks were made using CoCr alloy and artificial acrylic resin teeth were added. The overlays were processed with heat-polymerizing acrylic resin (Clássico Artigos Odontológicos) and tooth-colored heat-polymerizing acrylic resin polyglass (Artglass; Heraeus Kulzer, Wehrheim, Germany) for the overlay portion of the prosthesis (Figs. 1B and 1C).

The artificial teeth were arranged and tried-in to verify jaw relation records and obtain the patient's approval before final processing. After deflasking procedures, occlusion was adjusted and the prostheses were finished and polished.

The overlays were inserted (Fig. 1D) and the follow-up for clinical evaluations occurred weekly

during 6 months. Necessary adjustments were made on the centric and the eccentric mandibular positions.

The treatment promoted the re-establishment of vertical dimension of occlusion, the occlusal contacts that were distributed in a simultaneous and homogeneous way, better clinical conditions of masticatory muscles and consequently, coordinated mandibular movements. These results were observed by the analyses of the static and dynamics occlusal contacts, the muscles digital palpations, the range of mouth opening and the eccentric mandibular movements (lateral and protrusion) (2,6). After this time, the follow-up for evaluations were made monthly during 1 year.

## DISCUSSION

The patient of this case showed accentuated wear of the anterior teeth, mainly in the maxilla, probably because the loss of bilateral posterior teeth caused an overload on the anterior region. Thus, it was necessary to re-establish the maxillomandibular relationship using ORPD (6), which is a removable prosthesis constructed over natural teeth.

Considering that restorative procedures for

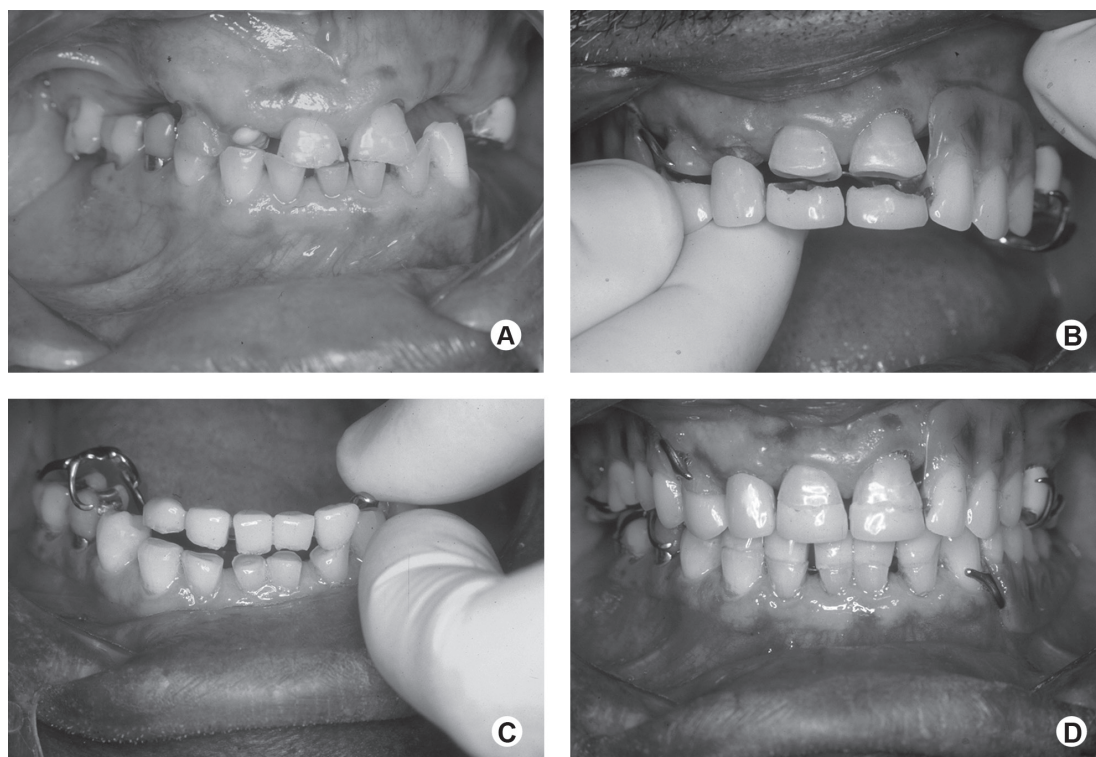


Figure 1. Clinical procedures. A: Intraoral frontal view of maxillary and mandibular dentitions. B: Intraoral frontal view of maxillary ORPD insertion. C: Intraoral frontal view of mandibular ORPD insertion. D: Intraoral frontal view of restored dentition.

the elderly patient should be conservative and should maintain the dental structures intact, functional, comfortable, and aesthetically pleasant (11), the ORPD were the best choice of treatment.

The retention system of this prosthesis was made by means of a metallic framework which has retentive circumferential clasp arms engaging the last molars, as earlier study (11,12).

Furthermore, the ORPD have been suggested to be efficient and cost effective with the final outcome pleasing to the patient (4,8). However, disadvantages of these prostheses include esthetic issues, caries or periodontal disease if poor oral hygiene is present (4). So, the patient should be aware of these factors before agreeing with the treatment. The other disadvantage of these prostheses is that their cast metal denture base may be an additional difficulty in future relining (11).

In the present case, the different treatment modalities were explained to the patient (endodontic, implants, fixed restorations, conventional partial removable dentures) previously, as recommended (13), the advantages as cost and conservative approach were considered very important aspects.

In addition to the esthetic concerns, the patient presented clinical features, such as absence of multiple teeth and posterior edentulous spaces, that are the classical indication for ORPD (14). The use of ORPD in this case promoted facial appearance improvement by the reestablishment of VDO and the esthetic expectations were successfully fulfilled.

Through periodic analysis of the function of these prostheses, it was possible to verify that the integrity of the maxillomandibular relationship was maintained as well as the masticatory system functions, such as speaking and chewing.

Several therapies could be used in this case but a conservative treatment approach was agreed as the best choice. In conclusion, the treatment was effective because it solved the patient's esthetic concerns and improved the masticatory functions.

## RESUMO

A perda de dentes posteriores pode provocar o desequilíbrio do sistema estomatognático. As próteses parciais removíveis terapêuticas atuam como terapia reversível e não dispendiosa para os pacientes com desgastes dentais severos. Este trabalho apresenta um tratamento com as próteses parciais removíveis terapêuticas (overlay) em um paciente de 55 anos, do gênero masculino que apresentava atrição severa nos dentes superiores e inferiores, dor na articulação temporomandibular e dimensão

vertical de oclusão reduzida. O tratamento consistiu em restabelecer a dimensão vertical de oclusão utilizando o Jig de Lucia, próteses parciais removíveis com reconstrução dos dentes desgastados e sem preparos. Esta terapia pode ser utilizada como uma alternativa de tratamento para a obtenção de estética, função e estabilidade oclusal em pacientes com desgastes dentais severos.

## REFERENCES

1. Shugars DA, Bader JD, Phillips Jr., White A, Brantley F. The consequences of not replacing a missing posterior tooth. *J Am Dent Assoc* 2000;131:1317-1323.
2. Hotta TH, Vicente MFR, Reis AC, Bezzon OL, Bataglion C, Bataglion A. Combination therapies in the treatment of temporomandibular disorders: a clinical report. *J Prosthet Dent* 2003;89:536-539.
3. Murphy T. Compensatory mechanisms in facial height adjustment to functional tooth attrition. *Aust Dent J* 1959;4:312-323.
4. Ganddini MR, Al-Mardini M, Graser GN, Almog D. Maxillary and mandibular overlay removable partial dentures for the restoration of worn teeth. *J Prosthet Dent* 2004;91:210-214.
5. Hotta TH, Bataglion A, Bataglion C, Bezzon OL. Involvement of dental occlusion and trigeminal neuralgia: a clinical report. *J Prosthet Dent* 1997;77:343-345.
6. Hotta TH, Nunes LJ, Quatrini AH, Bataglion C, Nonaka T, Bezzon OL. Tooth wear and loss: symptomatological and rehabilitative treatments. *Braz Dent J* 2000;11:147-152.
7. Sato S, Hotta TH, Pedrazzi V. Removable occlusal overlay splint in the management of tooth wear: a clinical report. *J Prosthet Dent* 2000;83:392-395.
8. Matsumoto W, Hotta TH, Bataglion C, Rodvalho GV. Tooth wear: use of overlays with metallic structures. *J Craniomandib Pract* 2001;19:61-64.
9. Del Castillo R, LaMar Jr. F, Ercoli C. Maxillary and mandibular overlay removable partial dentures for the treatment of posterior open-occlusal relationship: a clinical report. *J Prosthet Dent* 2002;87:587-592.
10. Fonseca J, Nicolau P, Daher T. Maxillary overlay removable partial denture for restoration of worn teeth. *Compend Contin Educ Dent* 2011;32:14-20.
11. Guttal S, Patil NP. Cast titanium overlay denture for a geriatric patient with a reduced vertical dimension. *Gerodontology* 2005;22:242-245.
12. Freitas AC Jr, Silva AM, Lima Verde MA, Jorge de Aguiar JR. Oral rehabilitation of severely worn dentition using an overlay for immediate re-establishment of occlusal vertical dimension. *Gerodontology* 2012;29:75-80.
13. Zarati S, Ahmadian L, Arbabi R. A transitional overlay partial denture for a young patient: a clinical report. *J Prosthodont* 2009;18:76-79.
14. Bezzon OL, Gonçalves M, Pagnano VO. T-bar clasp-retained removable partial denture as an alternative to implant-based prosthetic treatment. *Braz Dent J* 2008;19:257-262.

Received October 21, 2010

Accepted February 8, 2012