

Palatal Harvesting Technique Modification for Better Control of the Connective Tissue Graft Dimensions

Danilo Maeda Reino, Arthur Belém Novaes Jr., Márcio Fernando de Moraes Grisi, Luciana Prado Maia, Sérgio Luis Scombatti de Souza

Department of Oral and Maxillofacial Surgery and Traumatology and Periodontology, Ribeirão Preto School of Dentistry, USP - University of São Paulo, Ribeirão Preto, SP, Brazil

Correspondence: Prof. Dr. Sérgio Luis Scombatti de Souza. Avenida do Café, s/n, Monte Alegre, 14040-904, Ribeirão Preto, SP, Brasil. Tel: +55-16-3602-3980. e-mail: scombat@forp.usp.br

Subepithelial connective tissue graft (SCTG) has been extensively used for a variety of clinical applications. However, the surgical procedure may not allow control of graft thickness. The purpose of this case series is to illustrate a modification to the single incision palatal harvesting technique in order to control the SCTG thickness without increasing patient discomfort. Fifty cases from thirty systemically and periodontally healthy patients with at least one multiple gingival recession were treated with coronally advanced flaps combined with a SCTG. The palatal area served as the donor site, from where a single perpendicular incision was made to obtain a full thickness flap. Next, 1-2 mm of the flap was elevated and dissected to obtain a partial thickness flap. The graft remained attached to the full-partial thickness flap. After determining the desired SCTG thickness, the graft was harvested from the palatal flap. The patients healed uneventfully at 7 days postoperatively and primary closure was obtained for all palatal donor sites. The SCTG length and width varied depending on the needs of each case, but the SCTG thickness was well controlled with only 0.24 mm standard deviation. The suggested modification granted control of the SCTG dimensions and achieved complete wound closure within a week.

Key Words: connective tissue, grafts, surgery.

Introduction

For many reasons, patients may present loss of gingival tissue, which can negatively affect esthetics and function. The subepithelial connective tissue graft (SCTG) technique has been used to increase the height and thickness of keratinized mucosa (1), to correct uneven gingival margins and edentulous alveolar ridge depressions (2) and to remove amalgam tattoos (3). SCTG is predictably used to treat gingival recessions and to manage root sensitivity (4, 5). Recently, SCTG was also used with immediate implants, to obtain esthetics in anterior areas (6).

Several techniques have been proposed to obtain autogenous SCTG. Some surgeons use a method that consists in creating a partial-thickness trapezoidal palatal flap followed by SCTG harvesting (7,8). The use of this technique has been abandoned because it may compromise the vascularization of the flap, resulting in delayed healing (7, 8).

Another technique proposed to harvest a SCTG is to remove a free gingival graft and then bisect it into one part with connective tissue and another piece with epithelium and a thin connective tissue (9). McLeod et al. (10) considered it a challenging technique because it is often difficult to bisect the free gingival graft removed and proposed a modification: a back-action periodontal surgical chisel was previously used to deepithelialize the donor

site, and a gingivectomy was made to harvest the graft. These techniques present greater morbidity and produce more discomfort to patients because the connective donor site remains uncovered and the healing occurs by second intention.

Some other techniques were developed in an attempt to generate less connective donor site exposure, and to obtain better healing. An incision design was described to harvest the SCTG with a band of epithelium (11), and a single incision technique was created to harvest a full thickness SCTG (12). These two techniques reduce patient morbidity, but may result in a small void at the donor site, often requiring long periods to repair for second intention (13).

Recently, the single incision technique was modified to avoid causing the void at the donor site, with the objective of reducing patient morbidity and to accelerate the donor site healing (13). This modification is the less invasive technique for SCTG harvesting, but it also removes a full thickness SCTG, which may jeopardize the healing of the donor site. Additionally, more fat tissue can be harvested with the graft, which is not desirable. Furthermore, with this technique it is difficult to control the thickness of the harvested graft.

Each technique to harvest autogenous SCTG has benefits and disadvantages. The purpose of this report is to describe a modification of the single incision technique

without removing the periosteum from the donor site, in an attempt to control the thickness of the harvested SCTG without increasing patient discomfort or morbidity.

Material and Methods

Thirty patients received 50 periodontal plastic surgeries for the treatment of multiple gingival recessions within a 6-month period. The patients agreed to participate in this study and gave their written informed consent on an Institutional Review Board consent form, in accordance with the Helsinki Declaration of 1975, as revised in 2002. Patients with systemic disease or any contraindication for surgery were excluded from the study. Previously, all patients had general oral hygiene instructions to eliminate habits related to the etiology of the gingival recessions and received basic periodontal treatment, consisting of scaling and root planing.

Recipient Site Preparation

After local anesthesia, the recipient site was prepared as described for the coronally advanced flap technique (14) (Fig. 1A). Oblique submarginal incisions and intrasulcular incisions were made at the defect area (Fig. 1B) to create surgical and anatomical papillae. Then, a partial thickness dissection was achieved by raising an envelope flap. The root surfaces were mechanically treated with the use of curettes and the remaining tissue of the anatomical papillae was de-epithelialized to create connective tissue beds for the surgical papillae. Gauze was placed on the recipient site until the donor site tissue was harvested.

Donor Tissue Harvesting

Tissue dimensions required for root coverage were precisely evaluated. After local anesthesia, a single incision approximately 3 mm apical to the gingival margin of the maxillary teeth was made, as described in the modified single incision technique (13). The incision was made perpendicular to the palatal tissue until reaching the bone in a horizontal direction (Figs. 2A and 3A). The length of the incision is

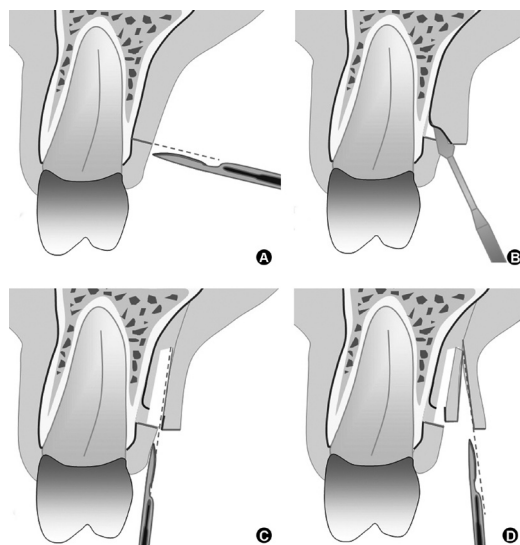


Figure 2. Schematic illustration of the new modification for the single incision palatal harvest technique. A: Incision perpendicular to the palatal tissue until reaching the bone in a horizontal direction. B: Elevation of 1 to 2 mm of a full thickness flap. C: Dissection of the partial thickness flap. D: Graft harvesting from the flap.

D.M. Reino et al.

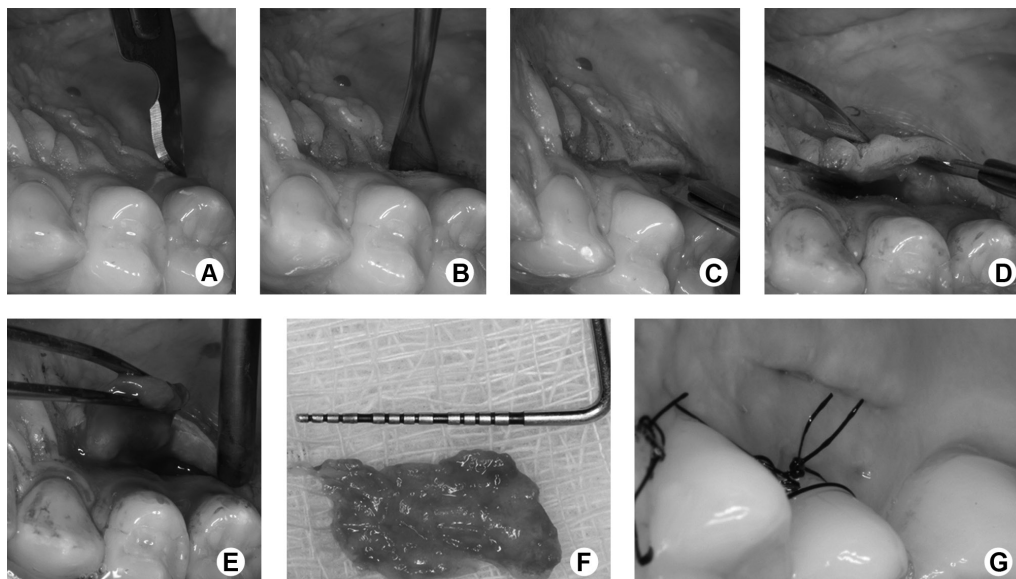


Figure 1. Surgery at the recipient site. A: Preoperative multiple gingival recession. B: Oblique incisions. C: SCTG fixed at the recipient site. D: Sutures. E: Postoperative image of the treated area after 6 months.

determined by the dimensions of the graft required.

A small elevator was used to carefully elevate a 1 to 2 mm full thickness flap, which facilitates flap dissection (Figs. 2B and 3B). Then, a blade was used to dissect a partial thickness flap following the full thickness flap raised (Figs 2C and 3C). The periosteum was kept covering the bone and most part of the connective tissue remained fixed to the full-partial thickness flap, in such a way that graft thickness could be chosen (Fig. 3D). In sequence, an approximate 1.5 mm wide graft was harvested from the flap (Figs. 2D and 3E, F).

The SCTG length, width and thickness were measured with a digital caliper. The donor site was then sutured with 4.0 silk sutures and primary closure was achieved. The graft was sutured to the recipient bed with 5.0 absorbable sutures (Fig. 1C), and the flap was coronally advanced, covering the SCTG and the gingival recession, and was sutured with 5.0 nylon sutures (Fig. 1D).

All patients were instructed to avoid trauma and discontinue toothbrushing at the surgical site for a 15-day period. A 0.12% chlorhexidine digluconate solution rinse

(1 min rinse, twice a day, for 15 days) for cleaning and a non-steroidal antiinflammatory agent (nimesulide 100 mg, twice a day, for 3 days) for control of postoperative pain were prescribed. The palatal sutures were removed 7 days postoperatively (Fig. 3G).

Data Analysis

A descriptive statistical analysis was carried out made for SCTG length, width and thickness, and the parameters were expressed as means and standard deviation.

Results

The data of the 50 surgeries showed that the dimensions of SCTG varied according to the amount of graft required. SCTG length varied between 22.25 mm and 8 mm (14.33 ± 3.58 mm). SCTG width was between 13.37 mm and 6.88 mm (9.52 ± 1.50 mm). The SCTG thickness varied between 1.8 mm and 1 mm (1.52 ± 0.24 mm). Palatal healing occurred uneventfully for all patients. After 3 months good root coverage was obtained with favorable esthetic results (Fig. 3E).

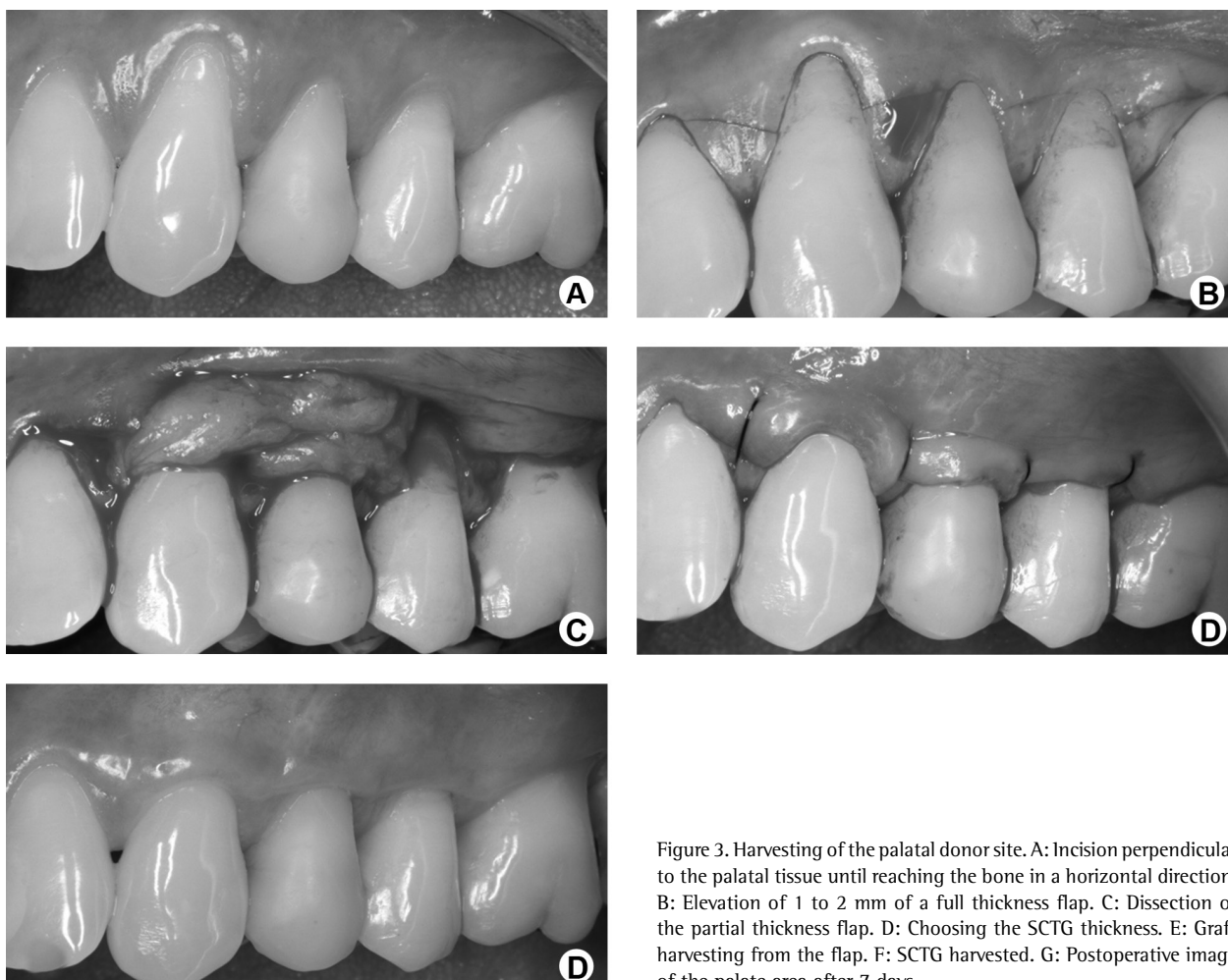


Figure 3. Harvesting of the palatal donor site. A: Incision perpendicular to the palatal tissue until reaching the bone in a horizontal direction. B: Elevation of 1 to 2 mm of a full thickness flap. C: Dissection of the partial thickness flap. D: Choosing the SCTG thickness. E: Graft harvesting from the flap. F: SCTG harvested. G: Postoperative image of the palate area after 7 days.

Discussion

Connective tissue is widely used in periodontal plastic surgery. Some techniques (7-10) proposed to obtain this tissue impair donor site healing or increase morbidity. The single incision technique (12) improves the healing of the palatal harvesting donor site, but it makes more difficult the primary closure of the flap. In order to overcome this problem, Lorenzana (13) proposed a modification, which is the most conservative technique for SCTG harvesting. However, this technique also has limitations: the harvested graft thickness is not predictable and removes the periosteum, a procedure that can retard the healing process.

This case series presents a modification of the single incision technique (12) for SCTG harvesting. This approach also is different from the modification proposed by Lorenzana (13), and it involves a full-partial thickness flap at the donor site, preserving most of the periosteum at the palatal site, which may be a benefit to the healing process. After SCTG harvesting, the remaining connective tissue and periosteum can act as a recipient bed for the flap, nourishing it. This approach also allows a primary closure of the wound, which can improve the donor site healing. So, this technique permits to obtain the desired SCTG with good healing and minimal discomfort to the patients.

The use of grafts with periosteum has been advocated due to a possible capacity of the periosteum to stimulate bone formation on the tooth root, promoting periodontal regeneration and improving the root coverage (13, 15,16). Nevertheless, there are no studies confirming this hypothesis. Additionally, good results on root covering are obtained with periosteum-free SCTG (10).

This new modification of the single incision technique also allows a more accurate control of the graft thickness. Although SCTG length and width has varied, due to the required size of the graft, its thickness had a small standard deviation (0.24 mm), similar to that reported by Yotnuengnit (17) (0.17 mm). This new modification of the single incision technique for connective tissue graft harvesting permits primary wound closure and control of graft thickness.

Resumo

O enxerto de tecido conjuntivo (ETC) tem sido amplamente utilizado para várias aplicações clínicas. Entretanto, o procedimento cirúrgico pode não permitir o controle da espessura do enxerto gengival. O objetivo deste relato de casos seriados é descrever uma nova técnica cirúrgica que modifica a técnica de incisão única para remoção de enxerto gengival, permitindo o controle da espessura do ETC sem aumentar o desconforto do paciente. Cinquenta casos foram realizados em trinta pacientes sistemicamente e periodontalmente saudáveis, que apresentavam pelo menos uma retração gengival múltipla, a qual foi tratada pela técnica de retalho avançado coronalmente combinada com ETC. O palato serviu como área doadora, uma incisão perpendicular foi realizada para criar um retalho total. Em seguida 1-2 mm do retalho foi elevado e dissecado para obter um retalho parcial. O ETC permaneceu retido no retalho total-parcial. Depois de determinar qual a espessura desejada do ETC, o

enxerto foi removido do palato. Os pacientes apresentaram cicatrização sem complicações em 7 dias, com fechamento da ferida por primeira intenção em todos os casos. A largura e comprimento do ETC variaram conforme a necessidade de cada caso clínico, mas a espessura do ETC foi bem controlada, com apenas 0,24 mm de desvio padrão. A sugestão de modificação de técnica cirúrgica para remoção de ETC permite controlar as dimensões do ETC e fechamento da ferida por primeira intenção em 7 dias.

Acknowledgments

The authors thank the Brazilian Ministry of Education's Federal Agency for Support and Evaluation of Graduate Education (CAPES) for the scholarship which supported the author Reino.

References

1. Wessel JR, Tatakis DN. Patient outcomes following subepithelial connective tissue graft and free gingival graft procedures. *J Periodontol* 2008;79:425-430.
2. Langer B, Calagna LJ. The subepithelial connective tissue graft. A new approach to the enhancement of anterior cosmetics. *Int J Periodontics Restorative Dent* 1982;2:22-33.
3. Campbell CM, Deas DE. Removal of an amalgam tattoo using a subepithelial connective tissue graft and laser deepithelialization. *J Periodontol* 2009;80:860-864.
4. Langer B, Langer L. Subepithelial connective tissue graft technique for root coverage. *J Periodontol* 1985;56:715-720.
5. Santamaria MP, Ambrosano GM, Casati MZ, Nociti Junior FH, Sallum AW, Sallum EA. Connective tissue graft plus resin-modified glass ionomer restoration for the treatment of gingival recession associated with non-carious cervical lesion: a randomized-controlled clinical trial. *J Clin Periodontol* 2009;36:791-798.
6. Kan JY, Rungcharassaeng K, Morimoto T, Lozada J. Facial gingival tissue stability after connective tissue graft with single immediate tooth replacement in the esthetic zone: consecutive case report. *J Oral Maxillofac Surg* 2009;67:40-48.
7. Edel A. Clinical evaluation of free connective tissue grafts used to increase the width of keratinised gingiva. *J Clin Periodontol* 1974;1:185-196.
8. Broome WC, Hutchinson RA, Mays EE. Histoplasmosis of the gingiva. Report of a case. *J Periodontol* 1976;47:95-97.
9. Bosco AF, Bosco JM. An alternative technique to the harvesting of a connective tissue graft from a thin palate: enhanced wound healing. *Int J Periodontics Restorative Dent* 2007;27:133-139.
10. McLeod DE, Reyes E, Branch-Mays G. Treatment of multiple areas of gingival recession using a simple harvesting technique for autogenous connective tissue graft. *J Periodontol* 2009;80:1680-1687.
11. Raetzke PB. Covering localized areas of root exposure employing the "envelope" technique. *J Periodontol* 1985;56:397-402.
12. Bruno JF. Connective tissue graft technique assuring wide root coverage. *Int J Periodontics Restorative Dent* 1994;14:126-137.
13. Lorenzana ER, Allen EP. The single-incision palatal harvest technique: a strategy for esthetics and patient comfort. *Int J Periodontics Restorative Dent* 2000;20:297-305.
14. Zucchelli G, De Sanctis M. Treatment of multiple recession-type defects in patients with esthetic demands. *J Periodontol* 2000;71:1506-1514.
15. Pasquinelli KL. The histology of new attachment utilizing a thick autogenous soft tissue graft in an area of deep recession: a case report. *Int J Periodontics Restorative Dent* 1995;15:248-257.
16. de Molon RS, de Avila ED, de Souza JA, Nogueira AV, Cirelli CC, Cirelli JA. Combination of orthodontic movement and periodontal therapy for full root coverage in a Miller class III recession: a case report with 12 years of follow-up. *Braz Dent J* 2012;23:758-763.
17. Yotnuengnit P, Promsuthi A, Teeparat T, Laohapand P, Yuwapecha W. Relative connective tissue graft size affects root coverage treatment outcome in the envelope procedure. *J Periodontol* 2004;75:886-892.

Received August 16, 2013
Accepted October 10, 2013