

Three-dimensional Digital Evaluation of Dental Arches in Infants with Cleft Lip and/or Palate

Viviane Mendes Fernandes¹, Paula Karine Jorge¹, Cleide Felício Carvalho Carrara¹, Márcia Ribeiro Gomide¹, Maria Aparecida Andrade Moreira Machado², Thais Marchini Oliveira^{1,2}

¹Department of Pediatric Dentistry, Hospital for Rehabilitation of Craniofacial Anomalies, USP - Universidade de São Paulo, Bauru, SP, Brazil
²Department of Pediatric Dentistry, Orthodontics and Public Health, Dental School of Bauru, USP - Universidade de São Paulo, Bauru, SP, Brazil

Correspondence: Thais Marchini Oliveira, Alameda Dr. Octávio Pinheiro Brisolla, 9-75, 17012-901 Bauru, SP, Brasil. Tel: +55-14-3235-8224. email: marchini@usp.br

The aim of this study was to measure and compare the dimensions of the dental arches on three-dimensional digital study models in children with and without cleft lip and palate before the primary surgery. The sample consisted of 223 digital models of children aged 3-9 months, divided into 5 groups: without craniofacial deformities, unilateral and bilateral incomplete cleft lip and alveolus, unilateral and bilateral complete cleft lip and alveolus, unilateral cleft lip and palate, and bilateral cleft lip and palate. Dental casts of the maxillary dental arches of the children were used. The dental casts underwent a process of scanning through 3D scanner and the measurements used for the correlation among groups were made on the scanned images. Statistical analysis was performed by t test and ANOVA followed by Tukey test. The results showed that the intercanine distance and anterior cleft width was wider in children with unilateral cleft lip and palate. The intertuberosity distances and posterior cleft width was wider in children with bilateral cleft lip and palate among the groups. Children with cleft lip and palate before the primary surgery had wider maxillary arch dimensions than the children without cleft lip and palate.

Key Words: dental arch, cleft lip/palate, anatomic landmarks, dental model.

Introduction

Cleft lip and palate are the most prevalent congenital alterations in the human craniofacial region (1,2). Cleft lip and palate is a facial alteration of embryologic origin due to the lack of fusion of the palatal processes, medial nasal processes and of the last with the maxillary process (laterally). The anatomic and functional alterations of the cleft lip and palate individuals show several requirements related to medical, dental and speech care (2). The fact that the professional be aware of the dimensional alterations of the dental arches occurring in cleft lip and palate subjects is of extreme therapeutic interest, because it can influence the stability of the obtained results in the rehabilitation of this subject (3).

The systematic and early documentation of the cleft lip and palate patient aiming the rehabilitation treatment of these individuals is considered a constant challenge and it should be started at birth (3). It is important to emphasize that the dental documentation enables an adequate and prospective planning, by individualizing the procedures required for each specific case and allows the longitudinal evaluation of the progress attained in the proposed treatment.

The most common way of evaluating and comparing the results of the cleft lip and palate patient rehabilitation is performed by impressions of the dental arches at pre-established ages by the treatment protocol. On the dental

plaster cast resulting from the impressions, measurements are performed and used as parameters of comparison between the patients with different cleft types. Dental plaster casts, despite their easy construction and low cost, have some disadvantages such as susceptibility to damage and loss, need of room for physical storage and occasionally transportation to a common place.

These potential challenges led the professionals to search for alternative methods to conduct these studies such as the tridimensional images of plaster cast. Different from the static photographs, the three-dimensional (3D) digital images have the advantages of rotation and manipulation similar to those of a plaster cast (4-7), excellent potential for use in the clinical evaluation of the performed treatment, for teaching and research to verify the alterations in the growth of dental arches, for comparison of the results with international treatment centers, clarification of legal claims and for surgical guidance (8-13).

The aim of this study was to measure and compare the dimensions of the dental arches on three-dimensional digital study models of children with and without cleft lip and palate before the primary surgery.

Material and Methods

The local Ethics committee approved the study protocol (Process #267/2010). The inclusion criteria were dental casts of 3-9-month-old children of both sexes with or

without cleft lip and palate. The sample was selected from the documentation files of our dental school. The exclusion criteria comprised dental casts of children with associated syndrome, with previous lip repair and incomplete documentation.

According to the documentation protocol, all children are submitted to impression and photographs at pre-established periods: before cheiloplasty – around 3 to 6 months of age; before palatoplasty – around 12 months of age; 1 year after the last primary surgery and with complete deciduous dentition. Before initiating the dental arch impressions for achievement of dental casts, the parents are informed about the need of this procedure, how it is performed and are reassured in case of pain and/or nausea. Impressions from the dental arches and photographs were made since the patients's first months of life. Before the age of 4, only impressions of the maxillary dental arch are made; impressions of the mandibular arch are only made in the complete primary dentition (14).

The sample size was calculated so that the number of selected dental casts of children met the representative rating to conduct the study. Considering a former study by Prah et al. (15) with significance level of 5%, test power of 80% and difference to be detected of 1.44, the minimum sample size was calculated to be 23 digital models per group.

The study was conducted on 223 digital models. The research participants were divided into five groups: G1 - 23 digital models of children without craniofacial deformities; G2 - 50 digital models of children with unilateral and bilateral incomplete cleft lip and alveolus; G3 - 50 digital models of children with unilateral and bilateral complete cleft lip and alveolus; G4 - 50 digital models of children with unilateral cleft lip and palate and G5 - 50 digital models of children with bilateral cleft lip and palate. The study follows the classification proposed by Spina and colleagues in 1972, modified by Silva Filho in 1992 (3).

To perform the evaluation of the measurements of the maxillary dental arches of the selected participants, study casts for each child from the documentation files of the institution were used. The digital models were constructed and digitized to measure the tooth arches (R700TM Scanner; 3Shape AS, Copenhagen, Denmark). The 3D OrthoAnalyzerTM Software (3Shape AS) enabled the following measurements to be evaluated:

- Unilateral anterior cleft width (UACW) - the measurement between the alveolar ridges at the anterior region of the cleft, for unilateral cases: points A and A';

- Left (ACW-L) and right (ACW-R) anterior cleft width - the measurement between the alveolar ridges at the anterior region of the cleft for bilateral cases: points P-A and P'-A'. The points P and P' were the most external areas of the premaxilla;

- Posterior cleft width (PCW) - at the intertuberosity area, the points were located in the boundary of the posterior cleft width: points U and U';

- Intercanine distance (ICD) - the points C and C', which correspond to the points of the primary canines, located at their site within the alveolar ridges where the canine eminence is already present within the bone plate;

- Intertuberosity distance (ITD) - the points T and T', which are the tuberosity points of the ridge.

Figures 1A-1E exhibit the measurements used in each group studied in the research.

For the analysis of intra-examiner error, paired t test was used with level of significance set at 5%. The casual error was determined by the Dahlberg's formula. The results were submitted to t test and ANOVA followed by Tukey test (Statistics for Windows - Version 7.0 - StatSoft), with level of significance set at 5%.

Results

The intra-examiner reproducibility was performed and there was no statistically significant difference among the repeat measurements (Table 1). The mean age of the children was 4.9 months. The analysis of the results obtained in the ICD and ITD showed that there was statistically significant difference among the studied groups. Table 2 shows the results obtained with the measurements in all groups of the research.

The UACW was present in groups 3 and 4. There was statistically significant difference between the means ($p=0.000$) and the UACW measurement was greater in G4.

The ACW-L and ACW-R were present in G3 and G5. There was statistically significant difference between the means of the studied groups ($p=0.011$ and $p=0.030$), and G5 showed greater measurements than G3.

The PCW measurement was used in the groups with unilateral (G4) and bilateral (G5) complete cleft lip and palate. The comparison demonstrated that there was statistically significant difference between groups, with greater measurements in G5. Table 3 exhibits the results obtained with the ACW and PCW measurements in G3, G4 and G5.

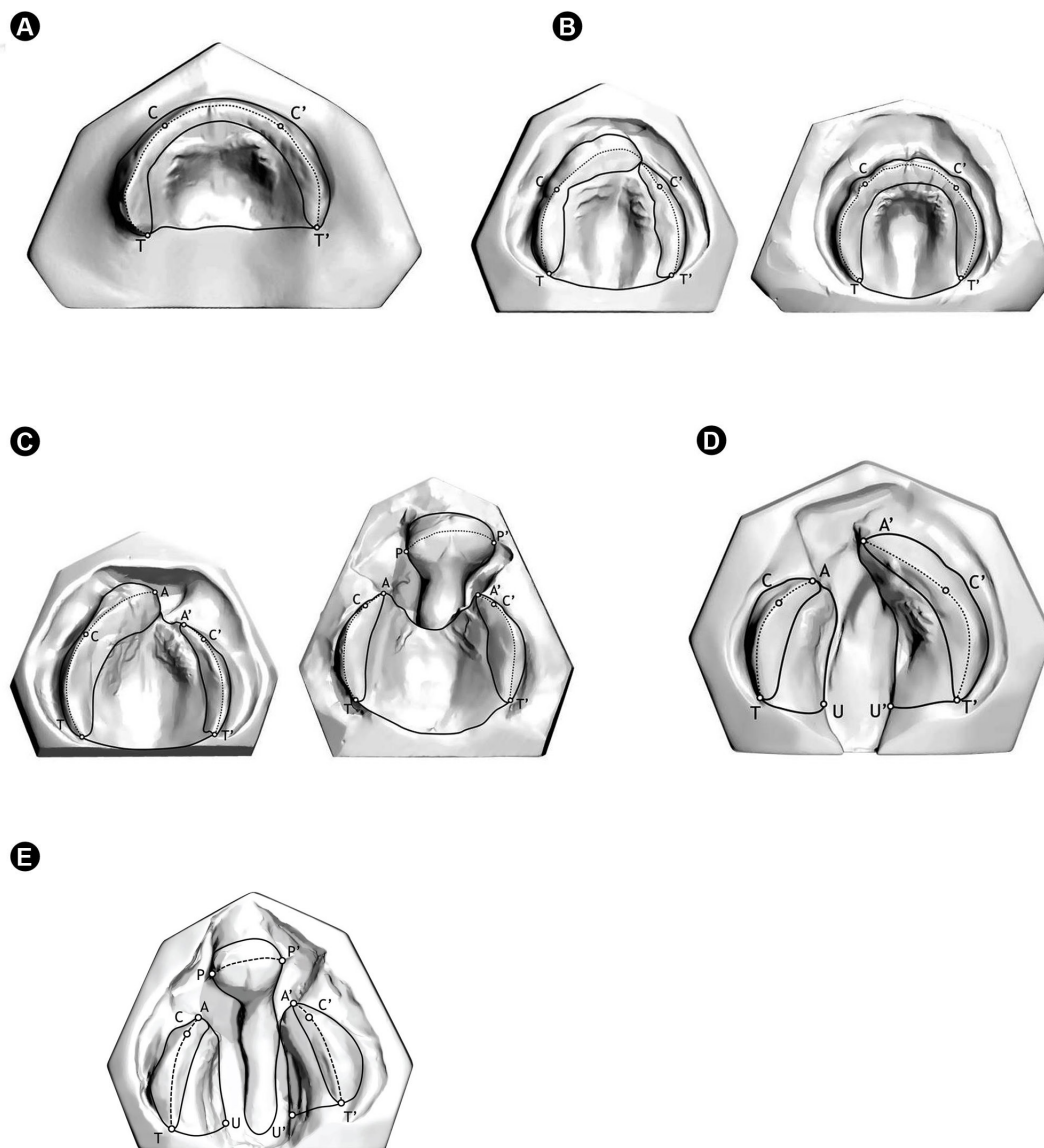
Discussion

The use of landmarks and tridimensional images for the study of dental arches is a method largely employed for several goals, such as study of growth and development of the maxilla. The landmark is the most contributing factor for the inaccuracy of the measurement and there is no standard protocol for the demarcations (16). Although this is a method largely known especially in orthodontics, in cases in which the patient presents cleft lip and palate, the demarcation of these landmarks is extremely difficult (17-

21), which could explain the small number of studies on this field, mainly in the early childhood. This study enabled the clinical documentation of children in the early childhood to evaluate the measurements of the dental arches prior to the primary surgeries. This is a fundamental aspect for the rehabilitation process because the result obtained during the treatment can demonstrate its progress at every phase. In this institution, the treatment of cleft lip and palate is initiated soon after birth and continues up to adulthood.

In the analysis of the obtained results, the ICD was wider in unilateral complete cleft lip and palate for the

studied groups. It was observed that the ICD values found in groups 1, 2 and 3 were very close among each other without statistically significant differences, probably because in cases of complete and incomplete unilateral and bilateral cleft lip (G2 and G3) there is no palate involvement. Therefore, the ICD measurements of complete cleft lip and alveolus were very close to those of the patients without cleft. However, the comparison of the ICD of G1 with the means of G4 and G5 evidenced a statistically significant difference in the measurements, corroborating the aforementioned discussion that the palate involvement



Composite figure of digital mold images. A: Digital mold of the maxillary arch of a child without cleft (Group 1). B: Digital mold of a unilateral and bilateral incomplete cleft lip and alveolus (Group 2). C: Digital mold of a bilateral and unilateral complete cleft lip and alveolus (Group 3). D: Digital mold of a unilateral complete cleft lip and palate (Group 4). E: Digital mold of a bilateral complete cleft lip and palate (Group 5).

may influence the measurement results.

Similarly, there were statistically significant differences when the results of ITD measurements were analyzed, they were greater for the bilateral complete cleft lip and palate in children. The ITD measurement means found in this study were very close to those of Lo et al. (22), who conducted their study using tridimensional molds. The authors measured the palate area, intercanine distance and intertuberosity distance of cleft lip and palate on 3 month-old children. Generally, ICD and ITD were 2 mm smaller than those of the present study. This agreement was also observed with Honda et al. (23), who studied the

maxillary arch using plaster casts, and found the following ITD means: 31.20 mm for unilateral cleft lip and alveolus; 36 mm for unilateral complete cleft lip and palate; and 36.01 mm bilateral complete cleft lip and palate. On the other hand, the present study found: 32.98 mm, 35.00 mm and 36.49 mm, respectively. On the other hand, this agreement did not occur for the ICD means, which in the study of Honda et al. (23) were 30.8 mm for unilateral cleft lip and alveolus; 34.3 mm for unilateral complete cleft lip and palate; and 32.7 mm for bilateral complete cleft lip and palate. In this study, the means were 26.49 mm, 28.31 mm and 27.44 mm, respectively.

A part of the sample from the study of Huang et al., (24) was composed by 3-month-old children with unilateral complete cleft lip and palate. The comparison with the findings of Huang et al. (24) demonstrates that the ACW means were similar to the ones of this study. The children had worn a passive orthodontic appliance previous to the cheiloplasty surgery to aid in the milk ingestion, which could explain the difference found among the mean values. Another hypothesis could be the different methods adopted, because the authors employed a caliper to obtain the measurements. In this study, regarding the results for ACW was observed a statistically significant difference in the comparison among groups G3, G4 and G5. Harila et al. (25) measured the dimensions of the maxillary arches and the cleft width of children in early childhood, using a digital caliper and the following measurements: ACW, ICD and ITD.

The difference verified in the comparison between the two studies is probably explained by the different methods employed in the measurement, as well as in the impression materials, because Harila et al. (25) employed alginate.

In the present study, in the case of PCW measured in groups G4 and G5, statistically significant differences were found in the group means. This

fact can be related to the severity of the amplitude of unilateral and bilateral complete cleft lip and palate. The bilateral complete cleft lip and palate in some cases exhibits a wider dimension at the anterior region of the palate, which can extend to the posterior region. Notwithstanding, it is possible to observe in some cases of this study that the PCW of the bilateral complete cleft lip and palate was smaller than that of the unilateral complete cleft lip and palate. These findings corroborate the findings of Harila et al., (25) when they affirmed that at birth, inside the same group, there is a great variability in the lack of tissue

Table 1. Result of the dependent t test and Dahlberg's test applied to the variables, to evaluate the inter-examiner agreement

Variables	1st Measurement	2nd Measurement	p	Dahlberg
ICD*	26.89	26.82	0.126	0.28
ITD**	33.26	33.19	0.179	0.31
uniACW***	11.40	11.40	0.969	0.20
ACW-L****	9.38	9.30	0.423	0.34
ACW-R*****	8.20	8.15	0.439	0.24
PCW*****	12.36	12.47	0.440	0.15

* Intercanine distance; ** Intertuberosity distance; *** Unilateral anterior cleft width; **** Left anterior cleft width; ***** Right anterior cleft width; ***** Posterior cleft width.

V.M. Fernandes et al.

Table 2. Means and standard deviation of intercanine distance (ICD) and intertuberosity distance (ITD) for the five groups

Variable	G1	G2	G3	G4	G5	p
ICD*	24.73 (2.16) ^A	25.21 (1.47) ^A	26.49 (1.95) ^{AC}	28.31 (3.57) ^B	27.44 (3.59) ^{BC}	0.0000****
ITD**	31.10 (2.90) ^A	31.52 (3.11) ^A	32.98 (3.02) ^A	35.00 (3.24) ^B	36.49 (2.98) ^B	0.0000****

* Intercanine distance. ** Intertuberosity distance. *** Statistically significant difference $p < 0.05$ (ANOVA and Tukey's test). Groups with different letters mean statistically significant differences among each other (rows).

Table 3. Means and standard deviation of anterior cleft width (ACW) and posterior cleft width (PCW) for the five groups

Variable	G3 Mean (SD)	G4 Mean (SD)	G5 Mean (SD)	p
UACW*	9.61 (3,68)	12.73 (3.95)	-	0.000*****
ACW-L**	6.76 (4,53)	-	10.19 (4.10)	0.011*****
ACW-R***	5.93 (3,90)	-	9.52 (5.41)	0.030*****
PCW****	-	12.39 (3.29)	14.17 (3.53)	0.013*****

* Unilateral anterior cleft width. ** Left anterior cleft width. *** Right anterior cleft width. **** Posterior cleft width. ***** Statistically significant difference $p < 0.05$ (independent t test).

and cleft width. The cleft width is closely linked to the prognosis of the child's treatment because it may affect the surgical repair and consequently the outcome to be reached. Therefore, the cleft severity is generally evaluated by its width. The larger the cleft, the greater the chance of generating a higher number of scars which may affect the maxillary growth (25,26).

The measurements and assessments of the cleft width and the dimensions of the maxillary dental arches play an important role in the determination of the most adequate treatment plan suitable for each severity and type of cleft lip and palate. Some authors advocate that there is need for more multicenter studies to reduce the variety of treatment modalities (27). In the long term, the documentation protocol enables the evaluation of both the changes and growth of the dental arches, which consequently leads to further studies favoring the treatment of cleft lip and palate subjects (28,29). This documentation may help in further researches and longitudinal studies in which, among other aspects, could be followed-up the maxillary growth, the rehabilitation process of the cleft lip and palate, and the best outcomes of the treatments performed.

This study shows that before the primary surgery the children with cleft lip and palate had wider maxillary arch dimensions than the children without cleft lip and palate

Acknowledgements

The authors would like to acknowledge the financial support of the São Paulo Research Foundation (FAPESP grants #2010/13724-9 and #2010/00868-2 at TMO) and all the patients and families who helped us carry out this study.

Resumo

O propósito deste trabalho foi mensurar e comparar as dimensões dos arcos dentários em modelos digitais tridimensionais de crianças com ou sem fissuras de lábio e palato antes das cirurgias primárias. A amostra foi composta de 223 modelos de gesso de crianças, de 3 a 9 meses, divididas em 5 grupos: sem deformidades craniofaciais, fissura pré-forame incompleta, fissura pré-forame completa, fissura transforame unilateral e fissura transforame bilateral. Modelos de gesso dos arcos dentários superiores das crianças foram utilizados para avaliação. Os modelos passaram por um processo de digitalização, por meio de escâner 3D e as medidas utilizadas para a correlação entre os grupos foram realizadas diretamente nas imagens escaneadas. A análise estatística foi realizada por meio do teste t e ANOVA seguido pelo teste de Tukey. Os resultados mostraram que a distância intercaninos e a amplitude anterior da fissura foram maiores nas crianças com fissura transforame unilateral. A distância intertuberosidades e a amplitude posterior da fissura foi maior nas com fissura transforame bilateral entre os grupos estudados. As crianças com fissura de lábio e palato apresentam as dimensões dos arcos maxilares maiores que as crianças sem fissura labiopalatina antes das cirurgias primárias.

References

- World Health Organization. Global strategies to reduce the health-care burden of craniofacial anomalies. Geneva: WHO; 2002.
- Farronato G, Cannalire P, Martinelli G, Tubertini I, Giannini L, Galbiati G, et al.. Cleft lip and/or palate: review. *Minerva Stomatol* 2014;63:111-126.
- Freitas JA, das Neves LT, de Almeida AL, Lauris R de C, Almeida AL, Neves LT, et al.. Rehabilitative treatment of cleft lip and palate: experience of the Hospital for Rehabilitation of Craniofacial Anomalies/USP (HRAC/USP) - Part 1: overall aspects. *J Appl Oral Sci* 2012;20:9-15.
- Zilberman O, Huggare JA, Parikakis KA. Evaluation of the validity of tooth size and arch width measurements using conventional and three-dimensional virtual orthodontic models. *Angle Orthod* 2003;73:301-306.
- Goonewardene RW, Goonewardene MS, Razza JM, Murray K. Accuracy and validity of space analysis and irregularity index measurements using digital models. *Aust Orthod J* 2008;24:83-90.
- Leifert MF, Leifert MM, Efstratiadis SS, Cangialosi TJ. Comparison of space analysis evaluations with digital models and plaster dental casts. *Am J Orthod Dentofacial Orthop* 2009;136:16.e1-e4.
- Boonvong K, Liu Z, McGrath C, Hägg U, Wong RWK, Bendeus M, et al.. Virtual model analysis as an alternative approach to plaster model analysis: reliability and validity. *Eur J Orthod* 2010;32:589-595.
- Kusnoto B, Evans CA. Reliability of a 3D surface laser scanner for orthodontic applications. *Am J Orthod Dentofacial Orthop* 2002;122:342-348.
- Asquith JA, Gillgrass T, Mossey P. Three-dimensional imaging of orthodontic models: a pilot study. *Eur J Orthod* 2007;29:517-522.
- Russell K, Long RE Jr, Hathaway R, Daskalogiannakis J, Mercado A, Cohen M, et al.. The Americleft study: an inter-center study of treatment outcomes for patients with unilateral cleft lip and palate part 2. Dental arch relationships. *Cleft Palate Craniofac J* 2011;48:244-251.
- Rheude B, Sadowsky PL, Ferriera A, Jacobson A. An evaluation of the use of digital study models in orthodontic diagnosis and treatment planning. *Angle Orthod* 2005;75:300-304.
- Nollet PJPM, Katsaros C, Van't Hof MA, Bongaarts CAM, Semb G, Shaw WC, et al.. Photographs of study casts: an alternative medium for rating dental arch relationships in unilateral cleft lip and palate. *Cleft Palate Craniofac J* 2004;41:646-650.
- Ahmad I. Digital dental photography. Part 2: Purposes and uses. *Br Dent J* 2009;206:459-464.
- Freitas JA, Garib DG, Oliveira M, Lauris R de C, Almeida AL, Neves LT, et al.. Rehabilitative treatment of cleft lip and palate: experience of the Hospital for Rehabilitation of Craniofacial Anomalies-USP (HRAC-USP) - part 2: pediatric dentistry and orthodontics. *J Appl Oral Sci* 2012;20:268-281.
- Prahl C, Kuijpers-Jagtman AM, Van't Hof MA, Prahl-Andersen B. A randomised prospective clinical trial into the effect of infant orthopaedics on maxillary arch dimensions in unilateral cleft lip and palate (Dutchcleft). *Eur J Oral Sci* 2001;109:297-305.
- Seckel NG, van der Tweel I, Elema GA, Specken TF. Landmark positioning on maxilla of cleft lip and palate infant - a reality? *Cleft Palate Craniofac J* 1995;32:434-441.
- Spauwen PH, Hardjowasito W, Boersma J, Latief BS. Dental cast study of adult patients with untreated unilateral cleft lip or cleft lip and palate in Indonesia compared with surgically treated patients in the Netherlands. *Cleft Palate Craniofac J* 1993;30:313-319.
- Suzuki A, Mukai Y, Ahishi M, Miyanoshta Y, Tashiro H. Relationship between cleft severity and dentocraniofacial morphology in Japanese subjects with isolated cleft palate and complete unilateral cleft lip and palate. *Cleft Palate Craniofac J* 1993;30:175-181.
- Thilander B. Dentoalveolar development in subjects with normal occlusion. A longitudinal study between the ages of 5 and 31 years. *Eur J Orthod* 2009;31:109-120.
- Ye B, Ruan C, Hu J, Yang Y, Ghosh A, Jana S, et al.. A comparative study on dental-arch morphology in adult unoperated and operated cleft palate patients. *J Craniofac Surg* 2010;21:811-815.
- Mazaheri M, Athanasiou AE, Long RE Jr, Kolokitha OG. Evaluation of maxillary dental arch form in unilateral clefts of lip, alveolus, and palate from one month to four years. *Cleft Palate Craniofac J* 1993;30:90-93.

22. Lo LJ, Wong FH, Chen YR, Lin WY, Ko EW. Palatal surface area measurement: comparisons among different cleft types. *Ann Plast Surg* 2003;50:18-23.
23. Honda Y, Suzuki A, Ohishi M, Tashiro H. Longitudinal study on the changes of maxillary arch dimensions in Japanese children with cleft lip and/or palate: infancy to 4 years of age. *Cleft Palate Craniofac J* 1995;32:149-155.
24. Huang C-S, Wang W-I, Liou EJ-W, Chen Y-R, Chen PK-T, Noordhoff MS. Effects of cheiloplasty on maxillary dental arch development in infants with unilateral complete cleft lip and palate. *Cleft Palate Craniofac J* 2002;39:513-516.
25. Harila V, Ylikontiola LP, Palola R, Sándor GK. Maxillary arch dimensions in cleft infants in Northern Finland. *Acta Odontol Scand* 2013;71:930-936.
26. Reiser E, Skoog V, Andlin-Sobocki A. Early dimensional changes in maxillary cleft size and arch dimensions of children with cleft lip and palate and cleft palate. *Cleft Palate Craniofac J* 2013;50:481-490.
27. Ladeira PR, Alonso N. Protocols in cleft lip and palate treatment: systematic review. *Plast Surg Int* 2012;2012:562892.
28. Mello BZ, Fernandes VM, Carrara CF, Machado MA, Garib DG, Oliveira TM. Evaluation of the intercanine distance in newborns with cleft lip and palate using 3D digital casts. *J Appl Oral Sci* 2013;21:437-442.
29. Heibuchel KLM, Kuijpers-Jagtman AM. Maxillary and mandibular dental-arch dimensions and occlusion in bilateral cleft lip and palate patients from 3 to 17 years of age. *Cleft Palate Craniofac J* 1997;34:21-26.

Received July 11, 2014
Accepted March 10, 2015