

## Dopplervelocimetric evaluation of portal vein as a diagnostic tool for portosystemic shunt diagnosis in dogs

### Avaliação dopplervelocimétrica da veia porta como ferramenta diagnóstica de shunt portossistêmico em cães

Cibele Figueira Carvalho<sup>I</sup> Giovanni Guido Cerri<sup>II</sup> Maria Cristina Chammas<sup>III</sup>

#### ABSTRACT

*The objective of this research was to verify if the study of portal hemodynamic parameters through duplex Doppler ultrasonography (DUS) is able to help to detect portosystemic shunt (PSS) and the shunted vessel origin. It was detected PSS in 20 dogs by abdominal DUS and confirmed at surgery or necropsy from March of 2004 until March 2007. Main ultrasonographic findings were: identification of a tortuous vessel shunting portal flow being: portocaval shunt (16/20 or 80%), esplenocaval shunt (2/20 or 10%), gastrocaval shunt (1/20 or 5%), portoazigo shunt (1/20 or 5%); 2) elevated portal flow velocity before shunt (17/20 or 81%), 3) lower portal flow velocity after shunt (17/20 or 81%), 4) turbulence in the caudal vena cava (10/20 or 47,5%) and 5) reduced liver size (15/20 or 71%). The others ultrasonographic findings associated with clinical records were similar to that described in literature. With this work we could conclude that hemodynamic assessment of portal vein with DUS may be a useful tool for PSS diagnosis and to detect the shunted vessel origin.*

**Key words:** ultrasonography, Doppler, portosystemic shunt, dog.

#### RESUMO

*O objetivo desta pesquisa foi verificar se o estudo dos parâmetros hemodinâmicos, por meio da ultrassonografia duplex Doppler (USD), é capaz de auxiliar na detecção do desvio portossistêmico (DPS) e na origem do vaso desviado. Por meio da USD abdominal, foram detectados, no período de março de 2004 a março de 2007, casos de DPS em 20 cães, os quais foram confirmados pela cirurgia ou necropsia. Os principais achados ultrassonográficos foram: 1) identificação de um vaso tortuoso, desviando o fluxo portal, sendo: desvio portocaval (16/20 ou 80%), desvio esplenocaval (2/20 ou 10%), desvio gastrocaval (1/20 ou 5%), desvio portoázigos (1/20 ou*

*5%); 2) velocidade de fluxo portal elevada antes do desvio (17/20 ou 81%); 3) velocidade de fluxo portal diminuída após o desvio (17/20 ou 81%); 4) fluxo turbulento na veia cava caudal (10/20 ou 47,5%); e 5) fígado de tamanho diminuído (15/20 ou 71%). Os outros achados ultrassonográficos associados com dados clínicos foram semelhantes aos descritos na literatura. Com este trabalho, pode-se concluir que a avaliação hemodinâmica da veia portal com USD pode ser uma ferramenta diagnóstica útil na detecção do DPS e na origem do vaso desviado.*

**Palavras-chave:** ultrassonografia, Doppler, desvio portossistêmico, cão.

#### INTRODUCTION

Portosystemic shunts (PSS) are single or multiple abnormal vascular communications that connect blood from stomach, pancreas, spleen and intestines to systemic circulation without passing through the liver. It can be found in all mammals but affects more frequently dogs (D'ANJOU et al., 2004).

PSS in dogs can be either congenital or acquired. Acquired PSSs develop secondary to portal hypertension and are associated with diseases as cirrhosis, chronic cholangiohepatitis, hepatic neoplasia and arteriovenous fistulas. Portal hypertension may result in the formation of multiple extrahepatic shunts, with were previously nonfunctional remnant vessels of the portal system (FERREL et al., 2003). Congenital form is more commonly recognized (LAMB, 1998).

<sup>I</sup>Instituto de Radiologia (INRAD), Hospital das Clínicas da Faculdade de Medicina da Universidade de São Paulo (HCFMUSP), 05403-001, São Paulo, SP, Brasil. E-mail: cibelegcarvalho@terra.com.br. Autor para correspondência.

<sup>II</sup>Faculdade de Medicina, Universidade de São Paulo (USP), São Paulo, SP, Brasil.

<sup>III</sup>Serviço de Ultrassonografia, INRAD, HCFMUSP, São Paulo, SP, Brasil.

Congenital PSSs are anomalous embryonal vessels that usually occur as single shunts (either intra or extra hepatic). The genetic basis for PSSs is unknown, although affected lines have been recognized in miniature Schnauzers, Irish Wolfhound, Old English Sheepdog and Cairn Terriers (FAVERZANI et al., 2003). An autosomal polygenic mechanism is suspected in Irish Wolfhounds (HERDEN et al., 2003). Acquired PSSs, with form is related with portal hypertension symptoms, are multiple extra hepatic shunts that connect the portal system and the caudal vena cava (FERREL et al., 2003). Single intrahepatic PSS provide a communication between portal vein and caudal vena cava (LAMB & WHITE, 1998). They can be classified as left, central and right divisional. The morphology of the left divisional shunt is consistent with failure to close of the fetal ductus venosus. The mechanisms associated to this failure are unknown. The pathogenesis of intrahepatic PSSs that occur in the right medial or lateral liver lobes is also unknown. Single intrahepatic PSSs are most common in large breed dogs (HUNT et al., 2000).

Extrahepatic PSSs usually connect the portal vein or one of this tributaries (left gastric or splenic vein) with the caudal vena cava cranial to the phrenicoabdominal veins. The anomalous vessel can eventually enter the azigos vein or other systemic vessel. Single extrahepatic PSSs are most common in cats and small breed dogs (HUNT et al., 2000).

Congenital PSS occur more frequently in purebred dogs. Breeds at increased risk are miniature Schnauzer, Yorkshire terrier, Irish wolfhound, Cairn terrier, Maltese, Golden Retriever, Old English Sheepdog and Labrador (BREZNOCK & WHITING, 1995). It can be found either in Shih Tzu and Poodle (HUNT et al., 2000). Literature still suggests that there is a slight sexual predilection for female dogs (HOLT et al., 1995). Age is a important diagnostic clue because most animals develop signs by six months of age (FERREL et al., 2003; TISDALL et al., 2000).

Clinical signs of congenital PSS can indicate that central nervous system, gastrointestinal system or urinary tract involved (SCHERMERHORN et al., 1996). This disease leads to hepatic atrophy and clinical signs related to the bypass of toxins such as ammonia, resulting in hepatic encephalopathy signs and nephropathy sometimes (FAVERZANI et al., 2003). It must be considered as differential diagnosis microvascular hepatic dysplasia (SCAVELLI et al., 1986); infectious diseases (WRIGLEY et al., 1987); hydrocephaly, idiopathic epilepsy and metabolic diseases as hypoglycemia and thiamine deficiency (D'ANJOU et al., 2004). In dogs and cats with

congenital PSS, the liver is usually small. Biopsy findings are indistinguishable from those in hepatic microvascular dysplasia (SCAVELLI et al., 1986).

Color Doppler ultrasound is a useful noninvasive diagnostic tool for evaluate animal with suspicious congenital PSS. Intrahepatic PSS are easier to detect than extrahepatic (LAMB & WHITE, 1998). Liver usually appears small (microhepatica) at the B mode ultrasonography; there is a consistent decrease in number and size of intrahepatic veins (LAMB & WHITE, 1998). Color Doppler mapping can help to identify the presence of an anomalous and tortuous vessel, usually near left kidney or spleen following to caudal vena cava. At the site of communication often it could be seen a turbulence flow (SZATMÁRI et al., 2004). The shunting vessel usually is origin at main portal vein, splenic or gastric vein (BREZNOCK & WHITING, 1995). Pulsed Doppler can reveal increased hepatic vascular impedance with increased velocity of blood flow at portal vein in 70% of affected dogs (LAMB, 1996).

Normal mean portal blood flow velocity was determined as  $18.1 \pm 7.6 \text{ cm s}^{-1}$  in the literature (KANTROWITZ et al., 1989; NYLAND & FISHER, 1990). Hemodynamic evaluation of portal vein at the sites before and after shunting vessel has not been previously reported in veterinary literature. The mean of this research was evaluating hemodynamic behavior of portal vein in dogs with PSS and verify the utility of duplex Doppler ultrasound to detect the shunting vessel origin at PSS cases.

## METHODS

Twenty dogs of several breeds have been selected, body weight and ages, whose PSS diagnosis were detected by DUS and confirmed at surgery or necropsy from March 2004 to March 2007. Owner consent was obtained before all procedures. A pulsed duplex Doppler ultrasound was used (GE®, Logiq 3 model) with convex multi frequentials scanners, 3,0 to 5,0MHz, and 4,0 to 6,0MHz and still a linear scanner with 7 to 10MHz.

Dogs were fasted for 6 hours before exam. All dogs had their abdominal area clipped, including right lateral side since 10<sup>th</sup> intercostal space, and acoustic gel was applied to the skin. Dogs were positioned in dorsal recumbency and ultrasound was performed at this sequence: B-mode, color and pulsed Doppler.

All abdominal organs were scanned by longitudinal, transverse and coronal sonographic planes. Epigastric area was scanned by color mapping

to evaluate vascular architecture. It was observed aorta, cranial mesenteric, celiac, gastric and splenic arteries; caudal vena cava, main portal and hepatic veins were also examined. Hepatic artery was observed when possible. It was performed a detailed research to find an anomalous tortuous vessel shunting portal blood circulation intra and/or extra hepatic. After color mapping, the cursor of pulsed Doppler was positioned at the center of vessel lumen to be analyzed, with special attention to the angle of insonation. This angle was maintained at 60° or less during the study of each vessel, and as parallel as possible to blood flow to measure velocities. It was gotten spectral Doppler of cranial mesenteric and aorta arteries, one hepatic vein and main portal vein at two distinct sites (before and after shunt), caudal vena cava and hepatic artery when was possible. Maximal systolic and final diastolic velocities of each mentioned artery were measured. Maximal systolic velocity were measured of each vein. The data were recorded, and calculated means and percentages. Velocities results were submitted to paired *t* test with confidence interval of 95% or statistical significance defined as  $P < 0.05$ .

## RESULTS AND DISCUSSION

All data was presented in table 1. From the twenty dogs examined with PSS, the following breed

distribution were obtained: Yorkshire (5/20 or 25%), Shih Tzu (4/20 or 20%), Lhasa Apso (2/20 or 10%), mixed breed (2/20 or 10%), and Maltese, Spitz, Poodle, Border collie, Miniature Schnauzer, Cairn terrier, Rottweiler (1/20 or 5% each one). These distribution seems similar that described in the literature (FAVERZANI et al., 2003; HUNT et al., 2000; BREZNOCK & WHITING, 1995). The mean age was 17 months indicate that this disease often appears in young dogs as cited elsewhere (FERREL et al., 2003; TISDALL et al., 2000). It has not observed sexual predilection.

According data recorded (Table 1) it was observed that 80% of the selected dogs with PSS presented portocaval shunt (Figure 1). Splenocaval shunt (Figure 2) was the second more common accounting 10%, while gastrocaval and portoazigos shunts were found in 5% each. These data confirm the findings related at veterinary literature that shows portocaval as the most frequent PSS in dogs (D'ANJOU et al., 2004; LAMB & WHITE, 1998; HUNT et al., 2000).

In 15% (3/20) of dogs was not possible to obtain two different measures at two sites of main portal vein. And one of them has elevated blood flow velocity at main portal vein. The others dogs (17/20) or 85% presented elevated blood flow velocity at main portal vein before the shunting vessel origin when comparing at the site after the shunting vessel origin (Figure 2). It

Table 1 - Distribution of the frequency of breed, age and sex of the examined dogs; also showing the origin of the shunting vessel and blood flow velocities of main portal vein (PV) before and after the identified shunting vessel. MSV: maximal systolic velocity.

Breed	Age (months)	sex	shunt	MSV of PV before shunt (cm s <sup>-1</sup> )	MSV of PV after shunt (cm s <sup>-1</sup> )
Rottweiler	05	Male	Portoazigos	36.60	20.95
Lhasa apso	10	Female	Splenocaval	----	16.17
Shih tzu	24	Male	Splenocaval	----	12.40
Shih tzu	14	Female	Gastrocaval	19.10	6.74
Mixed breed	19	Male	Portocaval	25.93	16
Mixed breed	06	Female	Portocaval	43.66	23.40
Shih tzu	06	Male	Portocaval	31.12	----
Shih tzu	09	Male	Portocaval	25	11.07
Yorkshire	20	Female	Portocaval	26	20.10
Yorkshire	26	Female	Portocaval	25.40	9.36
Yorkshire	12	Female	Portocaval	21	7
Yorkshire	02	Female	Portocaval	13.80	7.30
Yorkshire	09	Female	Portocaval	63.61	11
Spitz	50	Male	Portocaval	25.5	7.3
Poodle	18	Male	Portocaval	17.08	7.89
Border Collie	15	Male	Portocaval	32	27.35
Schnauzer	60	Male	Portocaval	14	10
Lhasa apso	10	Male	Portocaval	25.82	11.06
Maltês	06	Female	Portocaval	25.25	11.09
Cairn terrier	18	Female	Portocaval	20	9

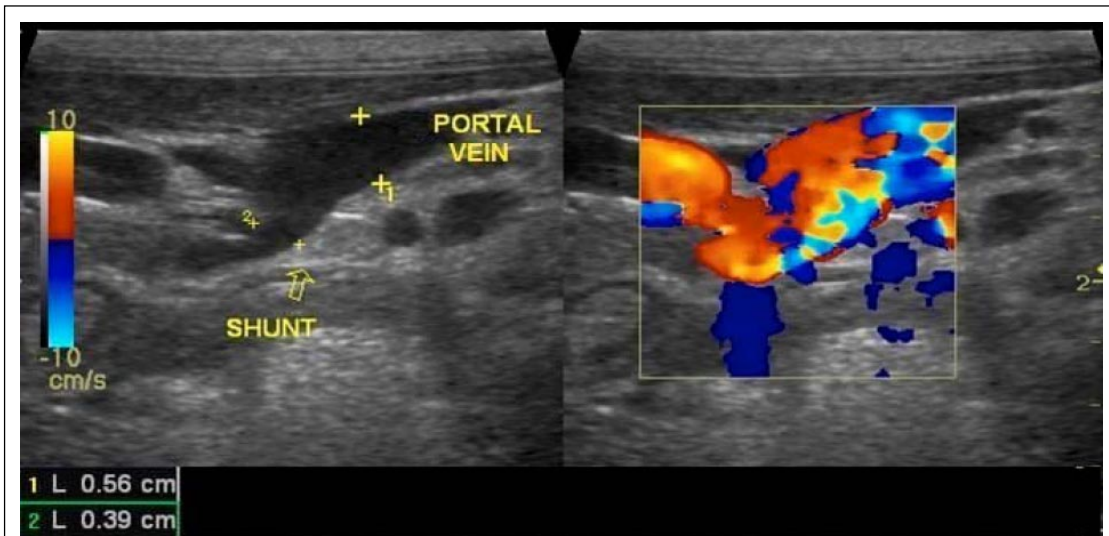


Figure 1 - Color Doppler ultrasonography showing shunting vessel with turbulent blood flow between portal vein and caudal vena cava.

was found a statistical difference ( $P > 0.05$ ) between these velocities before and after shunt.

It was found in 60% (12/20) of dogs an elevated main portal vein velocity with maximal systolic velocity upper normal limits established in literature (KANTROWITZ et al., 1989; NYLAND & FISHER, 1990). Another research done before (LAMB, C.R.,1996)

have found that 70% of affected dogs presented elevated portal vein velocity. These increased velocities are results of the associated hemodynamic disturbances depending on the location of the shunt as reported in the literature (SZATMÁRI et al., 2004).

Those dogs with normal values of blood flow velocity at main portal vein before shunt presented

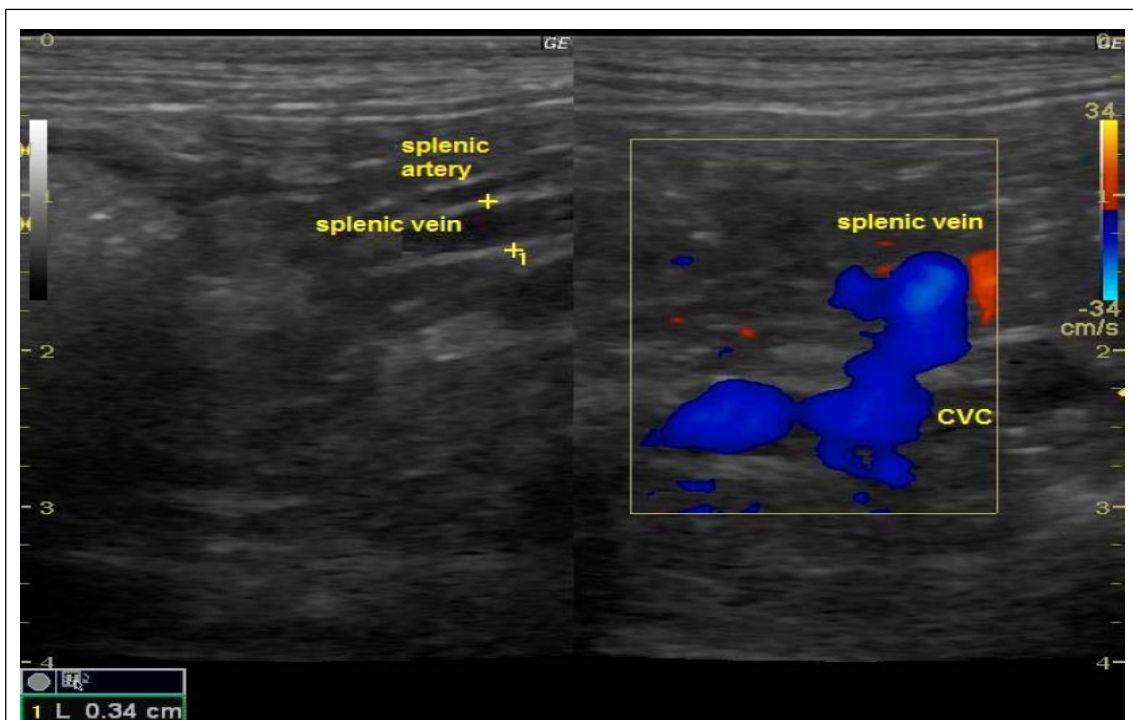

Figure 2 - Color Doppler ultrasonography showing shunting vessel between splenic vein and caudal vena cava.

lower values at the site after shunt. This lower flow was the result of the blood dividing, with some blood flowed via the shunt toward systemic circulation and some to the portal vein. Because the dual hepatic blood supply, where in approximately 75% of hepatic flow arrives via the portal vein, deviation of flow determines disturbances in hemodynamic equilibrium. Duplex Doppler ultrasonography can detect pathological blood flow. The hemodynamic behavior of portal vein in dogs with PSS demonstrates differences between velocities obtained before and after the site at shunting vessel origin. And the difference between these velocities also were statistical significant. These data suggests that this difference between velocities could help to identify the PSS and to find the anomalous vessel shunting origin.

## CONCLUSIONS

The hemodynamic study of portal vein using duplex Doppler ultrasound can be a useful tool to the PSS diagnosis. Differences between velocities in portal vein could help to identify the PSS and to find the anomalous vessel shunting origin. The results of this work show a national statistical data. That could help clinicians to think about that PSS diagnosis could be made using the tools that we have.

## REFERENCES

- BREZNOCK,E.M.; WHITING,P.G. Portocaval shunts and anomalies. In: SLATTER,D.H. **Textbook of Small Animal Surgery**. Philadelphia: Saunders, 1995. p.1156.
- D'ANJOU,M.A. et al. Ultrasonographic diagnosis of portosystemic shunting in dogs and cats. **Vet Radiol and Ultras**, v.45, n.5, p.424-37, 2004. Disponível em: <<http://www3.interscience.wiley.com/journal/118799598/abstract?CRETRY=1&SRETRY=0>>. Doi: 10.1111/j.1740-8261.2004.04076.
- FAVERZANIS,S. et al. Clinical, laboratory, ultrasonographic and histopathological findings in dogs affected by portosystemic shunts, following surgery or medical treatment. **Vet Res Comm**, v.27, n.1, p.755-58,2003. Disponível em: <<http://www.ingentaconnect.com/content/klu/verc/2003/00000027/A00100s1/05267360>>. Doi: 10.1023/B:VERC.0000014264.78105.78.
- FERREL,E.R. et al. Simultaneous congenital and acquired extrahepatic portosystemic shunts in two dogs. **Vet Radiol and Ultras**, v.44, n.1, p.38-42, 2003. Disponível em: <<http://www3.interscience.wiley.com/journal/118892990/abstract>>. Doi: 10.1111/j.1740-8261.2003.tb01446.
- HERDEN,C. et al. Unusual manifestation of hepatic encephalopathy in two Irish Wolfhound siblings. **Vet Rec**, n.29, p.682-86, 2003.
- HOLT,D.E. et al. Correlation of ultrasonographic findings with surgical, portographic, and necropsy findings in dogs and cats with portosystemic shunts: 63 cases (1987-1993). **J Am Vet Med Assoc**, v.207, p.1190-93, 1995.
- HUNT,G.B. et al. Congenital portosystemic shunts in toy and miniature poodles. **Austr Vet J**, v.78, n.8, p.530-32, 2000. Disponível em: <<http://www3.interscience.wiley.com/journal/120739343/abstract>>. Doi: 10.1111/j.1751-0813.2000.tb11894.
- KANTROWITZ,B.M. et al. Estimation of portal flow using duplex real-time and pulsed Doppler ultrasound imaging in the dog. **Vet Radiol and Ultras**, v.30, p.222-26, 1989. Disponível em: <<http://www3.interscience.wiley.com/journal/119446585/abstract>>. Doi: 10.1111/j.1740-8261.1989.tb00777.
- LAMB,C.R. Ultrasonographic diagnosis of congenital portosystemic shunts in dogs – results of a prospective study. **Vet Radiol and Ultras**, v.37, p.281-88, 1996. Disponível em: <<http://www3.interscience.wiley.com/journal/119223855/abstract>>. Ddoi: 10.1111/j.1740-8261.1996.tb01231.
- LAMB,C.R. Ultrasonography of portosystemic shunts in dogs and cats **Vet Clin North Am: Small Animm Pract**, v.28, p.725-53, 1998.
- LAMB,C.R.; WHITE,R.N. Morphology of congenital intrahepatic portocaval shunts in dogs and cats **Vet Rec**, v.142, p.55-60, 1998.
- NYLAND,T.G.; FISHER,P.E. Evaluation of experimentally induced canine hepatic cirrhosis using duplex Doppler ultrasound. **Vet Radiol and Ultras**, v.31, n.4, p189-194, 1990. Disponível em: <<http://www3.interscience.wiley.com/journal/119382436/abstract>>. Doi: 10.1111/j.1740-8261.1990.tb01809.
- SCAVELLI,T.D. et al. Portosystemic shunts in cats: seven cases (1976-1984) **J Am Vet Med Assoc**, v.189, p.317-25, 1986.
- SCHERMERHORN,T. et al. Characterization of hepatportal microvascular dysplasia in a kindred of Cairn Terriers. **J Vet Int Med**, v.10, n.4, p.219-30, 1996.
- SZATMÁRI,V. et al. Ultrasonographic assessment of hemodynamic changes in the portal vein during surgical attenuation of congenital extrahepatic portosystemic shunts in dogs. **J Am Vet Med Assoc**, v.224, n.3, p.395-402, 2004. Disponível em: <<http://avmajournals.avma.org/doi/abs/10.2460/javma.2004.224.395>>. Doi: 10.2460/javma.2004.224.395.
- TISDALL,P.K.C. et al. Neurological dysfunction in dogs following attenuation of congenital extrahepatic portosystemic shunts. **J Small Anim Pract**, v.41, n.12, p.539-46, 2000. Disponível em: <<http://www3.interscience.wiley.com/journal/119006088/abstract>>. Doi: 10.1111/j.1748-5827.2000.tb03150.
- WRIGLEY,R.H. et al. Ultrasonographic diagnosis of portocaval shunts in young dogs. **J Am Vet Med Assoc**, v.191, p.421-24, 1987.