

Nevi and cutaneous hamartomas in dogs: retrospective clinical and epidemiologic study of 81 cases

Nevus e hamartomas cutâneos em cães: estudo retrospectivo clínico e epidemiológico de 81 casos

Fabricia Hallack Loures¹ Lissandro Gonçalves Conceição^{II}

ABSTRACT

In a period of eight years, nevic lesions were diagnosed in 81 cases. Fibroadnexal hamartoma (FH) occurred in 53 animals (65.4%), and it was clinically characterized by firm nodules located mainly on the limbs and digits. No sexual predisposition was present. Mongrels, Boxers and Cocker Spaniels were the breeds most affected by FH. The average age at which lesions appeared was 6.3 years. The collagenous nevi was the second most prevalent lesion, occurring in 18 dogs (22.2%). The lesions were usually single, alopecic and hyperpigmented. The main affected places were the dorso and limbs. The average age at which lesions appeared was 4.7 years. Mongrels, Rottweilers and Labradors were the breeds most affected by the collagenous nevi. Nodular dermatofibrosis was diagnosed in one dog. In this dog, multiple collagenous nevi were present alongside unilateral papillary renal cystadenoma. Sebaceous, follicle-apocrine and fibrolipomatous nevi were less frequently found (10 cases – 12.3%).

Key words: nevi, hamartoma, dog, dermatosis.

RESUMO

As lesões névicas foram diagnosticadas em 81 casos, em um período de oito anos. O Hamartoma fibroanexial (HF) ocorreu em 53 animais (65,43%) e caracterizou-se clinicamente por lesões nodulares, geralmente firmes, localizadas predominantemente nos membros e dígitos. Não houve predileção sexual. Os animais mestiços e os das raças Boxer e Cocker Spaniel foram os mais acometidos pelo HF. A idade média de aparecimento das lesões foi de 6,3 anos. O nevo colágeno foi a segunda lesão mais prevalente, ocorrendo em 18 cães (22,2%). As lesões foram, em geral, únicas, alopecicas e hiperpigmentadas, localizadas em sua maioria no tronco, no dorso e nos membros. A idade média de aparecimento das lesões foi de 4,7 anos. Os animais mestiços e os das raças Rottweiler e Labrador Retriever foram os mais

acometidos. Em um dos cães, diagnosticou-se dermatofibrose nodular, onde foram observados múltiplos nevos colágenos em associação com cistadenoma renal papilar unilateral. Os demais tipos de nevos (sebáceo, foliculo-apócrino, folicular e fibrolipomatoso) ocorreram com menor frequência (10 casos - 12,3%) dos casos.

Palavras-chave: nevo, hamartoma, cão, dermatose.

INTRODUCTION

Nevi (Latin *Naevus*: birthmark) is an encircled and stable malformation of the skin, probably congenital, characterized by the focal excess of one or several mature tissue components (MEHREGAN, 1986; GOLDSCHMIDT & SHOFER, 1992). The meaning of the hamartoma word is similar to nevi, but the former is related to a lesion inclined to deviate from the normal histological structure, whose components are not necessarily mature and may show a more extensive growth (MEHREGAN, 1986; WALDER & GROSS, 1992). Moreover, whereas the term nevus is restrictively used for the skin, a hamartoma may be employed for hyperplastic alterations in any tissue (SCOTT et al., 2001).

In veterinary medicine, only a few studies on nevi and hamartomas have been performed. Often creating uncertainties and confusion, several terms have been employed to describe hamartomatous lesions caused by dysplastic epidermal appendages and fibroplasia. Organoid nevus, adnexal nevus, focal

¹Autônoma - Médica Veterinária. Convênio de consultoria em Dermatopatologia Comparada Fundação Arthur Bernardes (Funarbe), Universidade Federal de Viçosa, (UFV), Viçosa, MG, Brasil.

^{II}Departamento de Veterinária, UFV, 36570-000, Viçosa, MG, Brasil. E-mail: lissandro@ufv.br. Autor para correspondência.

adnexal dysplasia and fibroadnexal dysplasia are some of the terms employed (GOLDSCHMIDT & SHOFER, 1992; WALDER & GROSS, 1992; YAGER & WILCOCK, 1994; SCOTT et al., 2001). However, some authors prefer to use the term fibroadnexal hamartoma (FH), also adopted in this study (GROSS et al., 2005; LOURES, 2005).

Collagen nevus (CN) is relatively common among dogs and is characterized by a focal excess of dermal collagen. This nevus started to be acknowledged as a distinct entity only after its first description in veterinary medicine in 1984, previously being diagnosed probably as fibromas (SCOTT et al., 1984). The lesions are usually single, firm, rounded and frequently located on the cephalic segment, cervical region and the proximal region of limbs (GROSS et al., 2005). Nodular dermatofibrosis, also known as multiple CN (SCOTT et al., 1984) or multiple cutaneous fibroma (GOLDSCHMIDT & SHOFER, 1992), is characterized by the progressive development of multiple firm and clearly encircled collagenic cutaneous nodules. These lesions are located mostly on the limbs, although others parts of the body such as head and trunk may also be involved (JONES, et al. 1985, LIUN & MOE, 1985; CONSENZA & SEELY, 1986; GILBERT et al., 1990 PERRY, 1995; SCOTT et al., 2001). The syndrome caused by multiple collagen nevi, bilateral renal cystadenocarcinoma and uterine leiomyoma is a rare disease which occurs specially in German Sheepdogs, despite the involvement of other breeds that have been reported (SCOTT, 2001; WHITE et al., 1998).

Follicular hamartoma or hair follicle nevus is more frequently characterized by multiple, nodular or plaque lesions that are thick, irregular, with several centimeters in diameter, and thick hairs abnormally coming out of a dilated follicular infundibulum (GOLDSCHMIDT & SHOFER, 1992; SCOTT et al., 2001; GROSS et al., 2005). Histopathologically, these lesions are characterized by united groups of anagen hair follicles which keep their normal distribution and architecture, predominantly located in the deep dermis, whose hair shafts are proportionally long. They may be associated to enlarged sebaceous glands, both in number and size, in addition to a fibroplasia of the dermal collagen (GROSS et al., 2005; LOURES, 2005). In the so called giant hair follicle disease, considered by some authors as a different form of FH, hair follicles are systematically hyperplastic, but not dysplastic (YAGER & WILCOCK, 1994). This present study describes the clinical and epidemiological aspects of FH, giant hair follicle disease, follicular nevus, CN, sebaceous nevus, follicle-apocrine nevus and lipofibromatous nevus.

MATERIAL AND METHODS

Files originated from two histopathological diagnosis services (Veterinary Department - Federal University of Viçosa and Provet - SP) were used for this study, during the period from 2001 to 2008. All cases, originated from several veterinary practices, underwent biopsy according to indication of the veterinarian who requested the service for diagnostic purposes. Nevic or hamartomatous lesions were reviewed and confirmed under light optical microscopy. Histopathological examination request forms were reviewed and clinical and assignment information was retrieved. Veterinarians who requested the service were contacted by telephone or email so that additional or supplementary information regarding the following items could be obtained: breed, age and gender of the animals; site, number, size and evolution (period comprising the moment when the owner noticed it to the clinical appointment) of lesions; occurrence of concomitant dermatological alterations; treatment performed and occurrence of relapses. When it was not possible to obtain information for every case studied, the total number of animals whose information was retrieved was indicated by "(n=x)". Animals displaying multiple lesions had all of them biopsied, thus confirming the histopathological diagnosis of nevus or hamartoma. Descriptive statistics were used for the analysis of results. The terms nevus or hamartoma were interchangeably employed in the different pathological entities described herein, respecting the terms traditionally found in the veterinary and medical literature.

RESULTS AND DISCUSSION

Eighty-one nevic or hamartomatous lesions were retrieved from a total of 5864 records. Fibroadnexal Hamartoma (FH) was the most frequent lesion, followed by CN. This result is compliant with what has been described in literature (GOLDSCHMIDT & SHOFER, 1992). Other nevic and hamartomatous lesions occurred in a minority of cases (12.34%).

Fibroadnexal Hamartoma (FH)

Out of 53 cases of FH, 58.0% occurred in males and 42.0% in females, with a male:female ratio of 1.4:1. The two genders seemed to be equally affected, similarly to what had been described in a previous study (GOLDSCHMIDT & SHOFER, 1992). Only 8.0% of the cases showed more than one lesion, a frequency higher than what had been mentioned in literature (GOLDSCHMIDT & SHOFER, 1992). It was considered

that the presence of multiple lesions can be due to other dermatological conditions (YAGER & WILCOCK, 1994). However, in this study, only one dog possessed a FH lesion on the site of another pathological condition (external otitis) (Figure 1A).

All FH lesions were exophytic, mostly firm (96.3%), with a smooth surface (89.0%) and alopecic (77.0% - n=27). Pruritus or discomfort were described in most cases (56.0% - n=32). The lesions had an average 2.5cm in diameter, with sizes ranging from 0.5 to 8cm. All these findings are similar to descriptions found in literature (GOLDSCHMIDT & SHOFER, 1992; YAGER & WILCOCK, 1994; GROSS et al., 2005).

The lesions occurred frequently on limbs, digits and interdigital area, suggesting that trauma could be the possible determining or predisposing factor. In a previous study, the extremities of the limbs also were the most affected areas (GOLDSCHMIDT & SHOFER, 1992) (Table 1)

The average age at which lesions occur was of 6.3 years, ranging from 1 to 12 years. A previous study reported that the majority of dogs were aged between 5 and 12 years, thus confirming that those lesions occur predominantly in adulthood (GOLDSCHMIDT & SHOFER, 1992). However, a thick fur may hide small and flat lesions, making their early recognition difficult (GROSS et al., 2005).

The evolution time of lesions ranged from one month to five years, with an average of 12.6 months (n=27). In an average period of 12 months (ranging from 3 to 36 months) after surgical excision, no relapse was observed in 96.5% of cases (n=29). Numbers about relapse and evolution of lesions were not mentioned in any study. The biological benign behavior related to these lesions (GOLDSCHMIDT & SHOFER, 1992; GROSS et al., 2005) was also confirmed through this study, based on the minimum relapse rate and slow evolution of lesions.

FH' etiology is controversial. The cicatricial reaction, after a chronic inflammatory process, could involve and distort follicle-sebaceous units. In a previous histopathological study, fibroplasia occurred in the majority of FH lesions (Figure 1B). (LOURES, 2005). Nonetheless, despite they showed a marked distortion of adnexal structures, small lesions frequently did not show inflammation (WALDER & GROSS, 1992; GROSS et al., 2005), therefore pathogenesis may include some other unknown factor, such as racial or individual predisposition to explain the follicle-sebaceous alterations (WALDER & GROSS, 1992).

Mongrel dogs (8 cases - 15.1%), Boxers (6-11.3%), Cocker Spaniels (6-11.3%), Doberman Pinscher (4-7.5%), Labrador Retriever (4-7.5%) and German

Shepherd (3-5.7%) were the most affected breeds. In literature, Labrador Retrievers and Doberman Pinschers also had an increased risk, in addition to Weimaraners and Dalmatians (GOLDSCHMIDT & SHOFER, 1992).

Collagen Nevus

CN was diagnosed in 18 animals. There was no gender predisposition (male:female ratio of 1:1; n=18) for CN occurrence, similarly to what was mentioned in a previous study (MOE & LIUN, 1997). In 85.7% of the cases, there was reference to a single lesion with only 14.3% displaying several lesions (n=14). The majority of lesions were alopecic (77.8%) and hyperpigmentation occurred in nearly half of the cases (44.4%) (n=9). Pruritus or discomfort and ulceration were not mentioned in any case (n=9). These results are compliant with previous studies, despite ulceration, which was present in some multiple CN lesions, was not observed in this study (SCOTT et al., 1984; COSENZA & SEELY, 1986; GILBERT et al., 1990; PERRY, 1995; MOE & LIUN, 1997; GROSS et al., 2005).

The evolution time of lesions ranged from 7 days to 24 months, with an average of 7.2 months. The average age at which lesions occurred was of 4.7 years, ranging from 2 to 9 years (n=7). There are no reports in literature about the evolution time and age at which CN's single lesions appeared.

The most affected breeds were Rottweilers (27.8%), Labrador Retrievers (22.2%) and Mongrels (16.6%). Other breeds (Dachshund, Great Danes, Fila Brasileiro, Pit Bull, Sharpei and West Highland White Terrier) occurred each in only 5.55% of the cases (n=18). No racial predisposition for CN's single lesions has been mentioned (GROSS et al., 2005).

The anatomical areas most affected by CN were the trunk (41.6%), and posterior limbs (16.6%). In a minority of cases, cervical, digital, abdomen, head and scrotal areas were affected once (8.33%; n=12). These results are compliant with previous reports (GROSS et al., 2005), despite some sites (such as trunk and abdomen), which have been mentioned only in multiple CN (SCOTT et al., 1984; LIUN & MOE, 1985; COSENZA & SEELY, 1986; GILBERT et al., 1990) also have been mentioned in single lesions in this study. The size of lesions ranged between 0.3 and 3.5cm in diameter, with an average of 1.0cm in diameter (n=17), similarly as in a previous description. (GROSS et al., 2005).

The presence of systemic alterations were reported in only 2 animals (14.3%; n=14). Upon ultrasonographic examination, an 8-year-old female Rottweiler displayed a round structure at the dorsal portion of the left kidney, suggesting a neoplastic or

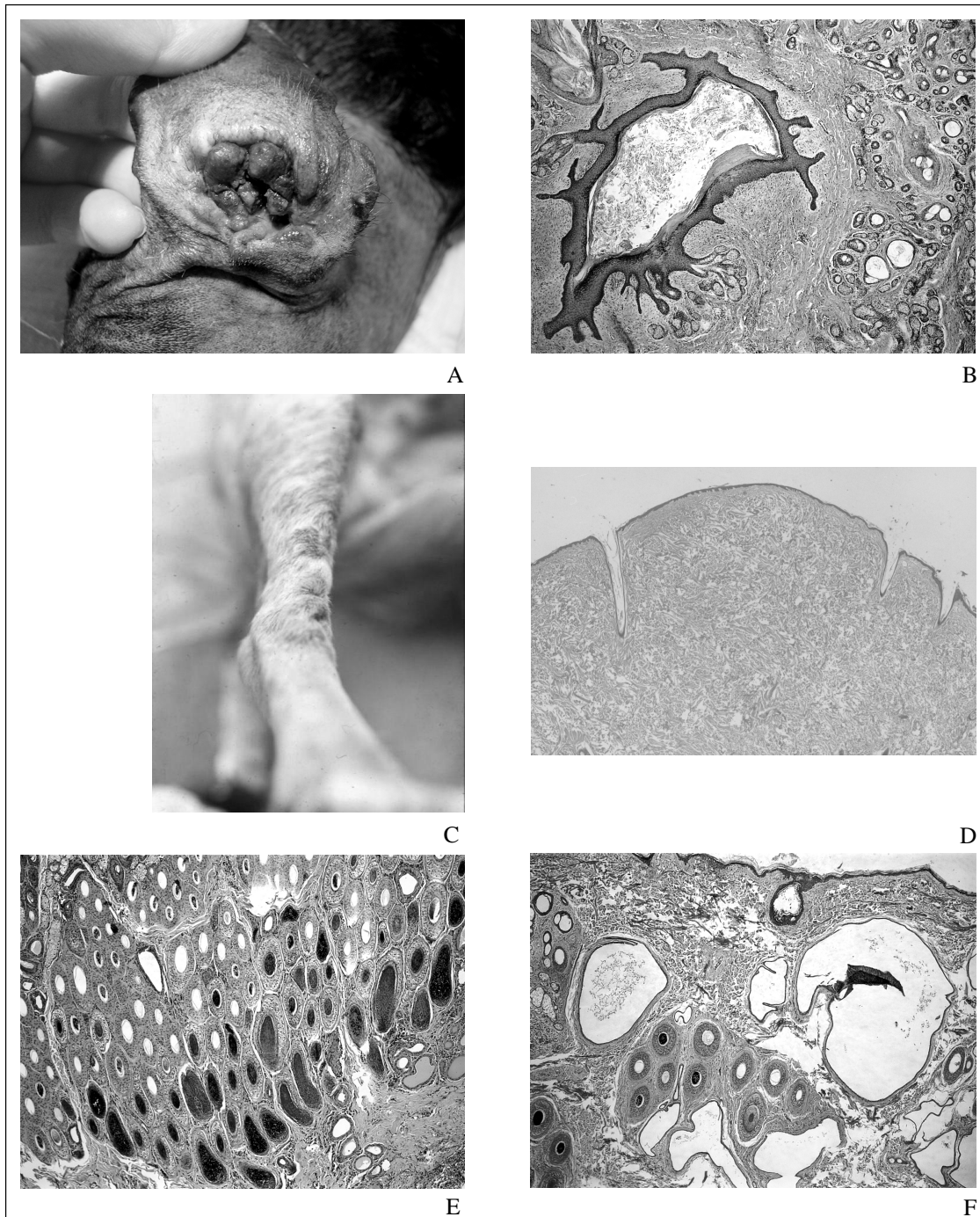


Figure 1 - Cutaneous hamartoma in dog. A: Fibroadnexal hamartoma. A large, tumoral and hyperpigmented polypoid lesion obstructing the external ear canal. B: Fibroadnexal hamartoma. A large, dilated and bizarre hair follicle is surrounded by a fibrous stroma and high numbers of haphazardly arranged and well differentiated sebaceous glands and ducts. C: Collagen nevus (nodular dermatofibrosis). Multiple firm, partially alopecic and hyperpigmented skin nodules on the cranial surface of hind limb. D: Collagen nevus. Redundant and more compact collagen fibers of normal appearance. E: Follicular hamartoma. Multiple large sized anagen hair follicles are arranged in very thick cluster. F: Follicle-apocrine hamartoma. Large hair follicles are surrounded by dilated, hyperplastic and irregular apocrine glands.

Table 1 - Observation frequency, according to the anatomic location of fibroadnexal hamartomas in dogs (n=50).

Location	Number of animals (%)
Limbs	23 (46.0)
✓ Anterior	11 (22.0)
✓ Posterior	10 (20.0)
✓ No information on the limb	2 (4.0)
Digit/Interdigital	8 (16.0)
Cervical	4 (8.0)
Dorso	3 (6.0)
Head	3 (6.0)
Torso (lateral)	2 (4.0)
Abdomen (lateral)	1 (2.0)
Tail	1 (2.0)
Perianal	1 (2.0)
Multiple	4 (8.0)

cystic formation. In this animal, it is possible that CN played the role of a cutaneous marker for the alterations found. Upon ultrasonographic examination of the abdominal cavity, the other animal, a 7-year-old female Mongrel with multiple CN presented cysts of different sizes on the left kidney's parenchyma, which turned out to be a unilateral papillary cystadenoma upon histopathology. In this case, the diagnosis of nodular dermatofibrosis (Figure 1C) associated to unilateral papillary cystadenoma was confirmed. A dome shaped proliferative mass of hypocellular, redundant and mature collagen was seen histopathologically (Figure 1D). Therefore, it is important to consider nodular dermatofibrosis even in non-predisposed breeds and with a unilateral renal lesion (CONCEIÇÃO et al., 2000).

Giant Hair Follicle Disease

In the present research, giant hair follicle disease occurred in three bitches. One Teckel, Poodle and Mongrel dog, aged, respectively, 15, 11 and 4 years were affected each. In one of the cases, two ulcerated nodules on the dorsal cervical and left scapular region were found. The lesions were single and nodular in the other animals, located on limbs and abdomen and presenting an average evolution period of six months without relapses, within an average of 11 months after surgery. Information on the clinical characteristics of this nevus was not mentioned in any study.

It was suggested that FH and giant hair follicle disease may represent different stages of the same pathological process (LOURES, 2005). Therefore, a progressive hyperplasia of epidermal appendages would occur, becoming crooked and dysplastic afterwards, in response to some non-established component (such as a genetic predisposition or a repeated trauma).

Follicular Hamartoma or Hair Follicle Nevus

Hair follicle nevus occurred in two Cocker Spaniel dogs. The first animal, a five-year-old male, displayed a non-alopecic lesion of about 0.5cm in diameter, located on the nasal bridge and with an evolution time of two months. No other information was obtained on the later evolution of this case. The other dog, a six-year-old female, possessed several non-alopecic papules of about 3mm in diameter with interdigital and tarsal location at the posterior limbs, with an evolution time of 18 months. There was no relapse of these lesions within a 12-month period after the surgery.

The lesions were firm, papular and non-alopecic, as described in veterinary literature (GOLDSCHMIDT & SHOFR, 1992; SCOTT et al., 2001; GROSS et al., 2005). Despite the fact that small lesions have been reported to be usually single (GROSS et al., 2005), the female mentioned in this study showed multiple papules of up to 3mm in diameter. The average evolution time of lesions, not mentioned in any previous study, was of 10 months. The microscopic findings included several architectural normal but large hair follicles in the anagen phase grouped together in clusters (Figure 1E).

Sebaceous Nevus

Sebaceous nevus occurred in two animals, a 10 and a 12-year-old female Poodle and Bichon Frise, respectively. Both animals had papular-nodular, single, encircled, alopecic and pruritic lesions, located at the tail base and posterior limbs, sized between 0.5 and 1.0cm in diameter. There was no relapse of these lesions within a 25-month period after surgical excision. In the few cases described in literature, this nevus was characterized by single or multiple alopecic, nodular or plaque lesions (GOLDSCHMIDT E SHOFR, 1992; SCOTT et al., 2001; GROSS et al., 2005), with no description of racial predisposition (GROSS et al., 2005). Pruritus and absence of relapse, observed in the dogs studied, were not mentioned in other studies.

Follicle-Apocrine Hamartoma

Follicle-apocrine hamartoma occurred in two dogs. One of them was a 12-year-and-three-month old female Poodle, possessing a firm nodule that evolved in two months, located on the anterior limb and with 3.5cm in diameter. There was no relapse of the lesion within a 24-month period after the surgery. The second case occurred in a three-year-and-eight-month old male Golden Retriever, which had a firm nodule on the lateral region of the face with 4.0cm in diameter, which evolved in five months. There was no relapse of the lesion within a 20-month period after surgical excision.

These lesions may represent a histopathological variety of FH, in which only apocrine sweat glands are considered abnormal, whilst the remaining epidermal appendages are only hyperplastic (Figure 1F). Apparently, their biological behavior is benign, with no relapse in an average period of 22 months after surgical excision.

Lipofibromatous Nevus:

In human beings, superficial cutaneous lipomatous nevus has two distinct clinical forms (NOGITA et al, 1994). In one of them, multiple papular-nodular lesions with a smooth or irregular surface were observed, manifested either on birth or during the first three life decades, usually located on the pelvic region (NOGITA et al., 1994; MCKEE, 1996). In the second form, also called pedunculated lipofibroma, single lesions which can be located on several anatomic regions were observed (NOGITA et al., 1994).

Lipofibromatous nevus occurred in one 7-year-old female Husky Siberian dog, which displayed an irregular-surfaced, pedunculated lesion with 3cm in diameter and hyperpigmentation areas, located on the perivulvar region and that evolved in 2 months. There was no relapse of the lesion within a 24-month period after surgical excision.

In summary, nevic or hamartomatous lesion represented 1.38% of all skin lesion diagnosed in an eight years period. Fibroadnexal hamartoma was the most common lesion in the dog, followed by the collagenous nevus. Limbs and digits were the anatomical region most affected by fibroadnexal hamartoma in the dog, and the prognosis after surgical excision seems to be good in most cases.

REFERENCES

- CONCEIÇÃO, L.G. et al. Nodular dermatofibrosis in a mixed breed dog. In: SCIENTIFIC ABSTRACTS FOURTH WORLD CONGRESS OF VETERINARY DERMATOLOGY, 2000, San Francisco, California. **Proceedings...** San Francisco: Veterinary Dermatology, 2000. 66p. p.55.
- CONSENZA, S.F.; SEELY, J.C. Generalized nodular dermatofibrosis and renal cystadenocarcinomas in a German Shepherd Dog. **Journal American Veterinary Medical Association**, v.189, p.1587-1590, 1986.
- GILBERT, P.A. et al. Nodular dermatofibrosis and renal cystadenoma in a German Shepherd Dog. **Journal of the American Animal Hospital Association**, v.26, p.253-256, 1990.
- GOLDSCHMIDT, M.H.; SHOFER, F.S. **Skin tumors of the dog and cat**. U.K.: Pergamon, 1992. 316p.
- GROSS, T.L. et al. **Skin diseases of the dog and cat. Clinical and histopathologic diagnosis**. 2.ed. Oxford: Blackwell Science, 2005. 932p.
- JONES et al. Cutaneous collagen nodules in a dog. **Journal of the Small Animal Practice**, v.26, p.445-451, 1985.
- LIUN, B.; MOE, L. Hereditary multifocal renal cystadenocarcinomas and nodular dermatofibrosis in the german shepherd dog: macroscopic and histopathologic changes. **Veterinary Pathology**, v.22, p.447-455, 1985.
- LOURES, F.H. **Nevos anexiais em cães: aspectos clínicos e histopatológicos em 61 casos**. 2005. 38f. Dissertação (Mestrado em Medicina Veterinária) – Curso de pós-Graduação em Medicina Veterinária, Universidade Federal de Viçosa, MG.
- MCKEE, P.H. **Pathology of the skin**. 2.ed. London: Mosby-Year Book, 1996. 17.14p.
- MEHREGAN, A.H. **Pinku's guide to dermatohistopathology**. 4.ed. Norwalk: Appleton-Century-Crofts, 1986. 655p.
- MOE, L.; LIUN, B. Hereditary multifocal renal cystadenocarcinomas and nodular dermatofibrosis in 51 German shepherd dogs. **Journal of Small Animal Practice**, v.38, p.498-505, 1997.
- NOGITA, T. et al. Pedunculated lipofibroma. **Journal of the American Academy of dermatology**, v.31, p.235-240, 1994.
- PERRY, W. Generalised nodular dermatofibrosis and renal cystadenoma in a series of 10 closely related German Shepherd Dogs. **Australian Veterinary Practitioner**, v.25, p.90-93, 1995.
- SCOTT, D.W. et al. **Muller and kirk's small animal dermatology**. 6.ed. Philadelphia: Saunders, 2001. 1130p.
- SCOTT, D.W. et al. Nevi in the dog. **Journal of the American Hospital Association**, v.20, p.505-512, 1984.
- WALDER, E.J.; GROSS, T.L. Focal adnexal dysplasia (Folliculosebaceous hamartoma). Advances in veterinary dermatology. In: WORLD CONGRESS OF VETERINARY DERMATOLOGY, 2., 1992, Montreal. **Proceedings...** Montreal: Pergamon, 1992. p.311-13.
- WHITE, S.D. et al. Nodular dermatofibrosis and cystic renal disease in three mixed-breed dogs and a Boxer dog. **Veterinary Dermatology**, v.9, n.2, p.119-126, 1998. Disponível em: <<http://www3.interscience.wiley.com/cgi-bin/fulltext/119129925/HTMLSTART>>. Access in: sept/01/2009. doi: 10.1046/j.1365-3164.1998.00100.x
- YAGER, J.A.; WILCOCK, B.P. **Color atlas and text of surgical pathology of the dog and cat: dermatopathology and skin tumors**. London: Wolfe Publishing, 1994. 320p.