

Comparative study between radiology and ultrasound in the evaluation of extracardiac thoracic diseases in dogs and cats

Estudo comparativo entre radiologia e ultrassonografia na avaliação de doenças torácicas extracardíacas em cães e gatos

Sâmara Turbay Pires^I Maria Cristina Ferrarini Nunes Soares Hage^{II}
Ana Carolina Brandão de Campos Fonseca Pinto^{III} Stefano Carlo Filippo Hagen^{III}

ABSTRACT

This study compared radiographic and B-mode and Doppler ultrasound exams of the thoracic cavity, excluding the heart, in canine and feline species, in which the radiographs revealed the formation of a potential acoustic window. The objectives were to demonstrate the advantages and limitations of each technique and to determine whether the additional information influenced the differential diagnosis as well as the outcome of each case. The advantages of B-mode ultrasonography included: better qualitative and quantitative evaluation of pleural effusions, an improved ability to determine whether a nodule was solid or cystic and easier determination of the location in the pulmonary parenchyma. The Power Doppler ultrasound evaluated the blood supply pattern of the nodules and masses and differentiated between vessels and fluid bronchogram. A limitation of the ultrasound examination was the need to be guided by the previous radiography. The advantages of the radiographic examination included the possibility of localizing pulmonary lesions at any depth in the absence of a pleural effusion and providing a panoramic view of the extent of the thoracic disease. The ultrasound examination influenced the differential diagnosis in 18 (62.06%) cases and influenced the outcome of 8 (27.58%) cases.

Key words: *thorax, lung, diagnostic imaging, radiography, thoracic ultrasound.*

RESUMO

Este estudo comparou os exames radiográficos e ultrassonográficos modo-B e Doppler da cavidade torácica, excluindo o coração, em animais da espécie canina e felina, nos casos em que as radiografias torácicas revelaram formação de janela acústica em potencial. O objetivo foi demonstrar as vantagens e limitações de cada técnica e determinar se as informações adicionais influenciaram o diagnóstico diferencial, bem como no desfecho de cada caso. As vantagens do modo B

incluíram: melhor avaliação qualitativa e quantitativa de efusão pleural; determinação da natureza sólida ou cística de nódulos, bem como a definição de sua localização no parênquima pulmonar. O ultrassom Doppler de Amplitude permitiu a avaliação do padrão de irrigação sanguínea de nódulos e massas e a diferenciação entre vasos e broncogramas fluidos. Uma limitação do exame de ultrassom foi a necessidade de se guiar pela radiografia prévia. As vantagens do exame radiográfico foram: possibilidade de localização de lesões pulmonares em qualquer profundidade na ausência de efusão pleural e proporcionar uma visão panorâmica do acometimento da cavidade torácica. O exame ultrassonográfico proporcionou impacto no diagnóstico diferencial de 18 (62,06%) dos casos e influenciou no desfecho de 8 (27,58%).

Palavras-chave: *tórax, pulmão, diagnóstico por imagem, radiografia, ultrassom de tórax.*

INTRODUCTION

Radiographic examinations are essential for the evaluation of thoracic diseases. However, the findings are often nonspecific or can be limited by the presence of pleural fluid or the involvement of multiple thoracic compartments (REICHLE & WISNER, 2000). The usefulness of thoracic ultrasound is maximized when it is performed together with thoracic radiography. The location and type of disease found on radiographs can help with the formation of a potential acoustic window (MATTOON & NYLAND, 2005). The ultrasound plays an increasingly important role in the diagnosis of several pulmonary, pleural

^IDepartamento de Veterinária (DVT), Universidade Federal de Viçosa (UFV), Viçosa, MG, Brasil.

^{II}Departamento de Medicina Veterinária, Universidade de São Paulo (USP), Av. Duque de Caxias Norte, 255, 13635-900, Pirassununga, SP, Brasil. E-mail: crishage@usp.br. Corresponding author.

^{III}Departamento de Cirurgia, USP, São Paulo, SP, Brasil.

and mediastinal conditions by providing information about the location, size, extent and nature of the lesion (REICHLER & WISNER, 2000). The objective of this study was to demonstrate the advantages and limitations of the technique of radiography and B-mode and Doppler ultrasound of the thoracic cavity in canine and feline species. Furthermore, at the end of the study, it was determined whether the additional information influenced the differential diagnosis and the outcome of each case.

MATERIALS AND METHODS

A prospective and comparative study between radiographic and B-mode and Doppler ultrasound of the thorax, excluding the heart, was conducted in dogs and cats. Cases of animals suspected of having thoracic disease, identified in 21 consecutive months, were included. Radiographic examination was performed first; if a potential acoustic window was identified, the animals underwent a thoracic ultrasound examination. The animals were excluded from the study if the radiograph did not reveal a potential acoustic window and if the animal's general condition was a contraindication to manipulation. For the radiographic examination, a 200mA, 110kV Omega 200T device was used. The radiographic film and the technique were based on the animal size and the thickness of the region to be radiographed. Three radiographic projections (laterolateral right (RLL), laterolateral left (LLL) and ventrodorsal (VD) were performed, except in dyspneic animals in which only dorsoventral positioning was performed. The radiographic films were developed and fixed manually. The ultrasound examination was performed with a SonoSite 180 Plus device (version 1.99) (SonoSite Inc., Bothell, WA, EUA) with two transducers, an electronic sector transducer (4.0 to 7.0 MHz) and a linear electronic transducer (5.0 to 10 MHz). The animals were prepared for examination with hair removal in the anatomic region under examination, and gel was applied. The appropriate transducer for intercostal, transhepatic or cranial mediastinal examination was selected according to the acoustic window visualized radiographically. Image acquisition was performed in the B-mode in the dorsal and transverse planes and repeated using the Power Doppler technique when applicable. The sonographic examination was evaluated by one observer. After the radiographic and ultrasound examinations, the results of the two methods were compared to assess the impact of the latter method on the diagnosis. The impact of ultrasonography was

considered if it helped in the differential diagnosis (cases in which there was reduction in the list of differential diagnoses, additional information or a change of diagnosis); influenced the outcome (cases in which the findings altered the clinical management); or did not affect the diagnosis. The radiographs were subsequently evaluated by two observers (A.C.B.C.F.P. and S.C.F.H.) who were blinded to the clinical history as well as the physical, laboratory and ultrasound findings. The radiographic findings of the three evaluators (two blind and ours) were compared (if there was correlation between the evaluations). Necropsies were performed on animals that were euthanized or that subsequently died.

RESULTS

Twenty-nine cases were studied, including 27 (93%) canines and 2 (7%) felines. Of these, 18 (62%) animals were female and 11 (38%) animals were male.

Of the 29 cases that radiographically demonstrated a potential acoustic window, 27 (93%) animals revealed an effective acoustic window. Of these animals, the acoustic window was due to masses and nodules on the surface of the thorax in 15 cases, pleural effusion in 9 cases, pulmonary consolidation in 4 cases and visualization of mediastinal masses (enlarged sternal lymph nodes) in 2 cases. In two cases, the potential acoustic window was not effective due to a small sternal lymph node and small osteomas.

Based on the opinion of at least one of the blinded observers, 9 of the 29 cases were considered to not have a potential acoustic window. Two cases did not form an effective acoustic window, but in 7 cases, an ultrasound image was obtained.

The advantages and limitations of the technique of radiography and B-mode and Doppler ultrasound of the thoracic cavity are shown in table 1.

At the end of the study, the impact of the ultrasound examination was compared with our evaluation of the radiographic examination and the blind evaluation. The formation of a potential acoustic window was based on the opinion of at least one observer, i.e., in the blind evaluation, 20 cases were considered to have a potential acoustic window (Table 2).

The outcome was influenced by the following additional information: the suggestion of a pulmonary consolidation rather than a nodule; the exclusion of a diaphragmatic rupture; the location and characterization of an abscess or neoplasm with central necrosis; the identification of adenopathy in the cranial

Table 1 - Advantages and limitations of the technique of radiography and B-mode and Doppler ultrasound of the thoracic cavity in canine and feline species.

Items reviewed	Advantages		Limitations	
	Radiography	Ultrasound	Radiography	Ultrasound
Amount of pleural effusion	---	Best estimate of the amount of pleural effusion (5 cases).	Underestimated (4 cases) or overestimated (1 case) amount of pleural effusion.	---
Characteristic of pleural effusion	---	Possible to identify the echogenicity of the fluid providing qualitative information about its nature: without debris (8 cases) and presence of debris (1 case).	Impossible to establish any relationship to the nature of the liquid.	---
Identification of structures immersed in pleural effusion	---	Allowed the identification of submerged structures in pleural effusion (6 Cases).	The silhouette effect prevents differentiation of pleural effusions and structures with water radiopacity.	---
Evaluation of tissue	It allowed the location of lesions in lung tissue at any profundity in the absence of pleural effusion (10 cases).	Possible to investigate the nature of nodules and masses (solid or cystic differentiation) in the presence of an acoustic window (19 cases). Evaluation of lung tissue due to consolidation (4 Cases).	The technique prevents the evaluation of the tissue of nodules and masses.	Impossible to assess the lung tissue in the absence of acoustic window (8 Cases).
Size of the lesion	Provided overview of the involvement of the thoracic cavity (all cases).	---	---	Only allowed assessment of lesions that made contact with the wall of the chest cavity. In this study, the evaluation was guided by the identification of potential acoustic window by radiology (all except one case).
Location of the lesion	---	Allowed the definition of the lesion in the lung tissue due to sliding sign (16 cases). Location in the chest wall in the absence of sliding sign (2 cases).	In some cases, it was impossible to know the origin of the lesions (lung tissue, chest wall, ribs, pleural cavity, mediastinum or diaphragm) (13 cases).	---
Vascularity of the lesion	---	Amplitude Doppler ultrasound allowed assessment of the pattern of blood vascularization of nodules and masses in lung tissue (16 cases) and to differentiate between vessels and fluid bronchograms (4 cases).	The technique does not allow assessment of the blood vasculature.	---
Physical condition	---	Facilitates the evaluation of dyspneic animals due to the possibility standing position.	Was not possible to perform the laterolateral projections in the animal due to dyspnea.	---

mediastinum, suggesting lymphoma; the identification of pleural effusion with the presence of debris, suggesting pyothorax (Figure 1); and the quantification of the pleural effusion resulting in the decision to not

perform a thoracentesis. In this study, the ultrasound affected the differential diagnosis in 10 animals. Although important information for the diagnosis was provided, this information did not influence clinical

Table 2 - Impact of the ultrasound examination in relation to the radiographic examination.

Evaluators	Impact on the differential diagnoses	Influenced the outcome	Did not affect the diagnosis
Our evaluation (29 animals)	18 (62.06%)	8 (27.58%)	11 (37.93%)
Blind evaluation (20 animals)	10 (50%)	2 (10%)	10 (50%)

management. Of these 10, in 9 animals, the exact location of the mass or nodules and tissue evaluation provided additional insight. In one animal, a structure immersed in free fluid was identified. In 11 cases, there was no impact on the differential diagnosis or on the outcome. In 6 cases, radiographic findings were confirmed by ultrasound but did not influence the diagnosis. In 2 cases, no effective acoustic window was identified. Therefore, there was good correlation of our radiographic evaluations and the evaluation of the blinded evaluators regarding the impact on the differential diagnosis provided by ultrasound examination for non-cardiac thoracic diseases, 62.06% and 50%, respectively.

DISCUSSION

In this study, the best transducer for the thoracic evaluation of dogs and cats was the sectorial electronic transducer (4.0 to 7 MHz) because of the reduced skin-contact surface. One of the advantages of the ultrasound examination was its portability. This feature facilitated the examination of patients in the emergency room. The evaluation of animals in sternal recumbency was possible and thus reduced the need for manipulation, corroborating SCHWARZ & TIDWELL (1999). The high incidence of females with nodules or thoracic masses can be explained by the fact that these animals were radiographically evaluated for lung metastases of mammary neoplasms.

The formation of an acoustic window was essential for ultrasound evaluation of the thoracic cavity. Formation of an acoustic window was possible in areas where there was no air between the transducer and the lesion, consistent with the descriptions by MATTOON & NYLAND (2005) and LARSON (2009).

In this study, with only the radiographic examination, lesions of the thoracic structure would be impossible to distinguish in many of the cases. The nodules identified on the chest wall

were confirmed by the absence of the sliding sign and by visualizing the ribs distal to the lesions. This sign allowed for easy identification in most of the cases. However, in animals that presented with shallow respiration that limited lung movement, the perception of this sign became more difficult. The sliding sign was reported by TIDWELL (1998). Another advantage of the ultrasound was the possibility of evaluating masses or nodules. According to PAULINELLI et al. (2002), twelve animals presented with ultrasound characteristics of malignancy (irregular borders and hyperechoic spots), but the definitive diagnosis could only be confirmed after histopathological examination. In one animal, the mass presented irregular borders, an anechoic center with hyperechoic spots and a peripheral echogenic halo that was suggested to be an abscess, which was confirmed by necropsy. This description is consistent with the findings in the literature (FAUSTO & CHAMMAS, 2009). Most nodules in the present study were thought to be metastases because of the little or lack of vascularization detected by the Doppler examination described by CHAMMAS et al. (2009). The presence of primary neoplasms in

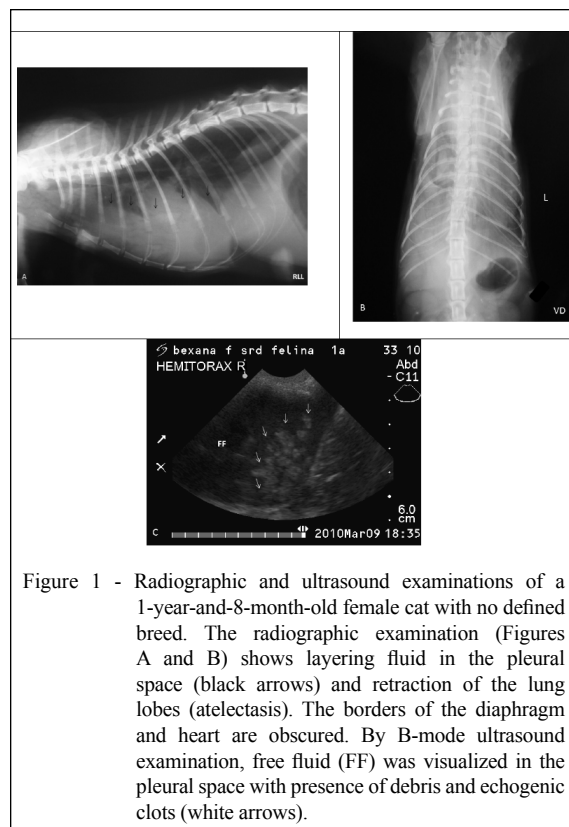


Figure 1 - Radiographic and ultrasound examinations of a 1-year-and-8-month-old female cat with no defined breed. The radiographic examination (Figures A and B) shows layering fluid in the pleural space (black arrows) and retraction of the lung lobes (atelectasis). The borders of the diaphragm and heart are obscured. By B-mode ultrasound examination, free fluid (FF) was visualized in the pleural space with presence of debris and echogenic clots (white arrows).

other locations, such as mammary neoplasms, would have suggested that the lung nodules were metastases, but this finding could only be confirmed by histopathological examination. In 4 animals, a Doppler reverberation artifact was observed in the periphery of the nodule. This finding can be mistaken for peripheral vascularization. Furthermore, the nodules in the ultrasound appeared slightly smaller than in the radiographic examination. The larger appearance upon radiographic examination can be explained by lung atelectasis around the nodule or by the inflammatory infiltrate as described by MYER (1980). To determine the exact sizes of these nodules or masses, further investigations with more sensitive imaging methods or necropsy (gold standard) should be conducted. The radiographic examination was better at detecting nodules because some lesions were not visualized by ultrasound, most likely because they were surrounded by aerated lung, which prevented their detection. The superiority of the radiographic examination in relation to the ultrasound was based on the possibility of a panoramic view of the thorax, which led to better descriptions regarding the extent of the lesion.

An acoustic window created by a pleural effusion was easily detected. Even small amounts of free fluid in the pleural space were capable of creating an acoustic window, enabling the assessment of deeper structures, which were usually not typically visualized because the lung was aerated (Figure 2). The advantage of the ultrasound was the possibility of evaluating and characterizing the pleural effusion. The results demonstrated that the anechoic effusions could represent transudative or exudative processes. However, the fluid with echogenic characteristics and the presence of floating particulate matter, septations or fibrin filaments represented an exudate, a phenomenon also noted by YANG et al. (1992). Another important advantage of ultrasound is the capacity to distinguish the amount of fluid present. The ultrasound is considered to be the gold standard for the evaluation of pleural effusions (SPERANDEO et al., 2008). Given the possibility of a small effusion, as observed in one case, ultrasound may be used prior to thoracentesis, as suggested by LARSON (2009). In this case, the radiopacity visualized by radiographic examination represented the overlapping of the free fluid in the pleural space with the more radiopaque lung due to a possible edema, which was confirmed by a positive response to the treatment. A thoracentesis without an initial evaluation with ultrasound could lead to complications.

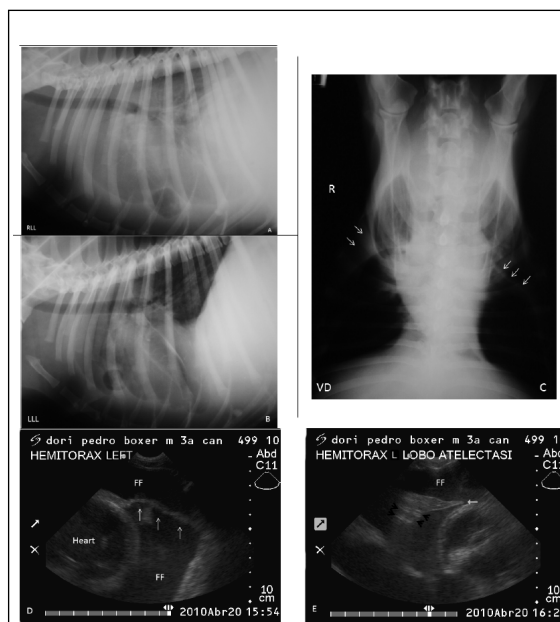


Figure 2 - Radiographic and ultrasound examinations of a male 3-year-old Boxer. Radiographic examination on the right and left laterolateral projections (RLL and LLL) and ventrodorsal projection (VD) (Figures 2A, B and C) revealed an increase in the homogeneous water radiopacity in the pleural space and dispersed throughout the thorax, leading to visualization of the interlobar incisions (white arrows) and retraction of the lung lobes (atelectasis), resulting in delimitation of their borders. It is difficult to identify the diaphragm and heart. The B-mode ultrasound examination (Figures D and E) shows the phreno-pericardial ligament (white arrows), confirming the presence of a large quantity of free fluid (FF) in the pleural space (Figure D) and the presence of an atelectatic lung lobe (arrows) (Figure E).

In cases of mediastinal diseases (2 cases), to form an acoustic window, lesions must be large enough to come into contact with the chest wall, corroborating LARSON (2009). The approach through the cranial mediastinum enabled the visualization of a lymph node in one case and the visualization of a pleural effusion in two cases. The mediastinal origins of the masses were confirmed by the location and independent movement of the lungs, i.e., the lungs slid over the masses. Access through the entrance of the thorax enabled the visualization of the masses in the topographical area of the sternal lymph node with the following features: heterogeneous echogenicity and echotexture, irregular margins, calcifications forming an acoustic shadow. The masses were able

to be evaluated by Power Doppler, revealing mottled central vascularization (Figure 3), consistent with a malignant lesion, as previously discussed.

In cases of radiographic findings suggestive of pulmonary consolidation, the ultrasound showed: loss of the reverberation artifact, hypoechoic lung tissue, hyperechoic trabeculations with anechoic content (fluid bronchograms or vessels) and hyperechoic spots with formation of a comet tail (residual air). These ultrasound characteristics corroborated RADEMACHER et al. (2014). The differentiation of fluid bronchograms and small pulmonary vessels was possible by Doppler evaluation. Fluid bronchograms, unlike vessels, are not pulsatile. However, the visualization of vessels or fluid bronchograms indicates pulmonary consolidation because none of these are visualized in normal aerated lung (Figure 4).

The ultrasound findings of three animals were confirmed by necropsy. In other words, the

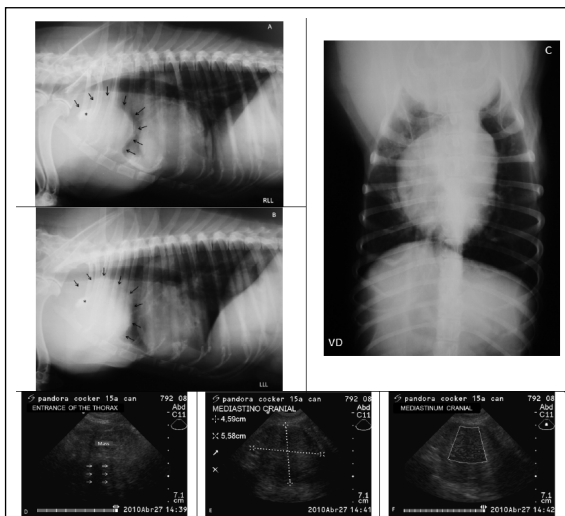


Figure 3 - Radiographic and ultrasound examinations of a 15-year-old female Cocker. Radiographic examination (Figures 3A, B and C) shows a mass measuring approximately 6 cm in diameter (arrows) in the region of the sternal lymph node. There is an area of focal calcification (*) in the mass. The B-mode ultrasound examination (Figure D), viewed from the entrance of the thorax, demonstrates a mass with heterogeneous echogenicity and echotexture. The mass has irregular borders and is in the area of the sternal lymph nodes, demonstrates calcifications dispersed throughout the tissue and forms an acoustic shadow (white arrows). The same mass is visualized at the lateral edge of the thorax (Figure E). Power Doppler evaluation shows a mottled central vascularization pattern (Figure F).

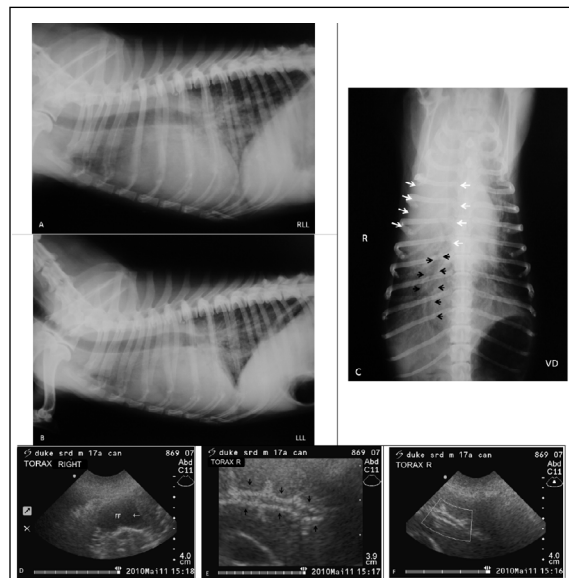


Figure 4 - Radiographic and ultrasound examinations of a 17-year-old male mixed breed dog. Radiographic examination (Figures A, B and C) shows an alveolar pattern in the cranial lung lobe overlapping the cardiac silhouette on the laterolateral projections (RLL and LLL). The ventrodorsal projection (VD) shows consolidation in the right lung lobe (white arrows) and air bronchograms (black arrows). B-mode ultrasound examination (Figures D and E) shows a small quantity of free fluid (FF) in the pleural space in the right hemithorax. Note the echogenic right lung lobe (consolidation) with the presence of fluid bronchograms (black arrows). The Doppler ultrasound examination (Figure F) confirms that the structure with hyperechoic borders is a fluid bronchogram rather than a vessel.

ultrasound examination was valuable for diagnosing these animals. In two animals, the ultrasound image was not capable of providing a precise diagnosis because additional alterations were visualized only after necropsy, thereby demonstrating the limitations of this imaging method. In one animal, the ultrasound image was not capable of precisely identifying the structure, which was only visualized after necropsy.

CONCLUSION

Radiographic examination should be conducted prior to an ultrasound to identify the location of an acoustic window. When nodules are dispersed throughout the thorax, the radiographic examination is superior to ultrasound. This study shows that ultrasound of the thorax should be adopted in a routine veterinary clinic because the

examination provides important clinical information. Additionally, the patient can be evaluated without excessive manipulation.

BIOETHICS AND BIOSSECURITY COMMITTEE APPROVAL

The project was certified by the Ethics Committee and Biosafety of DVT / UFV. Protocol N° 82/2007.

ACKNOWLEDGMENTS

To the Fundação de Amparo à Pesquisa do Estado de Minas Gerais (FAPEMIG) by the granting master's scholarship to the first author. To the Fundação Arthur Bernardes (FUNARBE) da Universidade Federal de Viçosa (UFV) for the granting to the second author (leader) (138/09).

REFERENCES

- CHAMMAS, M. C. et al. Lesões focais/tumores. In: CHAMMAS, M.C, CERRI, G. G. **Ultrassonografia abdominal**. 2. ed. Rio de Janeiro: Revinter, 2009. Cap. 3, p.154-215.
- FAUSTO, C.S.C.V; CHAMMAS, M.C. Doenças Infeciosas. In: CHAMMAS, M.C; CERRI, G.G. **Ultrassonografia abdominal**. 2nd ed. Rio de Janeiro: Revinter, 2009. p.78-80.
- LARSON, M. M. Ultrasound of the Thorax (Noncardiac). **Veterinary Clinics of North America: Small Animal Practice**, v.39, n.4, p.733-745, 2009. Available from: <<http://www.ncbi.nlm.nih.gov/pubmed/19531398>>. Accessed: Apr. 25, 2013. doi: 10.1016/j.cvsm.2009.04.006.
- MATTOON, J.S.; NYLAND, T.G. Tórax. In: NYLAND, T.G; MATTOON, J.S. **Ultrassom Diagnóstico em Pequenos Animais**. 2. ed. São Paulo: Rocca, 2005. p. 337-364.
- MYER, W. Radiography review: the interstitial pattern of pulmonary disease. **Veterinary Radiology**, v.21, n.1, p.18-23, 1980. Available from: <<http://onlinelibrary.wiley.com/doi/10.1111/j.1740-8261.1980.tb01345.x/abstract>>. Accessed: Feb. 08, 2013. doi:10.1111/j.1740-8261.1980.tb01345.x.
- PAULINELLI, R. R. et al. Estudo Prospectivo das Características Sonográficas no Diagnóstico de Nódulos Sólidos da Mama. **Revista Brasileira de Ginecologia e Obstetria**, v.24, n.3, p.195-199, 2002. Available from: <<http://www.scielo.br/pdf/rbgo/v24n3/a08v24n3.pdf>>. Accessed: Apr. 02, 2013. doi:10.1590/S0100-72032002000300008.
- RADEMACHER, N. et al. Transthoracic lung ultrasound in normal dogs and dogs with cardiogenic pulmonary edema: a pilot study. **Veterinary Radiology & Ultrasound**, v.55, n.4, p.447-452, 2014. Available from: <<http://onlinelibrary.wiley.com/doi/10.1111/vru.12151/pdf>>. Accessed: Jan. 30, 2015. doi:10.1111/vru.12151.
- REICHLE, J.K; WISNER, E.R. Non-cardiac thoracic ultrasound in 75 feline and canine patients. **Veterinary Radiology & Ultrasound**, v.41(2), p.154-162, 2000. Available from: <<http://onlinelibrary.wiley.com/doi/10.1111/j.1740-8261.2000.tb01470.x/abstract>>. Accessed: Feb. 02, 2013. doi:10.1111/j.1740-8261.2000.tb01470.x.
- SCHWARZ, L. A.; TIDWELL, A. S. Alternative imaging of the lung. **Clinical Techniques in small Animal**, v.14, n.4, p.187-206, 1999. Available from: <<http://www.ncbi.nlm.nih.gov/pubmed/10652836>>. Accessed: Apr. 02, 2013. doi:10.1016/S1096-28679980011-5.
- SPERANDEO, M. et al. Role of thoracic ultrasound in the assessment of pleural and pulmonary diseases. **Journal of Ultrasound**, v.11, n. 2, p. 39-46, 2008. Available from: <<http://www.ncbi.nlm.nih.gov/pubmed/23396553>>. Accessed: Apr. 22, 2013. doi:10.1016/j.jus.2008.02.001.
- TIDWELL, A. S. Ultrasonography of the thorax (excluding the heart). **Veterinary Clinics of North America: small animal practice**, v.28, n.4, p.993-1015, 1998. Available from: <<http://www.ncbi.nlm.nih.gov/pubmed/9698623>>. Accessed: Feb. 02, 2013.
- YANG, P.C. et al. Value of Sonography in Determining the Nature of Pleural Effusion: Analysis of 320 Cases. **American Journal of Roentgenology**, v. 159, n.1, p. 29-33, 1992. Available from: <<http://www.ajronline.org/cgi/reprint/159/1/29>>. Accessed: Apr. 22, 2013. doi:0361-803x/92/1591-0029.