

## Copaiba oil in experimental wound healing in horses

Flavia de Almeida Lucas<sup>1\*</sup> Adriana Lima Kandrotas<sup>1</sup> Eugenio Nardin Neto<sup>1</sup>  
Carlos Eduardo de Siqueira<sup>1</sup> Gabriela Santo André<sup>1</sup>  
Ingrid Bromerschenkel<sup>2</sup> Silvia Helena Venturoli Perri<sup>1</sup>

<sup>1</sup>Faculdade de Medicina Veterinária (FMVA), Universidade Estadual Paulista (UNESP), 16050-680, Araçatuba, SP, Brasil. E-mail: flavialucas@fmva.unesp.br. \*Corresponding author.

<sup>2</sup>Faculdade de Ciências Agrárias e Veterinárias (FCAV), Universidade Estadual Paulista (UNESP), Jaboticabal, SP, Brasil.

**ABSTRACT:** *The aim of this study was to evaluate the effects of 10% copaiba oil in experimentally induced wounds in horses. Four wounds were made in the lumbar and metacarpal regions of eight adult horses. In the treatment group, the wounds received 10% copaiba oil and in the control group 0.9% sodium chloride, in the daily dressing for 21 days. The wounds were evaluated three, 7, 14, and 21 days postoperatively. No significant differences were observed between the groups. The mean lumbar wound contraction rates were 80.54% and 69.64%, for the control and treated groups, respectively. For the wounds in the metacarpal region, these averages were 44.15% and 52.48%, respectively. Under the experimental conditions of the present study, it is concluded that 10% copaiba oil has beneficial in wound healing in the equine species and suggest that copaiba oil can be used as a therapeutic possibility in equine wound therapy.*

**Key words:** phytotherapy, wound healing, equine.

## Óleo de Copaíba na cicatrização de feridas experimentais em cavalos

**RESUMO:** *O objetivo deste estudo foi avaliar os efeitos do óleo de copaíba a 10% em feridas induzidas experimentalmente em equinos. Quatro feridas foram confeccionadas nas regiões lombares e metacarpianas de oito cavalos adultos. No grupo tratamento, as feridas receberam óleo de copaíba a 10% e no grupo controle, cloreto de sódio a 0,9% nos curativos diários durante 21 dias. As avaliações das feridas foram feitas aos 3, 7, 14, e 21 dias de pós-operatório. Não foram observadas diferenças significativas entre os grupos estudados. As médias das taxas de contração das feridas lombares foram 79,24% e 69,64%, para o grupo controle e tratado, respectivamente. Nas feridas do metacarpo, estas médias foram 44,78% e 52,05%, respectivamente. Nas condições experimentais deste estudo, conclui-se que o óleo de copaíba a 10% foi benéfico na cicatrização de feridas na espécie equina, sendo uma alternativa terapêutica para cura de feridas nesta espécie.*

**Palavras-chave:** fitoterapia, cicatrização de feridas, equinos.

## INTRODUCTION

Due to their active behavior and quick reactions, horses are predisposed to trauma, leading to skin lesions (PAGANELA et al., 2009). The most commonly affected areas are the distal regions of the members, including the carpus and tarsus and pectoral regions (WILMINK & VAN WEEREN, 2004), which suffer higher contamination and mobility as well as low shrinkage rates and blood supply related to the absence of a fleshy panicle, predisposing the formation of exuberant granulation tissue (TGE) (HENDRICKSON & VIRGIN, 2005; THEORET & WILMINK, 2013).

Approved by the FDA (Food and Drug Administration) in 1972, copaiba oil has been

recognized for its anti-inflammatory, antitumor, tetanus and urinary antiseptic effects, in the treatment of bronchitis, syphilis, skin diseases and ulcers as well as for wound healing (PAIVA et al., 2002; MONTES et al., 2009). PAIVA et al. (2002) reported the acceleration of wound contraction topically treated with this phytotherapeutic in rats. The efficiency of copaiba oil in the neoangiogenesis of skin flaps in rats was demonstrated by ESTEVÃO et al. (2009). In a skin ulcer model in rabbit ears (MASSON, 2011) and wound healing in rats (MASSON-MEYERS et al., 2013) at a concentration of 10%, stimulation of fibroplasia, reepithelization and remodeling were noted.

Able to stimulate cell proliferation *in vitro* (NOGUEIRA et al., 2012), copaiba oil does not

present mutagenic potential, being safe for topical use, yet possesses an antimicrobial effect on Gram-positive microorganisms (BRAGA & SILVA, 2008; MASSON, 2011; MASSON et al., 2013). Anti-inflammatory activity was also found in skin rats treated kaurenoic acid, a dipertene extracted from copaiba oil resin (SILVA et al., 2015).

The present study aimed to evaluate the clinical characteristics of topical application of 10% copaiba oil in experimentally induced wounds in the lumbar and dorsolateral metacarpal region of horses, verifying possible differences in healing between the regions.

## MATERIALS AND METHODS

Eight healthy, adult crossbred horses were used, four females and four males. The copaiba oil was formulated in the Pharmacy of Commercial Manipulation which has a good reputation and is well respected, in a solution containing 10% copaiba essential oil.

The animals were subjected to food and water fasting for 6 and 12 hours, respectively. They received xylazine hydrochloride<sup>a</sup> (0.5mg kg<sup>-1</sup>) intravenously and local anesthesia via infiltration, with lidocaine hydrochloride<sup>b</sup> 2% without any vasoconstrictor around the site to be incised. The lumbar region and lateral aspect of metacarpals were shaved and prepared aseptically using povidone iodine topical solution<sup>c</sup> 1% and 70% alcohol<sup>d</sup>. Four surgical wounds were made in each horse: two in the lumbar region, one cranial and the other caudal, spaced 10cm from each other, and two wounds in the dorsolateral region of the metacarpal bone, one proximal and one distal, spaced 8cm apart; the wounds were induced on the right in four horses and on the left in four horses, randomly. The depth of the excision included skin and subcutaneous tissue. After the surgery, all animals received phenylbutazone<sup>e</sup> (4.4 mg kg<sup>-1</sup>, intravenously) every 24 hours for 3 days to control pain and swelling.

All wounds were treated daily with 0.9% sterile saline solution<sup>f</sup>. Immediately thereafter, the wounds of the caudal lumbar and the metacarpal distal regions received copaiba oil, in sufficient quantities to cover the entire wound bed. After the daily dressing the wounds were covered with crepe bandages over sterile gauze. The evaluations were performed on the day of surgery and 3, 7, 14 and 21 days postoperatively (DPO) with observation of presented (local bleeding, presence of clots, scabs, granulation tissue, epithelialization and the presence of exudate), and objective alterations, with

photographic documentation and calculation of wound area and contraction rate. Measurement of the wound area was performed by determining the smallest and largest diameter of the wound using a universal caliper and the mathematical equation suggested by PRATA et al. (1988),  $A = \pi \times R \times r$ , where A represents the area, "R" the largest radius and "r" the smallest radius of the wound. The wound contraction rate was calculated using the equation proposed by RAMSEY et al. (1995): rate of contraction (%) =  $100 \times (F_0 - FA) / F_0$ , where F<sub>0</sub> represents the original area of the wound, shortly after its production and FA represents the area of the wound on the evaluation days (3, 7, 14 and 21 days of observation), always expressed as a percentage. The data of the areas were subjected to analysis of variance in subdivided parts with repeated measures for time and contraction rate of the wounds, followed by the Tukey's test for multiple comparisons of means. The data were tested for normality and homogeneity of variance, prerequisites for the analysis of variance. The statistics were considered significant when  $P < 0.05$ . Statistical analyzes were performed using the SAS program (Statistical Analysis System).

## RESULTS AND DISCUSSION

No clinical abnormality is associated with the surgically created wounds were noted throughout the study.

The square shape and size chosen for the induced wounds enabled evaluation over a sufficient period to observe the effects of 10% copaiba oil on the healing of equine skin. According to MADISON & GRONWALL (1992), in the equine species, the shape of the wound does not interfere with healing time. OLIVEIRA JR. et al. (2012) also used this model in their experimental study of wounds in horses.

Similarly to the work of OLIVEIRA JR. et al. (2012), the decision to apply the copaiba oil to the wounds in the caudal lumbar and distal metacarpal regions was made in order to avoid the control wounds, which did not receive treatment with oil, being contaminated during the healing, since, due to its low viscosity, the oil can drain into the adjacent wound, thus damaging the evaluations.

Non-steroidal anti-inflammatory phenylbutazone was used in the first three days after surgery to reduce pain associated with the surgical procedure in the same manner as it is routinely used in equine clinics. Any interference resulting from the systemic application of anti-inflammatory phenylbutazone would occur both in the control and

treated wounds. OLIVEIRA JR. et al. (2012) and MARTINS et al. (2013) also used phenylbutazone during the postoperative period in studies evaluating skin healing in the equine species.

Although phytotherapeutic products and associations (OLIVEIRA et al., 2012; RIBEIRO et al., 2013) have been used to treat skin lesions in horses, little research has been done to show any beneficial effects, and there have been no published reports of using copaiba oil in equine wound healing. In horses, SOUZA et al. (2003) described a period of 35 days for lumbar wound healing and 34 days for metacarpal wound healing when using *Triticum vulgare*. In other research involving phytotherapeutics in skin healing in horses, MARTINS et al. (2003) studied the influence of barbatimao (*Stryphnodendron barbatimao*), calendula (*Calendula officinalis*), and comfrey (*Symphytum officinale*). The authors reported a period of 21 days for barbatimao and comfrey, and a period of 26 days

for calendula to induce a contraction of lumbar wounds to a final area. In this research, the observation period of the research was 21 days, not enough to complete metacarpal and lumbar wound healing.

The concentration of copaiba oil chosen in this study was based on the studies of ESTEVÃO et al. (2009), MASSON (2011), ESTEVÃO et al. (2013) and MASSON-MEYERS et al. (2013) who presented satisfactory results in their studies using 10% copaiba oil-resin in the healing of rat skin. On the other hand, CAVALCANTI NETO et al. (2005), using pure oil-resin, observed delayed wound healing in rat skin, with a negative effect on the overall healing process of the wounds. GIESBRECHT (2011) used copaiba oil in an ointment at 1% for treatment of skin burns in rats and observed accelerated healing in the treatment group.

In this study, granulation tissue was observed earlier in the treated wounds compared with the controls, especially in the metacarpus (Figure 1). Granulation

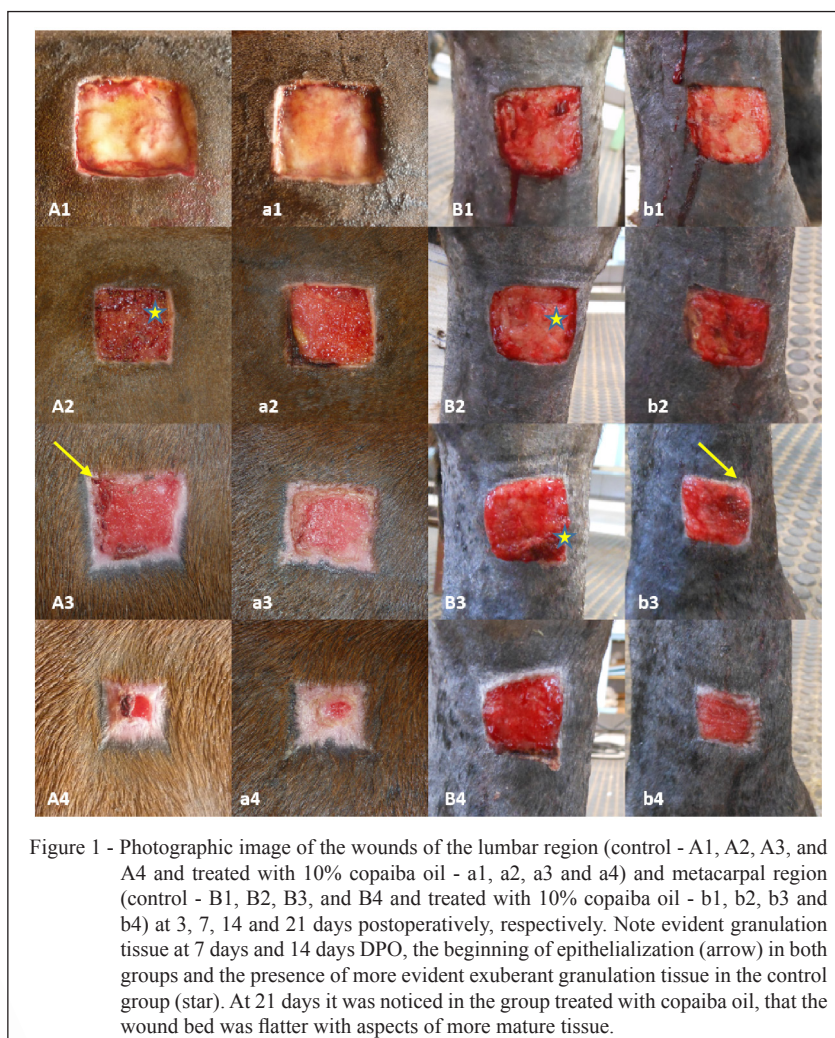


Figure 1 - Photographic image of the wounds of the lumbar region (control - A1, A2, A3, and A4 and treated with 10% copaiba oil - a1, a2, a3 and a4) and metacarpal region (control - B1, B2, B3, and B4 and treated with 10% copaiba oil - b1, b2, b3 and b4) at 3, 7, 14 and 21 days postoperatively, respectively. Note evident granulation tissue at 7 days and 14 days DPO, the beginning of epithelialization (arrow) in both groups and the presence of more evident exuberant granulation tissue in the control group (star). At 21 days it was noticed in the group treated with copaiba oil, that the wound bed was flatter with aspects of more mature tissue.

tissue formation then occurs, with proliferation of fibroblasts and the formation of few blood vessels which peaks around day 7 after surgical wounding (PAIVA et al., 2002). Epithelialization was observed on the 14<sup>th</sup> DPO also evident in the treated group. This suggests that topical use of copaiba oil possibly accelerated the cicatricial process while promoting a faster formation of granulation tissue, as has been described by ESTEVÃO et al. (2009) and ESTEVÃO et al. (2013) in wound healing with copaiba oil 10% in rat skin and MASSON (2011) in a skin ulcer model in rabbit ears.

The mean values for the lumbar wound area through the experimental period are represented in figure 2A. An increase in area on the 3<sup>rd</sup> DPO, both in the control and treated animals are noticed. On the 7<sup>th</sup> DPO, the wounds in the control group presented decreases in wound area while the wounds in the group treated with copaiba oil continued to demonstrate elevated areas. In both groups, there was a gradual reduction in the wound areas from the 7<sup>th</sup> DPO. COELHO et al., (1999) and MARTINS et al. (2013) also observed an increase in the areas of the wounds in the initial phase of the healing process, caused by the shrinkage of the rim of the lesions due to the action of the lines of tension (Langer Lines). In making the square wounds, the skin was incised in both directions, longitudinal and transversal, determining the increase in area due to stretching caused by the transverse incisions according to Langer's lines (ALGOWER, 1977 apud COELHO et al., 1999). GIESBRECHT (2011) observed a reduction in the areas of rat dorsal wounds receiving treatment with 1% copaiba oil ointment in rats. However, for the wounds in the metacarpal region, as illustrated in figure 2B, the control group presented increased wound areas until the 7<sup>th</sup> DPO, whereas, the wounds receiving copaiba oil presented decreased average areas in the first three days, with discrete increases until seven days.

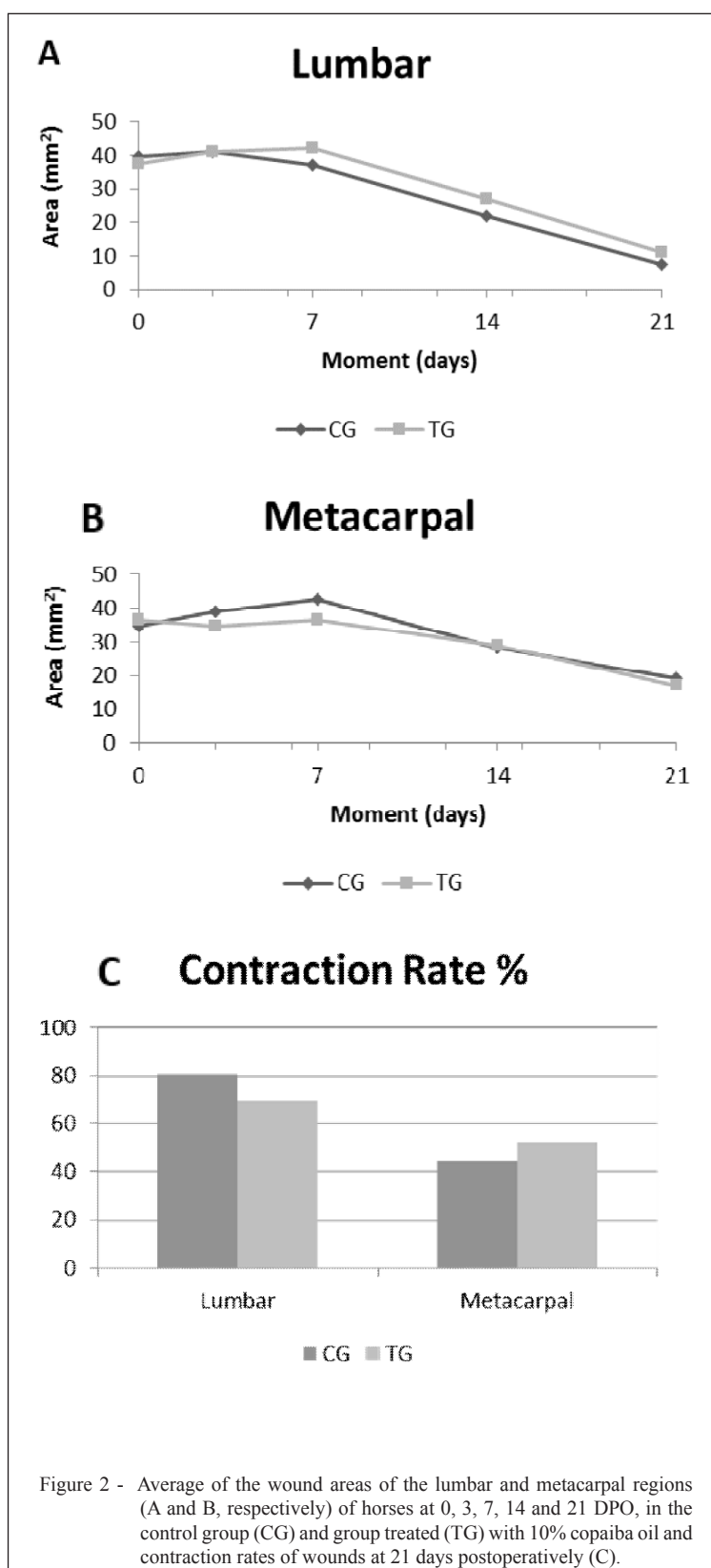
At 21 days postoperatively, the mean lumbar wound contraction rates were 80.54% and 69.64% for the control and treated groups respectively. In the wounds of the metacarpal, although not statistically different, higher mean contraction rates were observed in the group treated with copaiba oil (52.48%) compared to the control group (44.15%), similar to the study by suggesting a beneficial effect of copaiba oil on wound healing in this region (Figure 2C). It has been suggested that the common factor in wound contraction is the activity of fibroblasts (myofibroblasts) that are found in the granulation tissue of healing wounds (PAIVA et al, 2002). Several phytoconstituents present in the copaiba oleo-resin

such as diterpenes, and or the presence of some unknown growth factors such as transformation growth factor – that promote collagen formation (PAIVA et al., 2002), might have contributed to early wound contraction. The average contraction rate of the wounds at 21 DPO were significantly different between the metacarpal and lumbar regions; the lumbar region presenting a higher contraction rate in this period in both groups (Figure 2). The difference in the speed of healing between lumbar and metacarpal wounds in this study was expected, as it has been shown that lumbar wounds undergo a faster healing process, with a higher centripetal contraction, thinner granulation tissue, and a faster formation of crusts compared with metacarpal wounds (JACOBS et al., 1984; WHITE, 1995). According to JACOBS et al. (1984) and WILMINK et al. (1999), the delay in wound healing in distal regions of the limbs when compared with the trunk in the equine species, is due to a long healing phase, characterized by large retraction of the wound, low rates of epithelialization and early termination of wound contraction. BERRY & SULLINS (2003) state that lower blood supply, oxygen tension and temperature in addition to the presence of insufficient quantities of cytokines, determine the different patterns of healing between the different anatomical regions of the horse. According to RAMSEY et al. (1995), wound contraction is enhanced in areas where the skin is looser and more mobile, such as the skin of the trunk, which explains the occurrence in the present study. Faster healing in the lumbar region, when compared to the metacarpal region, was also observed in the study of OLIVEIRA JR. et al. (2012) who studied the effects of sunflower oil on experimental skin wounds in horses.

Although not presenting significant differences in clinical evaluation, it was possible to note a greater healing aspect in wounds receiving treatment with 10% copaiba oil, particularly in the wounds of the metacarpal region.

## CONCLUSION

Under the experimental conditions of the present study, it is concluded that 10% copaiba oil has beneficial in wound healing in the equine species and suggest that copaiba oil can be used as a therapeutic possibility in equine wound therapy. Furthermore, additional studies are required to determine the effects of this oil on different stages of healing in addition to investigations into the optimal concentration for topical use and histopathological evaluations.



## BIOETHICS AND BIOSSECURITY COMMITTEE APPROVAL

The present project was approved by the Ethics Committee on the use of animals FOA 00120-2013.

## SOURCES OF MATERIALS

- <sup>a</sup>Sedomin – Laboratórios König S.A. – Santana do Parnaíba – SP.  
<sup>b</sup>Lidocaine Hydrochloride 2% - Hipolabor Farmacêutica – Sabará - MG.  
<sup>c</sup>Riodeine – Rioquímica Indústria Farmacêutica – São José do Rio Preto – SP.  
<sup>d</sup>Álcool BM Ciclo Hospitalar – Ciclo Farma Indústria Química – Serrana – SP.  
<sup>e</sup>Phenylbutazone OF – Ourofino Saúde Animal – Cravinhos - SP  
<sup>f</sup>Sodium chloride 0.9% – Laboratório Sanobiol – Pouso Alegre – MG.

## REFERENCES

- BERRY II, D. B.; SULLINS, K. E. Effects of topical application of antimicrobials and bandaging on healing and granulation tissue formation in wounds of the distal aspect of the limbs in horses. **Am. J. Vet. Res.**, v.64, n.1, p.88-92, 2003. Available from: <http://avmajournals.avma.org/loi/ajvr>. Accessed: 07. Mar, 2013. doi: 10.2460/ajvr.2003.64.88.
- BRAGA, M. D.; SILVA, C. C. M. Atividade antimicrobiana do extrato aquoso de *Copaifera langsdorffii* Desf. sobre *Staphylococcus aureus*. **Unimontes. Cient.**, v. 9, n. 1, p. pág. 91-98, 2008. Available from: <http://www.ruc.unimontes.br/index.php/unicientifica/article/view/302>. Accessed: Nov. 23, 2014.
- CAVALCANTE NETO, A. T. et al. Análise comparativa entre o óleo-resina de copaíba e o digluconato de clorexidina no processo de cicatrização tecidual. Estudo histológico em dorso de ratos. **Rev. de Odont. da UNESP**, v. 34, n.2, p 107-112, 2005. Available from: <http://www.revodontolunesp.com.br/files/v34n2/v34n2a09.pdf>. Accessed: Jan. 2, 2017.
- COELHO, M. C. O. et al. Contração de feridas após cobertura com substitutos temporários de pele. **Ciência Rural**, v. 29, n. 2, p. 297-303, 1999. Available from: <http://www.scielo.br/scielo.php?script=sci\_arttext&pid=S01038478199900200018&lng=pt&nrm=iso>. Accessed: Aug. 08, 2014. doi: 10.1590/S0103-8478199900200018.
- ESTEVÃO, L. R.M. et al. Neoangiogênese de retalhos cutâneos em ratos tratados com óleo de copaíba. **Pesq. Agrop. Bras.**, v.44, n.4,p.406-412, 2009. Available from: <http://www.scielo.br/scielo.php?script=sci\_arttext&pid=S0100204X2009000400011&lng=en&nrm=iso>. Accessed: May. 24, 2013. doi: 10.1590/S0100-204X2009000400011.
- ESTEVÃO, L. R. M. et al. Effects of the topical administration of copaiba oil ointment (*Copaifera langsdorffii*) in skin flaps viability of rats. **Acta Cir. Bras.**, vol. 28, n 12, p. 863-869, 2013. Available from: <http://www.scielo.br/scielo.php?script=sci\_arttext&pid=S0102-86502013001200009> Accessed: May. 10, 2015. doi: 10.1590/S0102-86502013001200009.
- GIESBRECHT, P. C. P. **Efeitos da pomada de óleo de copaíba em queimadura cutânea em rato**. 2011. 62f. Dissertação (Mestrado em Ciência Animal) Universidade de Vila Velha, ES.
- HENDRICKSON, D.; VIRGIN, J. Factors that affect equine wound repair. **Vet. Clin. North Amer: Equine Pract.**, v.21, n. 1, p. 33-44, 2005. Available from: <http://www.vetequine.theclinics.com/article/S0749-0739(04)00083-5/pdf>. Accessed: Mar. 07, 2013. doi:10.1016/j.cveq.2004.11.002.
- JACOBS, K.A. et al. Comparative aspects of the healing of excisional wounds on the leg and body of horses. **Vet. Surg.**, v.13, n.2, p.83-90, 1984. Available from: <http://onlinelibrary.wiley.com/doi/10.1111/j.1532-950X.1984.tb00765.x/full>. Accessed: Mar. 7, 2013. doi: 10.1111/j.1532-950X.1984.tb00765.x.
- MADISON, J.B.; GRONWALL, R.R. Influence of wound shape on wound contraction in horses. **Am. J. Vet. Res.**, v.53, n.9, p.1575-1578, 1992. Available from: <http://www.ncbi.nlm.nih.gov/pubmed/1416358>. Accessed: Mar. 7, 2013.
- MARTINS, P.S. et al. Comparação entre fitoterápicos de uso tópico na cicatrização de pele em equinos. **Archives of Vet. Sci.** v.8, n.2, p.1-7, 2003. Available from: <http://revistas.ufpr.br/veterinary/article/view/4026/3257>. Accessed: May. 25, 2014.
- MARTINS, E. A. et al. Emprego da membrana de quitosana em feridas cutâneas induzidas experimentalmente em equinos. **Ciênc. Rural**, v.43, n.10, p.1824-1830, 2013. Available from: <http://www.scielo.br/scielo.php?script=sci\_arttext&pid=S0103-84782013001000015>. Accessed: 09 set. 2015. doi: 10.1590/S0103-84782013001000015.
- MASSON, D.S. **Atividades cicatrizante e antimicrobiana do óleo-resina de copaíba (*Copaifera langsdorffii*) em úlceras cutâneas**. 2011. 215f. Tese (Doutorado em Ciências Médicas) Faculdade de Medicina, USP, Ribeirão Preto, SP.
- MASSON, D. S. et al. Atividade antimicrobiana do óleo-resina de copaíba (*Copaifera langsdorffii*) em bactérias de significância clínica em úlceras cutâneas. **Rev. Bras. Pl. Med.**, v. 15, n. 4 supl. I, p. 664-669, 2013. Available from: <http://www.scielo.br/pdf/rbpm/v15n4s1/06.pdf>. Accessed: Aug. 10, 2015.
- MASSON-MEYERS, D. et al. Topical treatment with *Copaifera langsdorffii* oleoresine improves wound healing in rats. **International Journal of Phytomedicine**, v. 5, n.3, p. 378-386, 2013. Available from: <http://www.arjournals.org/index.php/ijpm/article/view/1248/671>. Accessed: Sept. 12, 2015.
- MONTES, L.V. et al. Evidências para o uso da óleo-resina de copaíba na cicatrização de ferida – uma revisão sistemática. **Natureza on line**, v.7, n.2, p.61-67, 2009. Available from: <http://www.naturezaonline.com.br/natureza/conteudo/pdf/02\_monteslvetal\_6167.pdf>. Accessed: Jan. 12, 2014.
- NOGUEIRA, E.O. et al. Avaliação do efeito do óleo de copaíba (*Copaifera* sp.) na proliferação celular *in vitro*. **Braz. J. Vet. Res. Anim. Sci**, v.49, n.4, p. 293-300, 2012. ISSN 1678-4456. Available from: <http://www.revistas.usp.br/bjvras/article/view/51714>. Accessed: Set. 9, 2015. doi:10.11606/issn.1678-4456.v49i4p293-300.
- OLIVEIRA JR., L.A.T. et al. Effects of topical application of Sunflower-Seed oil on experimentally induced wounds in horses. **J. of Equine Vet. Sci**, v. 32, p. 139-145, 2012. Available from: <http://www.sciencedirect.com/science/article/pii/S0737080611004709>. Accessed: Apr. 10, 2015. doi: 10.1016/j.jevs.2011.08.006.
- PAGANELA, J.C. et al. Abordagem clínica de feridas cutâneas em equinos. **Rev. Port. de Ciênc. Vet.**, v.104, p. 13-18, 2009. Available

from: <[http://www.fmv.ulisboa.pt/spcv/PDF/pdf12\\_2009/13-18.pdf](http://www.fmv.ulisboa.pt/spcv/PDF/pdf12_2009/13-18.pdf)>. Accessed: Aug. 3, 2015.

PAIVA, L.A.F. et al. Investigation on the wound healing activity of oleoresin from *Copaifera langsdorffi* in rats. **Phytotherapy Res.**, v. 16, n. 8, p. 737-739, 2002. Available from: <<http://onlinelibrary.wiley.com/doi/10.1002/ptr.1049/epdf>>. Accessed: Oct. 26, 2015. doi: 10.1002/ptr.1049.

PRATA M., et al. Uso tópico do açúcar em ferida cutânea: estudo experimental em ratos. **Acta Cir. Bras.**, v.3, p.43-8, 1988. Available from: <<http://bases.bireme.br/cgi-bin/wxislind.exe/iah/online/?IscScript=iah/iah.xis&src=google&base=LILACS&lang=p&nextAction=lnk&exprSearch=73664&indexSearch=ID>>. Accessed: Jan. 02, 2017.

RAMSEY, D. et al. Effects of three occlusive dressing materials on healing of full-thickness skin wounds in dogs. **Am J Vet Res**, v.56, n.7, p.941-949, 1995. Available from: <<https://www.ncbi.nlm.nih.gov/labs/articles/7574165/>>. Accessed: Feb. 10, 2014.

RIBEIRO, G. et al. Associação fitoterápica no tratamento de feridas cutâneas induzidas em equinos. **Arq. Bras. de Med. Vet. e Zootec.**, p. 1427-1433, 2013. Available from: <[http://www.scielo.br/scielo.php?script=sci\\_arttext&pid=S0102-09352013000500022](http://www.scielo.br/scielo.php?script=sci_arttext&pid=S0102-09352013000500022)>. Accessed: Jan. 2, 2017. doi: 10.1590/S0102-09352013000500022.

SILVA, J. J. L. et al. Effects of kaurenoic acid and arginine on random skin flap oxidative stress, inflammation, and cytokines in rats. **Aesthetic**

**Plast. Surg.**, v. 37, p. 971-977, 2015. Available from: <<https://www.ncbi.nlm.nih.gov/pubmed/26408387>>. Accessed: Jul. 27, 2015.

SOUZA, D. W. et al. Ensaio da aplicação de creme à base de Triticum vulgare na cicatrização de feridas cutâneas induzidas em equinos. **Rev. Bras. de Pl. Med.**, v.8, n.3, p.9-13, 2006. Available from: <[http://www.sbpmed.org.br/download/issn\\_06\\_2/artigo2\\_v8\\_n3.pdf](http://www.sbpmed.org.br/download/issn_06_2/artigo2_v8_n3.pdf)>. Accessed: Aug. 31, 2014.

THEORET, C. L.; WILMINK, J. M. Aberrant wound healing in the horse: Naturally occurring conditions reminiscent of those observed in man. **Wound Rep. and Reg.**, v. 21, n. 3, p. 365-371, 2013. Available from: <<http://onlinelibrary.wiley.com/doi/10.1111/wrr.12018/epdf>>. Accessed: Sept. 8, 2015. doi: 10.1111/wrr.12018.

WILMINK J.M., VAN WEEREN P.R. Differences in wound healing between horses and ponies: application of research results to the clinical approach of equine wounds. **Clin. Tech. Equine Pract.**, v.3, p. 1123-33, 2004. Available from: <<http://www.sciencedirect.com/science/article/pii/S1534751604000502>>. Accessed: Sept. 8, 2015. doi: 10.1053/j.ctep.2004.08.011.

WILMINK, J. M. et al. Differences in second-intention wound healing between horses and ponies: histological aspects. **Equine Vet. J.**, v. 31, n. 1, p. 61-67, 1999. ISSN 2042-3306. Available from: <<http://onlinelibrary.wiley.com/doi/10.1111/j.2042-3306.1999.tb03792.x/full>>. Accessed: Mar. 7, 2015. doi: 10.1111/j.2042-3306.1999.tb03791.x.