

## Equine nasopharyngeal cryptococcoma due to *Cryptococcus gattii*

Raquel Aparecida Sales da Cruz<sup>1\*</sup> Matheus de Oliveira Reis<sup>1</sup> Ronaldo Viana Leite Filho<sup>1</sup>  
Maiara Aline Gonçalves<sup>1</sup> Andréia Spanemberg<sup>2</sup> Luciana Sonne<sup>1</sup> Laerte Ferreiro<sup>2</sup>  
Saulo Petinatti Pavarini<sup>1</sup> David Driemeier<sup>1</sup>

<sup>1</sup>Setor de Patologia Veterinária (SPV), Universidade Federal do Rio Grande do Sul (UFRGS), Av. Bento Gonçalves, 9090, 91540-000, Porto Alegre, RS, Brasil. E-mail: [davetpat@ufrgs.br](mailto:davetpat@ufrgs.br). \*Corresponding author.

<sup>2</sup>Setor de Micologia, Universidade Federal do Rio Grande do Sul (UFRGS), Porto Alegre, RS, Brasil.

**ABSTRACT:** *Cryptococcus gattii* is often associated with pulmonary and systemic infections in humans and animals. In this research we report a case of nasopharyngeal cryptococcoma caused by *C. gattii* in an equine. A 10-year-old mare presented a mass obstructing the oropharynx. Macroscopically the mass was asymmetric, and was attached to the ethmoidal sinuses and obstructed the oropharynx. Histopathological examination of the mass revealed multiple yeast cells ranging from spherical to oval, 4-8µm in diameter, with some of them showing narrow base polar budding. *Cryptococcus gattii* growth in mycological culture (Sabouraud Dextrose Agar) and was L-canavanine-glycine-bromothymol blue Agar positive. The molecular identification confirmed the isolate as *C. gattii* by means of the amplification of universal primers. *C. gattii* is considered an emerging fungal agent, as it affects human and animals and does not respond efficiently to commonly established treatments.

**Key words:** mycotic diseases, cryptococcosis, equine, PCR, *Cryptococcus gattii*.

## Criptocoma nasofaríngeo equino devido a *Cryptococcus gattii*

**RESUMO:** *Cryptococcus gattii* é frequentemente associada a infecções pulmonares e sistêmicas em humanos e animais. Neste relato descreve-se um caso de criptocoma nasofaríngeo por *C. gattii* em um equino. Uma égua de 10 anos, apresentou uma massa obstruindo a orofaringe. Macroscopicamente a massa era assimétrica, e estava aderida aos seios etmoidais obstruindo a orofaringe. O exame histopatológico da massa revelou múltiplas células leveduriformes variando de esféricas a ovais, de 4-8µm de diâmetro, com algumas delas apresentando brotação polar de base estreita. *Cryptococcus gattii* foi isolado na cultura micológica (Ágar sabouraud dextrose) e foi positivo no Ágar L-canavanina-glicina-azul de bromotimol. A identificação molecular confirmou o isolado como *C. gattii* por meio da amplificação de primers universais. O diagnóstico de criptocoma por *C. gattii* nasofaríngeo foi baseado nos sinais clínicos, achados macroscópicos, lesões histológicas, cultura micológica e Reação em Cadeia da Polimerase. O *C. gattii* é considerado um agente fúngico emergente, pois acometendo humanos e animais, não respondendo com eficiência aos tratamentos comumente estabelecidos.

**Palavras-chave:** doenças micóticas, criptococose, equídeos, PCR, *Cryptococcus gattii*.

Cryptococcosis is a fungal infection caused by genus *Cryptococcus*, that includes 10 species, being five species of the *Cryptococcus gattii* identified through phylogenetic analysis (LIU et al., 2012; HAGEN et al., 2015). *Cryptococcus neoformans* and *Cryptococcus gattii* are often associated with pulmonary and systemic infections in humans and animals (CHEN et al., 2014).

During the past two decades, several *C. gattii* sensu lato outbreaks have been reported, characterized as an emerging disease with great interest in public health. The main route of

transmission of *Cryptococcus* is from inhalation of infectious propagules by immunocompromised as well as immunocompetent animals (CHEN et al., 2014). Cryptococcosis in horses is associated mainly with lesions in the respiratory tract, central nervous system (CNS), and abortion. However, disseminated cryptococcosis is reported with involvement of several systems concomitantly (ZOPPA et al., 2008). This reported describes a case of equine nasopharyngeal cryptococcoma due to *C. gattii*.

A 10-year-old crossbred mare, belonging to a jockey club in Porto Alegre, state of the Rio

Grande do Sul, Brazil, initially manifested apathy, weight loss, dyspnoea, and dysphagia as well as abundant discharge from the left nostril composed of serum and exudate. On endoscopic examination, a mass obstructing the entry of the oropharynx was demonstrated. Due to poor prognosis the owner decided euthanasia. Only the head of the horse was sent for examination. A sagittal cross section through the cranium revealed an asymmetric mass adhered to the ethmoid sinuses in the nasal cavity, with a portion extending over 8.0cm to the nasal turbinate and another portion forming a rounded mass of 4.0cm in diameter obstructing the oropharynx. The mass had a slightly uneven surface, white solid cut surface with soft consistency, and moderately delimited by a yellow capsule (Figure 1A). Fragments of the mass were fixed in 10% neutral buffered formalin and processed routinely. Sections were stained by haematoxylin and eosin (HE), in addition to histochemical techniques of periodic acid-Schiff (PAS), Alcian blue (AB), as well Mayer's mucicarmine (MM).

Microscopic examination of the mass revealed multiple spherical to oval yeasts cells, 4-8µm in diameter, with some of them exhibiting narrow-based polar budding. A negatively stained capsule gives these cells the aspect of having a clear zone of variable thickness around them imparts a typical soap-bubble appearance to the histological sections. A slightly infiltrate that consisted predominantly of macrophages with abundant extracellular organisms, associated with moderate fibrosis, was also observed. There was no evidence of fungal infection of the brain. The capsule of the yeast was demonstrated on PAS (Figure 1B) staining which was further highlighted by MM stain (Figure 1C), imparting it a red color confirming that capsular polysaccharide was present. The polysaccharide capsule stained blue with AB stain (Figure 1D).

Tissue fragments were plated on Sabouraud Dextrose Agar with chloramphenicol and incubated at 30°C for 48h. In addition, the isolate was discriminated by a color reaction when grow on canavanine-glycine-bromothymol blue (CGB) agar. Reaction on CGB agar was considered positive after 48h of incubation. Morphologically, spherical to oval encapsulated yeast cells, budding on a narrow base range from 4-10µm in diameter. The CGB agar turned blue, characterizing the colonies as *C. gattii*.

The PureLink™ Genomic DNA Mini Kit (Invitrogen) was used for DNA extraction from the tissue fragment. DNA extracted was detected with panfungal PCR using ITS3-F (5'-GCATCGATGAAGAACGCAGC-3')

ITS4-R (5'-TCCTCCGCTTATTGATATGC-3'), which amplify the ITS1 and/or ITS2 regions of fungal rDNA genes (WHITE et al., 1990). PCR amplification was performed in a 25µL containing 1µL of DNA extract, 12.5µL Qiagen Taq PCR master mix (Qiagen, Hilden, Germany) and 0.5µL of each primer (for a 0.2µM final concentration of each primer). After a preincubation at 94°C for 15min, the amplification was performed for a total of 35 cycles as follows: denaturation at 94°C for 30s, annealing at 57°C for 90s, extension at 72°C for 1min, and a final extension step of 10min at 72°C. Primers ITS3 and ITS4 amplified a fragment of between 300 and 400bp. The amplification positive control included genomic DNA from *C. gattii*. PCR product was separated on a 2% agarose. PCR product was purified using PureLink™ PCR Purification Kit (Invitrogen), and sequencing to confirm the presence of fungal elements in the tissue sample.

The horse presented here showed clinical signs similar to those described in nasal cavity infections by *C. gattii* in cats and humans, which are characterized by apathy, anorexia, lethargy, and bilateral nasal discharge of serous to hemorrhagic aspect (MALIK et al., 1997; CHEN et al. 2014, KINNE et al., 2017). The difficulty in swallow and breath, observed here, is also reported in nasopharyngeal granulomas by *Cryptococcus* in other animal species (MALIK et al., 1997). There are several reports of cryptococcosis in horses affecting the CNS (CHO et al., 1986) and respiratory tract (ZOPPA et al., 2008). Equine nasal granulomas are rarely described, but two systemic equine cryptococcosis reports by *Cryptococcus* in Australia and Brazil have clinical and morphological finding, respectively, with characteristics similar to those reported in the case presented here. It is suggested that the mechanism of transmission was through the inhalation of fungus propagules (KOMMERS et al., 2005; ZOPPA et al., 2008).

*Cryptococcus* is yeast with thick mucopolysaccharide capsule that does not stain by Indian Ink and is seen as a clear halo, ranging from 1 to 30µm of thickness (CASWELL & WILLIAMS, 2016). Different other fungi like *Coccidioides* sp. which have oval structures measuring 20-200µm in diameter containing multiple intracellular endospores observed in HE stain. Besides of the *Rhinosporidium* sp., are observed spherical to polygonal structures of variable appearance measuring approximately 100-500µm filled with endospores measuring 3-5µm (BERROCAL et al., 2007, CASWELL & WILLIAMS, 2016). The PAS and AA stains

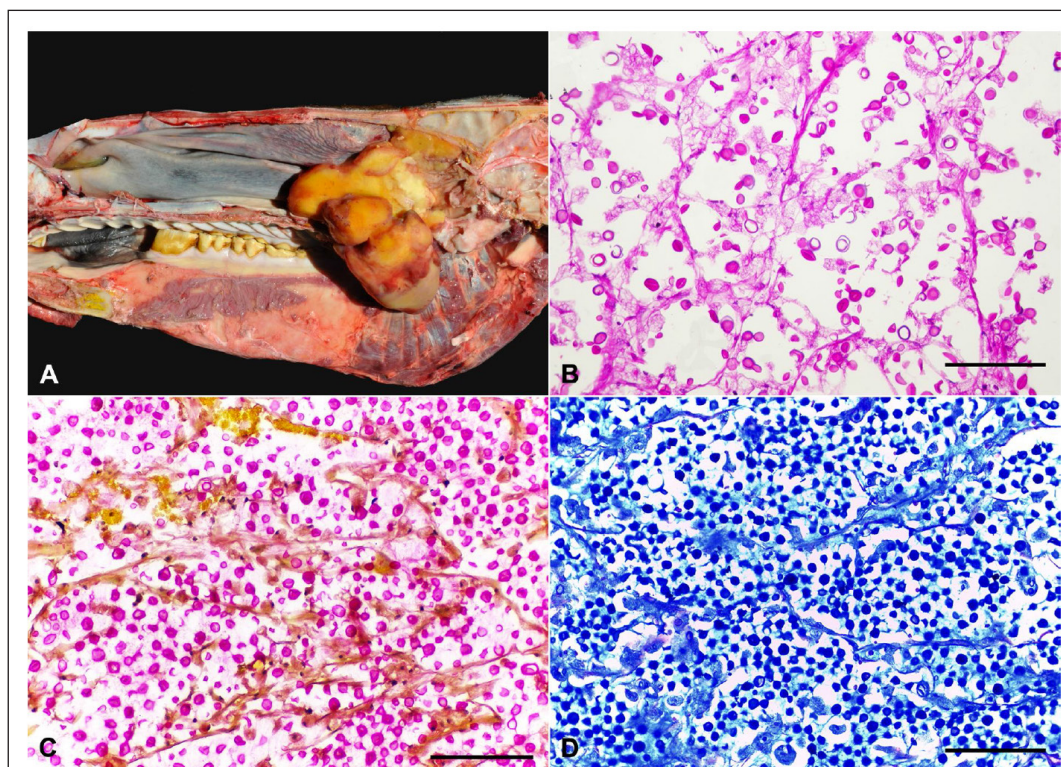


Figure 1 - (A) Sagittal cross section through the cranium revealed an asymmetric mass adhered to the ethmoid sinuses in the nasal cavity. (B) Multiple spherical to oval yeasts cells of *Cryptococcus gattii* shows unstained halo (mucopolysaccharidic capsule). (C) Cryptococcal organisms and the surrounding polysaccharide capsules stained pink with Mayer's mucicarmine stain. MM. (D) Cryptococcal organisms and the surrounding polysaccharide capsules stained blue with Alcian Blue stain. AB.

were applied to confirm the mucopolysaccharide capsule, consequently the yeast was uniformly positive by MM stain, except in cryptococcosis by nonencapsulated yeast-like organisms, in which the usual color appearance is absent. Inflammatory reaction seen is the histopathology examination of the case presented here, which demonstrated a well delimited mass with moderate fibrous stroma interspersed with a large quantity of yeast cells and slightly histiocytic infiltrate, being characterized as a cryptococcoma (SCHWARTZ, 1988). In vitro studies and experimental inoculations suggested that *C. gattii* is capable of inhibiting neutrophils migration, and that the metabolites produced by it has less pro-inflammatory capacity compared to *C. neoformans* (WRIGHT et al., 2002).

There are several reports of mass formation in the nasal cavity of horses related to fungal infections as *Conidiobolus* and *Coccidioides immitis*

(CASWELL & WILLIAMS, 2016), *Aspergillus* (GUIDA et al., 2005), *Rhinosporidium seeberi* (previously classified as a fungus) (LEEMING et al., 2007), in addition to formation of nasal polyps, ethmoid hematomas, and tumors (CASWELL & WILLIAMS, 2016). Clinical and microscopic findings are similar, so the histopathology and culture from a clinical sample are the standard reference tests for diagnosis of fungal infection. (GUARNER et al., 2011; BERROCAL et al., 2007).

Molecular methods for the differentiation of *C. neoformans* and *C. gattii* are needed when the conventional methodology (histopathology and culture) does not allow the correct identification. Similar methodology was performed in the outbreak by *C. gattii* in humans and animals occurred in Vancouver, Canada (GALANIS et al., 2009). In our study, although the *C. gattii* was CGB positive, PCR with primer panfungal was necessary to confirm

its identity, since is a valuable tool when used in conjunction with histopathology (the assay has the ability to identify fungi in tissue specimens) and culture in order to confirm fungal infections in animals. Thus, in some cases, such as differentiation of *Cryptococcus* species, it might be superior to culture alone; although, culture remains the standard reference test.

The determination of the species was important because infections by *C. gattii* are increasingly considered worrisome since this species is not susceptible to the most commonly used antifungal agents, which makes the treatment more difficult (TRILLES, 2004). In present case, the horse was euthanized after diagnosis of nasopharyngeal mass and there was no history of antifungal treatment.

Due to the fact that only the head of the mare was sent for analysis it was impossible to rule out the possibility of evaluation of disseminated cryptococcosis. To date there are no data regarding the occurrence of *C. gattii* infection in horses in this area as reported in this case. The diagnosis of severe injury by *C. gattii* in the case here presented and the various reports of infection in humans and animals characterized the *C. gattii* as an emerging fungal pathogen (LESTER et al., 2011, CHEN et al., 2014). So there is an awareness of the disease to the need for more accurate diagnostic investigation when suspected clinical manifestations. *C. gattii* should be included as one of the possible primary agents of granulomatous rhinitis in horses.

The diagnosis of equine nasopharyngeal cryptococcoma due to *Cryptococcus gattii* was confirmed based upon the gross and microscopical findings, combined with mycological and molecular assays.

## ACKNOWLEDGEMENTS

To Conselho Nacional de Desenvolvimento Científico e Tecnológico (CNPq) and Coordenação de Aperfeiçoamento de Nível Superior (CAPES).

## REFERENCES

- BERROCAL, A.; LÓPEZ, A. Nasal rhinosporidiosis in a mule. **Canadian Veterinary Journal**, v.48, n.3, p.305-306, 2007. Available from: <<https://www.ncbi.nlm.nih.gov/pmc/articles/PMC1800950>>. Accessed: Dec. 15, 2016.
- CASWELL, J.L.; WILLIAMS, K.J. Respiratory system. In: JUBB, KENNEDY, AND PALMER'S. **Pathology of domestic animals**. 6. ed. Saint Louis, MG Maxie, 2016. Cap.5, p.479.
- CHEN, S.C.A et al. *Cryptococcus gattii* infections. **Clinical Microbiology Reviews**, v.27, n.4, p.980-1024, 2014. Available from: <<https://www.ncbi.nlm.nih.gov/pubmed/25278580>>. Accessed: Dec. 17, 2016. doi: 10.1128/CMR.00126-13.
- CHO, D.Y. et al. Cerebral Cryptococcosis in a Horse. **Veterinary Pathology**, v.23, n.2, p.207-209, 1986. Available from: <<https://www.ncbi.nlm.nih.gov/pubmed/3962090>>. Accessed: Dec. 18, 2016. doi: 10.1177/030098588602300218.
- GALANIS, E. et al. Clinical presentation, diagnosis and management of *Cryptococcus gattii* cases: lessons learned from British Columbia. **Canadian Journal of Infectious Diseases and Medical Microbiology**, v.20, n.1, p.23-28, 2009. Available from: <<https://www.ncbi.nlm.nih.gov/pmc/articles/PMC2690522/>>. Accessed: Dec. 19, 2016.
- GUARNER, E; BRANDT, M.E. Histopathologic diagnosis of fungal infections in the 21st century. **Clinical Microbiology Reviews**, v.24, n.2, p-247-280, 2011. Available from: <<http://cmr.asm.org/content/24/2/247.full.pdf+html>>. Accessed: May 25, 2017. doi: 10.1128/CMR.00053-10.
- GUIDA, N. *Aspergillus fumigatus* in nasopharyngeal cavity of horses. **Revista Iberoamericana de Micología**, v.22, n.3, p.160-162, 2005. Available from: <<http://europepmc.org/abstract/med/16309352>>. Accessed: Dec. 19, 2016. doi: 10.1016/S1130-1406(05)70031-0.
- HAGEN, F. Recognition of seven species in the *Cryptococcus gattii/Cryptococcus neoformans* species complex. **Fungal and Genetics Biology**, v.78, p16-48, 2015. Available from: <<http://www.sciencedirect.com/science/article/pii/S1087184515000328>>. Accessed: May 25, 2017. doi: 10.1016/j.fgb.2015.02.009.
- KINNE, J. et al. Disseminated *Cryptococcus deuterogattii* (AFLP6/VGII) infection in an Arabian horse from Dubai, United Arab Emirates. **Revista Iberoamericana de Micología**, S1130-1406(17)30058-X, 2017. Available from: <<https://www.ncbi.nlm.nih.gov/pubmed/28595777>>. Accessed: June 14, 2017. doi: 10.1016/j.riam.2017.02.007.
- KOMMERS, D.G. et al. Granulomatous cryptococcal pneumonia in a horse. **Ciencia Rural**, v.35,p.938-940, 2005. Available from: <<http://dx.doi.org/10.1590/S0103-84782005000400032>>. Accessed: Dec. 20, 2016.
- LEEMING, G. et al. Equine Rhinosporidiosis in United Kingdom. **Emerging Infectious Diseases journal**, v.13, n.9, p.1377-1379, 2007. doi: 10.3201/eid1309.070532.
- LESTER, S.J. et al. Cryptococcosis: update and emergence of *Cryptococcus gattii*. **Veterinary Clinical Pathology**, v.40, n.1, p.4-17, 2011. Available from: <<https://www.ncbi.nlm.nih.gov/pubmed/21244455>>. Accessed: Dec. 20, 2016. doi: 10.1111/j.1939-165X.2010.00281.x.
- LIU, X.Z. et al. Towards an integrated phylogenetic classification of the Tremellomycetes. **Studies in Mycology**, v.85, p-85-147, 2015. Available from: <<http://www.sciencedirect.com/science/article/pii/S0166061615000275>>. Accessed: May 25, 2017. doi: 10.1016/j.simyco.2015.12.001.
- MALIK, R et al. Nasopharyngeal cryptococcosis. **Australian Veterinary Journal**, v.75, n.7, p.483-488, 1977. Available from: <<http://onlinelibrary.wiley.com/doi/10.1111/j.1751-0813.1997.tb14377.x>>. Accessed: Dec. 20, 2016. doi: 10.1111/j.1751-0813.1997.tb14377.x.

SCHWARTZ, D.A. Characterization of the biological activity of *Cryptococcus* infections in surgical pathology. The Budding Index and Carminophilic Index. **Annals of Clinical & Laboratory Science**, v.5, p.388-397, 1988. Available from: <<http://www.annclinlabsci.org/content/18/5/388.abstract>>. Accessed: Dec. 20, 2016.

TRILLES, L. et al. *In vitro* antifungal susceptibility of *Cryptococcus gattii*. **Journal of Clinical Microbiology**, v.42, n.10, p.4815-4817, 2004. Available from: <<https://www.ncbi.nlm.nih.gov/pmc/articles/PMC522305/>>. Accessed: Dec. 20, 2016. doi: 10.1128/JCM.42.10.4815-4817.2004.

WRIGHT, L. et al. Metabolites released by *Cryptococcus neoformans* var. *neoformans* and var. *gattii* differentially affect human neutrophil

function. **Microbes and Infection**, v.4, p.1427-1438, 2002. Available from: <<http://www.sciencedirect.com/science/article/pii/S1286457902000242>>. Accessed: Dec. 20, 2016.

WHITE, T.J. et al. Amplication and direct sequencing of fungal ribosomal RNA genes for phylogenetics. In: INNIS, M.A. et al. (Eds.). **PCR protocols: a guide to methods and applications**. San Diego, CA: Academic, 1990. p.315-322.

ZOPPA, A.L. et al. Nasal obstruction caused by fungal granuloma in a horse: case report. **Arquivo Brasileiro de Medicina Veterinária e Zootecnia**, v.60, n.2, p.315-321, 2008. Available from: <[http://www.scielo.br/scielo.php?script=sci\\_arttext&pid=S010209352008000200006](http://www.scielo.br/scielo.php?script=sci_arttext&pid=S010209352008000200006)>. Accessed: Dec. 20, 2017.