





Single incision laparoscopic surgery (SILS™) using an umbilical hernial approach for cryptorchidectomy of a degenerated testis in a dog

Caio de Faria Tiosso¹ Fabiana Azevedo Voorwald^{2*}  Maurício Veloso Brun³
Luciana Cristina Padilha Nakaghi¹ Roberta Martins Crivelaro¹ Maricy Apparicio¹ 
Wilter Ricardo Russiano Vicente¹

¹Faculdade de Ciências Agrárias e Veterinárias de Jaboticabal, Universidade Estadual Paulista (FCAV/UNESP), Jaboticabal, SP, Brasil.

²Departamento de Veterinária (DVT), Universidade Federal de Viçosa (UFV), 36570-900, Viçosa, MG, Brasil. E-mail: voorwald@gmail.com.

*Corresponding author.

³Universidade Federal de Santa Maria (UFSM), Santa Maria, RS, Brasil.

ABSTRACT: *SILS™ via an umbilical hernia opening was used in the correction of an abdominal cryptorchidism in a dog. The SILS™ port was inserted through a 2.5 cm skin incision on the umbilical hernia and pneumoperitoneum was established with CO₂. A 10mm telescope, 5mm laparoscopic Babcock clamp, and a clamp with combined cutting and coagulation features were used for the dissection and removal of the testicle through the SILS™ port. The treatment proved to be effective, easy, and quick to perform. However, the lack of triangulation between clamps and telescope limited the movement of the instruments, making it more laborious than a multiple-trocar approach. It can be concluded that the use of a SILS™ port through a pre-existing opening of the abdominal wall enables a reduction of the risks associated with multiple incisions; such as injury and manipulation of internal organs, pain, bleeding, and development of new hernias.*

Key words: *Single-port, laparoscopy, SILS, cryptorchidism, canine.*

Aplicação do portal único (SILS™) por acesso herniário umbilical para criptorquidectomia de testículo degenerado em cão

RESUMO: *Objetivou-se proceder um tratamento para um caso de criptorquidismo canino, utilizando-se abordagem laparoscópica com portal único SILS™, por meio de acesso abdominal via abertura de hérnia umbilical. Realizou-se uma incisão de 2,5 cm da pele em cima da hérnia umbilical, por onde introduziu-se trocater SILS™, seguido do estabelecimento do pneumoperitônio com CO₂. Utilizou-se ótica de 10mm, pinça laparoscópica de apreensão tipo Babcock de 5mm e pinça com corte e coagulação simultâneos para liberação e retirada do testículo e do trocater SILS™, pelo acesso herniário. O tratamento proposto mostrou-se efetivo, de execução relativamente fácil e rápida. Entretanto, a ausência de triangulação entre as pinças e a óptica resultou em maior limitação na movimentação dos instrumentais, em comparação ao procedimento realizado com utilização de múltiplos portais. Pode-se concluir que a utilização do trocater SILS™ em uma falha pré-existente da parede abdominal possibilita significativa redução dos riscos potenciais de múltiplas incisões, como lesão de órgãos internos, manipulação, dor, sangramento e formação de novas hérnias.*

Palavras-chave: *Portal único, laparoscopia, SILS, criptorquidismo, canina.*

INTRODUCTION

In dogs, testicular migration normally takes place within five days of birth; however, cryptorchidism occurs when one or both testes fail to move into the scrotum. Partial closure of the inguinal ring at 6 months hinders testicular migration to the scrotum, increasing the chances of retention within the abdominal cavity, inguinal, or pre-scrotal region (KAWAKAMI et al., 1993; JOHNSTON et al., 2001; YATES et al., 2003).

Due to their higher mobility, testicles retained in the abdomen are more prone to torsion

and 13.6 times more likely to become cancerous than those in the scrotum (YATES et al., 2003). Hypoplasia and degeneration of cryptorchid testes can also occur and are usually difficult to distinguish by morphology alone. However, these disorders frequently occur together, since hypoplastic testes tend to degenerate (ACLAND, 1998).

Mechanism behind cryptorchidism inheritance remains unknown and controversial, with polygenic and single autosomal recessive gene inheritance having been suggested (BURKE & REYNOLDS, 1993; YATES et al., 2003). The genetic nature, combined with

its high potential to form a tumour, make orchietomy the treatment of choice for cryptorchidism.

Orchietomy is one of the most common surgical procedures in veterinary medicine. However, a laparotomy becomes necessary when a testicle is retained in the abdominal cavity. Although, exploratory laparotomy remains widely used, laparoscopy has been a useful alternative in the diagnosis and treatment of abdominal testicle retention. Recently, different techniques have been developed and are being used in veterinary medicine such as NOTES (natural orifice transluminal endoscopic surgery), SILS™ (single incision laparoscopic surgery), and OPUS (one port umbilical surgery), with the aim of minimizing the potential morbidity associated with multiple incisions (TRACY et al., 2008; IRWIN et al., 2009).

Taking into account the benefits of laparoscopic surgery, single incision laparoscopic surgery (SILS™) was used for the abdominal cryptorchidism correction of a degenerated testicle in a dog via an umbilical hernia opening. To the best of the author's knowledge, this is the first description of SILS™ via an umbilical hernia in veterinary medicine.

A four-year old cross breed dog, weighing 20 kg, was referred for investigation of an umbilical hernia. According to the case history, the animal had undergone orchietomy two years prior and, at the time of surgery, only one testicle was present in the scrotum. On physical examination the heart and respiratory rate and rectal temperature were 160 beats per minute, 29 breaths per minute, and 38.9 °C; respectively. Furthermore, the presence of a 2.5 cm diameter umbilical hernia was observed (Figure 1A). Haematological evaluation and serum biochemical analysis (creatinine, urea, alanine aminotransferase, and albumin) were within the normal range for the species.

Ultrasonography of the umbilical hernia revealed the presence of the omentum and an intra-abdominal ultrasound showed a structure compatible with a testis, albeit with significantly altered echogenicity and size. Exploratory laparoscopy (SILS™) via the umbilical hernia was carried out to confirm the diagnosis.

Chlorpromazine (0.5 mg/kg intramuscular injection - IM) (Longactil® Cristália, Itapira-SP-Brazil) and morphine (0.5 mg/kg IM) (Dimorf®

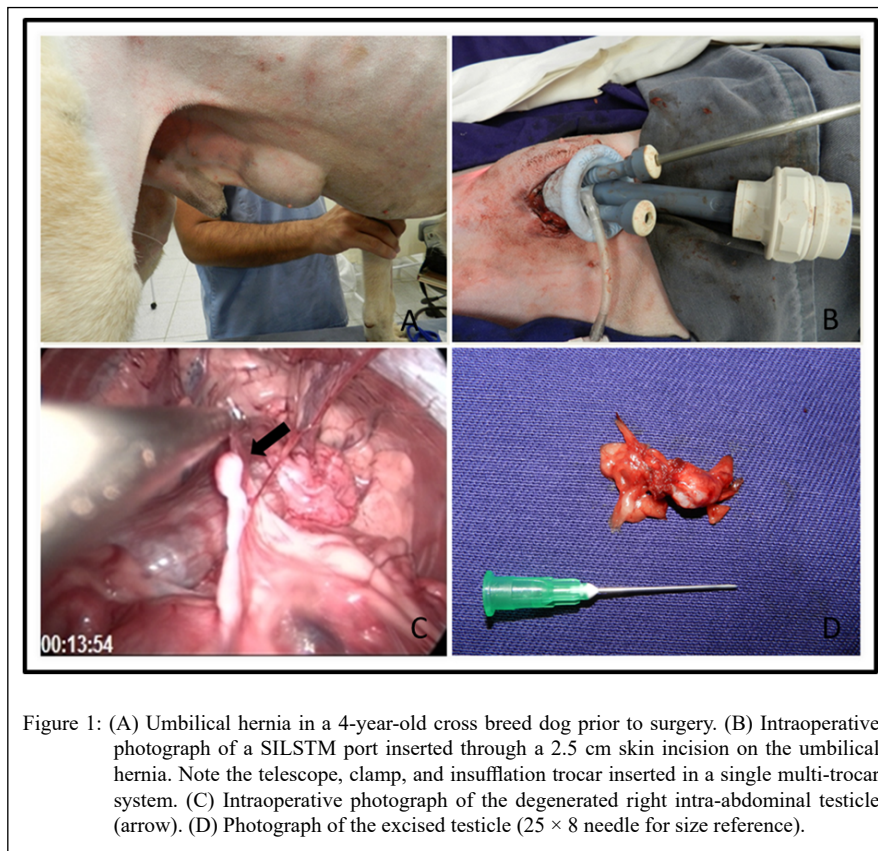


Figure 1: (A) Umbilical hernia in a 4-year-old cross breed dog prior to surgery. (B) Intraoperative photograph of a SILSTM port inserted through a 2.5 cm skin incision on the umbilical hernia. Note the telescope, clamp, and insufflation trocar inserted in a single multi-trocar system. (C) Intraoperative photograph of the degenerated right intra-abdominal testicle (arrow). (D) Photograph of the excised testicle (25 × 8 needle for size reference).

Cristália) were used as premedication. Anaesthesia was induced with intravenous propofol (3 mg/kg) (Propovan® Cristália) and maintained with isoflurane (Isoforine® Cristália) diluted in 100% O₂ at 30 mL/kg/min under a semi-closed anaesthetic circuit. Antimicrobial chemoprophylaxis was carried out after induction with 22000UI/kg of sodium penicillin, procaine, and benzathine (Mogipen Bimeda® mogivet, Monte Mor-SP-Brazil) given intramuscularly.

A single 2.5 cm long semi-circular supraumbilical skin incision was used for the SILS™ Port (Covidien; Norwalk, CT, USA). Pneumoperitoneum was established using a Veress needle insertion (VERESS, 1938) and CO₂ at 1.5 L/min, with a maximum intra-abdominal pressure of 12 mmHg (Figure 1B). The abdominal cavity was inspected using a 10 mm telescope and the intra-abdominal testis visualised in a location compatible with the sonographic image obtained (Figure 1C).

A 5 mm Babcock clamp was inserted through the umbilical trocar site to manipulate the testicle. A clamp, with combined cutting and coagulation functions, was used to cut and electrocauterize the pampiniform plexus, vas deferens, and internal cremaster muscle in order to release and remove the testicle via the SILS™ port (Figure 1D). Herniorrhaphy was performed using 2-0 poliglecaprone (Carprofyl® Ethicon, São José dos Campos-SP-Brazil), intradermal suture with 3-0 poliglecaprone 25 (Carprofyl® Ethicon) and the skin edges were opposed with simple interrupted suture using 3-0 nylon (Nylon® Ethicon). The dog recovered uneventfully from surgery. Ten days after the surgical procedure, the dog returned for skin suture removal, showing good surgical wound healing and no signs of hernia recurrence or local alterations.

Histopathological analysis of the intra-abdominal testicle indicated severe germ cell degeneration, atrophy of seminiferous tubule and increased connective tissue accumulations, characterising interstitial fibrosis.

Laparoscopic correction of the unilateral cryptorchidism using a SILS™ port via an umbilical hernia was effective, easy, and quick to perform (61.32 minutes total time) with no complications. Several studies have reported the use of laparoscopy as the surgical treatment for abdominal cryptorchidectomy; however, only one has reported using a SILS™ port for this type of procedure (RUNGE et al., 2014). In the study mentioned above, cryptorchidectomy was performed using three single port devices followed by an evaluation of the clinical outcome of the patients. The authors reported a median surgical time of 38

minutes, 20 minutes less than the present report. However, surgical time is likely to decrease with practice and experience.

BONJER et al. (1997) reported that the insufflation of the abdomen with a Veress access needle has been associated with a risk of injury to blood vessels and parenchymal and hollow organs. Since the animal in this case report had an umbilical hernia and the trocar already had an insufflation valve, the open technique was the approach of choice, since it facilitated the placement of the trocar and decreased the risk of iatrogenic lesions caused by the Veress needle.

Limitations observed with the use of a SILS™ port were mainly related to instrument manipulation. As multiport devices were not used, there was often contact between the camera and clamps. Other difficulties encountered were similar to those observed in other multiport laparoscopies, such as lack of tactile sensation, which can be overcome by practice and experience. Identification of the intra-abdominal testicle was challenging due to its reduced size; however, the presence of a telescope ensured the success of this approach.

The use of a SILS™ port for the cryptorchidectomy of an intra-abdominal degenerated testis via an umbilical hernia was unique. This report concludes that laparoscopic procedures facilitate the identification of degenerated testicles and that the use of a SILS™ port via a pre-existing opening of the abdominal wall (umbilical hernia) reduces the risks associated with multiple incisions, such as injury and excessive manipulation of internal organs, pain, bleeding, and development of new hernias.

ACKNOWLEDGEMENTS

The research was financed in part by the Coordenação de Aperfeiçoamento de Pessoal de Nível Superior (CAPES), Brasil – Finance code 001, and CFT had fellowships from FAPESP, Brasil, Finance code 2009/12698-7 and 2012/25061-0.

BIOETHICS AND BIOSSECURITY COMMITTEE APPROVAL

We authors of the article entitled “Single incision laparoscopic surgery (SILSTM) using an umbilical hernia approach for cryptorchidectomy of a degenerated testis in a dog” declared, for all due purposes, the project that gave rise to the present data of the same has not been submitted for evaluation to the Ethics Committee of the University /Research Institute “Faculdade de Ciências Agrárias e Veterinárias de Jaboticabal – FCAV/UNESP”, but we are aware of the content of the Brazilian resolutions of the National Council for Control of Animal Experimentation - CONCEA “<http://www.mct.gov.br/index.php/content/view/310553.html>” if it involves animals.

DECLARATION OF CONFLICT OF INTERESTS

The authors declare no conflict of interest. The founding sponsors had no role in the design of the study; in the collection, analyses, or interpretation of data; in the writing of the manuscript, and in the decision to publish the results.

AUTHORS' CONTRIBUTIONS

MVB conceived and designed the experiment. CFT, FAV, MVB and RMC performed the surgical procedure. All authors prepared the draft of the manuscript, critically revised the manuscript and approved of the final version.

REFERENCES

- ACLAND, H.E. Sistema reprodutor do macho. In: CARLTON, W.W.; MCGAVIN, M.D. **Patologia veterinária especial de Thomson**, 2nd ed. Porto alegre: Artmed. 1998, p.573-589.
- BONJER, H.J.; HAZEBROEK, E.J.; KAZEMIER, G.; GIUFFRIDA, M.C.; MEIJER, W.S.; LANCE, J.F. Open versus closed establishment of pneumoperitoneum in laparoscopic surgery. **British Journal of Surgery**, v.84, p.599-602, 1997. Available from: <<https://onlinelibrary.wiley.com/doi/abs/10.1046/j.1365-2168.1997.d01-1355.x?sid=nlm%3Apubmed>>. Accessed: Aug. 23, 2019. doi: 10.1046/j.1365-2168.1997.d01-1355.x.
- BURKE, T.J.; REYNOLDS, H.A. The testes. In: BOJRAB, M.J. **Disease mechanisms in small animal surgery**, 2nded. Philadelphia: Lea & Febiger, 1993. p.546-547.
- IRWIN, B.H.; RAO, P.P.; STEIN, R.J.; DESAI, M.M. Laparoendoscopic single site surgery in urology. **The Urologic Clinics of North America**, v.36, p.223-235, 2009. Available from: <<https://www.sciencedirect.com/science/article/pii/S0094014309000123?via%3Dihub>>. Accessed: Aug. 23, 2019. doi: 10.1016/j.ucl.2009.02.011.
- JOHNSTON, S.D.; ROOT KUSTRITZ, M.V.; OLSON, P.N.S. Disorders of the canine testes and epididymes. In: SAUNDERS, W.B. **Canine and Feline Theriogenology**. Philadelphia, 2001. p.312-332.
- KAWAKAMI, E.; YAMADA, Y.; TSUTSUI, T.; OGASA, A.; YAMAUCHI, M. Changes in plasma androgen levels and testicular histology with descent of the testis in the dog. **The Japanese Journal of Veterinary Science**, v.55, n.6, p.931-935, 1993. Available from: <<https://ci.nii.ac.jp/naid/130003571797/>>. Accessed: Aug. 23, 2019. doi: 10.1292/jvms.55.931.
- TRACY, C.R.; RAMAN, J.D.; CADEDDU, J.A.; RANE, A. Laparoendoscopic single-site surgery in urology: where have we been and where are we heading? **Nature Clinical Practice**, v.5, n.10, p.561-568, 2008. Available from: <<https://www.nature.com/articles/ncpuro1215>>. Accessed: Aug. 23, 2019. doi: 10.1038/ncpuro1215.
- RUNGE, J.J.; MAYHEW, P.D.; BRAD CASE, J.; SINGH, A.; MAYHEW, K.N.; CULP, W.T.N. Single-port laparoscopic cryptorchidectomy in dogs and cats: 25 cases (2009–2014). **Journal of the American Veterinary Medical Association**, v.245, n.11, p.1258-1265, 2014. Available from: <<https://avmajournals.avma.org/doi/pdf/10.2460/javma.245.11.1258>>. Accessed: Aug. 23, 2019. doi: 10.2460/javma.245.11.1258.
- VERESS J. Neues instrument zur Ausführung von brust-oder bauchpunktionen und pneumothoraxbehandlung. **Dtsch Med Wochenshr**, v.41(8), p.1480-1481, 1938. Available from: <<https://www.thieme-connect.com/products/ejournals/abstract/10.1055/s-0028-1123401>>. Accessed: Aug. 23, 2019. doi: 10.1055/s-0028-1123401.
- YATES, D.; HAYES, G.; HEFFERNAN, M.; BEYNON, R. Incidence of cryptorchidism in dogs and cats. **Veterinary Record**, v.152, p.502-504, 2003. Available from: <<https://veterinaryrecord.bmj.com/content/152/16/502>>. Accessed: Aug. 23, 2019. doi: 10.1136/vr.152.16.502.