

# Laryngeal sequelae of recurrent respiratory papillomatosis surgery in children

JULIANA SATO HERMANN<sup>1</sup>, PAULO PONTES<sup>2</sup>, LUC LOUIS MAURICE WECKX<sup>3</sup>, REGINALDO FUJITA<sup>4</sup>, MELISSA AVELINO<sup>5</sup>, SHIRLEY SHIZUE NAGATA PIGNATARI<sup>6</sup>

<sup>1</sup>MSc in Sciences (Otorhinolaryngology); Assistant Physician, Department of Otorhinolaryngology and Head and Neck Surgery, Universidade Federal de São Paulo (UNIFESP), São Paulo, SP, Brazil

<sup>2</sup>Full Professor, Department of Otorhinolaryngology and Head and Neck Surgery, UNIFESP, São Paulo, SP, Brazil

<sup>3</sup>Full Professor; Chief of Department of Otorhinolaryngology and Head and Neck Surgery, UNIFESP, São Paulo, SP, Brazil

<sup>4</sup>Adjunct Professor, Department of Otorhinolaryngology and Head and Neck Surgery, UNIFESP; Chief of the Internal Clinic of the Pediatric Otorhinolaryngology Discipline, UNIFESP, São Paulo, SP, Brazil

<sup>5</sup>PhD in Sciences (Otorhinolaryngology), UNIFESP; Otorhinolaryngologist, São Paulo, SP, Brazil

<sup>6</sup>Adjunct Professor; Chief of the Pediatric Otorhinolaryngology Discipline, UNIFESP, São Paulo, SP, Brazil

## SUMMARY

**Objective:** To evaluate laryngeal sequelae from surgical treatment of recurrent respiratory papillomatosis in children, as well as associated risk factors. **Methods:** Case-control study. Medical record data analysis of 50 children with recurrent respiratory papillomatosis, divided into two groups: with and without laryngeal sequelae. The group of patients with laryngeal sequelae was compared to those without sequelae in regard to the onset of disease, age at first surgery, number and frequency of surgeries, disease stage, and type of surgery (CO<sub>2</sub> laser, cold forceps). **Results:** 23 patients (46%) sustained laryngeal sequelae. The most frequent sequela was anterior commissure synechia (17 patients [34%]), followed by glottic stenosis (six patients [12%]). There was no statistically significant difference between groups with and without laryngeal sequelae regarding the disease onset ( $p = 0.93$ ), age at first surgery ( $p = 0.68$ ), number of surgeries ( $p = 0.22$ ), annual frequency of surgery ( $p = 0.93$ ), presence of papilloma in anterior ( $p = 0.430$ ) or posterior commissure ( $p = 0.39$ ), and type of surgery ( $p = 0.27$ ). The Derkay anatomical score (a staging system that assesses the extent of the disease in the aerodigestive tract) was significantly higher in the laryngeal sequelae group ( $p = 0.04$ ). **Conclusion:** Laryngeal sequelae are a frequent complication of recurrent respiratory papillomatosis surgical treatment in children, particularly anterior commissure synechia and glottic stenosis. Advanced stages are associated with increased risk of laryngeal sequelae after surgery.

**Keywords:** Papilloma; postoperative complications; dysphonia; laser; therapy; papillomavirus infections.

Study conducted at the Pediatric Otorhinolaryngology Discipline, Department of Otorhinolaryngology and Surgery of the Head and Neck Surgery, Universidade Federal de São Paulo (UNIFESP), São Paulo, SP, Brazil

Submitted on: 04/02/2011  
Approved on: 12/08/2011

**Correspondence to:**  
Juliana Sato Hermann  
Rua dos Otonis, 674  
Vila Clementino  
CEP: 04025-001  
São Paulo – SP, Brazil  
juli64@ig.com.br

**Conflict of interest:** None.

©2012 Elsevier Editora Ltda. All rights reserved.

## INTRODUCTION

Recurrent respiratory papillomatosis (RRP) is characterized by proliferation of papillomas in the respiratory tract, frequently multiple and likely to recur. The disease affects individuals of all ages presenting a variety of clinical courses. RRP is classified as juvenile or adult, based on the onset of the disease.

In the United States, the annual incidence of RRP is estimated at 4.3 per 100,000 children<sup>1</sup>, with prevalence estimates of 1.69 to 2.59 per 100,000<sup>2</sup>. In Denmark, an incidence rate of 3.5 per 1 million person-years is reported<sup>3</sup>.

RRP is caused by human papillomavirus (HPV), usually types 6 and 11, which are also responsible for most cases of anogenital condylomata<sup>4</sup>. Although the mode of HPV transmission is still not clear, vertical transmission (intrauterine or occurring during delivery, through an infected birth canal) is presumed to be the major mode of transmission to children. HPV deoxyribonucleic acid has been detected in peripheral blood of pregnant women and neonates<sup>5</sup>.

When compared to the adult presentation, juvenile RRP tends to require more surgical procedures for recurrences and generally presents larger areas of airway involvement<sup>6</sup>. The larynx is usually the most affected site, particularly the vocal folds, epiglottis and vestibular folds<sup>7-9</sup>.

Juvenile RRP has similar distribution between males and females<sup>6,8,9</sup>. Most children present the first symptoms between the ages of two and four years and the most common symptom is dysphonia<sup>9</sup>. The progressive growth of lesions may result in obstruction of the respiratory tract, causing dyspnea and stridor. Less common presenting symptoms include chronic cough and dysphagia<sup>4</sup>. The earlier the first manifestation appears, the more aggressive RRP tends to be. Children diagnosed before the age of three years are 3.6 times more likely to need more than four surgeries per year and to present more than one diseased anatomical site<sup>8</sup>.

RRP treatment consists of the resection of the papillomas to maintain airway patency and to improve voice quality. However, even with the complete removal of the lesions, the virus remains latent, leading to recurrences. In children, five surgeries a year to control the recurrences is the average<sup>8,9</sup>.

The number of surgical procedures due to recurrences and the extent of the disease may increase the risk of surgical complications. Among them, laryngeal sequelae are frequently described<sup>10-20</sup>.

Conventional cold forceps, CO<sub>2</sub> laser, and microdebrider are the most employed instruments<sup>21</sup>. It is believed that according to the type of surgical procedure the risk of laryngeal sequelae may vary<sup>10</sup>. Some authors associate an increased risk of complications with conventional cold instruments<sup>10</sup>.

Surgical technique and frequency of surgical procedures may also be related to the risk of laryngeal sequelae. Extensive, radical surgical removal of papillomas in the anterior commissure<sup>11</sup> and frequent surgeries<sup>10</sup> have been associated with a higher rate of complications.

The objective of this study is to identify laryngeal sequelae from surgical treatment of RRP in children, and risk factors associated with laryngeal sequelae of surgery.

## METHODS

This study was approved by the Institutional Ethics in Research Committee, registered under the number 2045/08. Charts of patients with RRP attended to at the Otorhinolaryngology Pediatric Clinic of the UNIFESP were reviewed. Patients who had had recurrence after two or more controlling surgeries, onset of disease before 18 years of age, and histopathological confirmation, were included in this study. From 1998-2009, 55 patients with RRP were attended to, and 50 met the inclusion criteria. From medical records and exams (nasopharyngolaryngeal fibroscopy, bronchoscopy, and/or thorax computed tomography), the following data were collected:

1. Gender
2. Age of onset
3. Symptoms
4. Age at first surgery
5. Presence or absence of laryngeal sequela
6. Type of laryngeal sequela
7. Total number of surgeries for RRP treatment, or number of procedures until the sequela detection
8. Disease duration, or interval between diagnosis and detection of the sequela
9. Surgical technique applied (instruments used in the surgical procedures)
10. Topographic and sizing staging
11. Degree of airway obstruction

Based on the data from items 7 and 8, the annual frequency of surgeries of each patient was obtained. Based on the data from items 10 and 11, RRP was classified according to the staging score system proposed by Derkay et al.<sup>22</sup>, which assesses the extent of the disease in anatomical sites of the aerodigestive tract. Based on the size of the lesion, the surgeon attributes a score to each affected site, ranging from "0" to "3": "0" for no injuries, "1" for superficial injuries, "2" for raised lesions, and "3" for obstructive lesions. The sum provides an anatomical score (Figure 1). For results analysis, the maximum degree of respiratory impairment presented by the patients during their follow-up (the worst score presented during follow-up) was considered. Patients who did not have all information required by items 1 to 11 were not included in the study.

FOR EACH SITE. SCORE AS: 0 = NONE    1 = SURFACE LESION 2 = RAISED LESION    3 = BULKY LESION	
SITE	SCORE
Epiglottis – lingual surface	
Epiglottis – laryngeal surface	
Right aryepiglottic fold	
Left aryepiglottic fold	
Right false vocal cord	
Left false vocal cord	
Right true vocal cord	
Left true vocal cord	
Right arytenoid	
Left arytenoid	
Anterior commissure	
Posterior commissure	
Subglottis	
Trachea – upper one-third	
Trachea – middle one-third	
Trachea – lower one-third	
Right bronchi	
Left bronchi	
Tracheotomy stoma	
Nose	
Palate	
Pharynx	
Esophagus	
Lungs	
Other	
TOTAL (ANATOMICAL SCORE)	

**Figure 1** – Anatomical score from staging system proposed by Derkay et al.<sup>22</sup>.

Patients with laryngeal sequelae were compared to patients without sequelae according to the age of onset, age at first surgery, number of RRP surgeries, frequency of surgery, stage of the disease, and type of surgery.

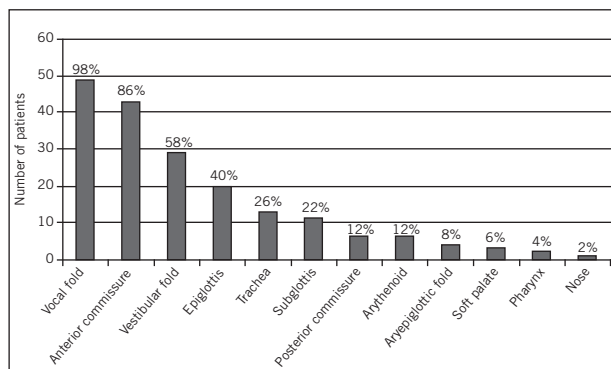
The statistical information was initially reported in a descriptive way. Student's *t* test for independent samples and Fisher's exact test were the inferential tests used to confirm the evidence. Significance level  $\alpha$  equal to 5% was used for all statistical results.

**RESULTS**

Gender distribution was 26 (52%) male and 24 (48%) female. Age at onset of symptoms ranged from one month to 15 years old (mean = 2.69 years). Thirty three patients (66%) presented the first symptoms before three years of age. The most common symptoms were dysphonia (40 patients [80%]), dyspnea (38 [76%]) and weak cry (10 [20%]). Age at first surgery ranged from nine months to 15 years (mean = 4.03 years). Twenty eight patients (56%) had their first surgery before four years of age. The total number of surgeries, or the number of procedures until the sequela was detected, ranged from two to 40 (mean = 8.84 surgeries per person). Thirty two patients (64%) required less than 10 controlling surgeries.

The duration of the disease or the interval between the diagnosis and the detection of the sequela ranged from one to 13 years (mean = 3.62). Surgery frequency ranged from 0.3 to nine (mean = 2.72 surgeries per year). Per year, 31 patients (62%) underwent less than three surgeries for recurrence control, while 19 (38%) required three or more surgeries.

The vocal fold was the most frequent affected site (49 patients [98%]). Extra-laryngeal spread was observed in 17 cases (34%), mostly in the trachea (13 patients [26%]). The spread to other anatomical sites is seen in Figure 2.



**Figure 2** – Anatomical sites affected by recurrent respiratory papillomatosis.

Forty three patients (86%) had involvement of the anterior commissure and six (12%) presented with papilloma at the posterior commissure. According to the Derkay et al.<sup>22</sup> staging system, the anatomical score ranged from 3 to 49 (mean = 13.32).

All patients were operated on using suspension laryngoscopy and surgical microscope, 41 (82%) patients were submitted to cold forceps (NL) surgery, and nine (18%) to CO<sub>2</sub> laser (L) surgery. The patients submitted to NL surgery were operated on by the same team of surgeons, with previous experience in laryngeal microsurgery. The L group was referred from other institutions and information regarding equipment settings, surgical technique, and surgeon experience was not available.

Twenty three patients (46%) developed laryngeal sequelae. Anterior commissure synechiae was the most frequent complication, present in 17 cases (34%), followed by anterior glottic stenosis (three patients [6%]), and posterior glottic stenosis (two patients [4%]). One (2%) patient presented with two concomitant complications (anterior and posterior glottic stenosis).

When the sequelae group was compared to those without sequelae, no statistically significant difference regarding the age of onset of symptoms (*p* = 0.93), age at first surgery (*p* = 0.68), number of surgeries (*p* = 0.22), annual surgery frequency (*p* = 0.93), presence of papilloma in the anterior commissure (*p* = 0.43) or posterior commissure (*p* = 0.39) was found. The Derkay score of the sequelae group was statistically higher than the score of the group without sequelae (*p* = 0.04) (Table 1).

**Table 1** – Comparison between groups with and without laryngeal sequelae

	With sequelae	Without sequelae	p
Age of symptom onset (average in years)	2.73	2.66	0.93
Age at first surgery (average in years)	4.22	3.86	0.68
Number of surgeries (average)	10.35	7.56	0.22
Annual frequency of surgeries (average)	2.70	2.75	0.93
Derkey score (average)	15.59	11.48	0.04
Papilloma in the anterior commissure			
Yes	21 (91.3%)	22 (81.5%)	0.43
No	2 (8.7%)	5 (18.5%)	
Papilloma in the posterior commissure			
Yes	4 (17.4%)	2 (7.4%)	0.39
No	19 (82.6%)	25 (92.6%)	
Laser			
Yes	6 (26.1%)	3 (11.1%)	0.27
No	17 (73.9%)	24 (88.9%)	

The L surgery among patients with laryngeal sequelae was equally frequent when compared to those without sequelae ( $p = 0.27$ ) (Table 1).

The distribution of sequelae between L and NL groups was different. A higher percentage of patients with glottic stenosis was observed among the L group (44.4%) compared to the NL group (4.9%). Anterior commissure synechia was frequent in both, L (22.2%) and NL (36.6%) groups (Table 2).

## DISCUSSION

The literature is not uniform regarding the classification of juvenile RRP as aggressive or non-aggressive. According to Doyle et al.<sup>6</sup>, RRP could be considered aggressive when a patient needs 10 or more surgical procedures, three or more surgical procedures a year, or if the disease spreads to a subglottic region. In this study, we chose not to classify the disease as aggressive or non-aggressive. Severity of the disease was demonstrated through age of onset, age at first surgery, total number of controlling surgeries, frequency of surgeries, and number of affected sites; as stated by other authors<sup>3,4,8,23</sup>.

The extent and severity of the lesions were represented by a staging system. Staging systems are useful for documentation of the disease evolution and for appropriate information reporting among professionals. Although

several systems have already been proposed, there is no single system accepted worldwide. Unfortunately, this lack of uniformity affects scientific communication, especially concerning therapeutic results.

The stage report reflects the severity of RRP in a particular moment, varying with time and treatment. The system proposed by Derkey et al.<sup>22</sup> was chosen for being the most applied worldwide. The most common symptoms were dysphonia and dyspnea, commonly observed in RRP, since the larynx is the most frequently affected site<sup>7-9</sup>. All patients in our study group had laryngeal disease.

The principal treatment for RRP is still surgical, aiming to clear the airway and to improve the voice quality. Its management often includes multiple surgeries over a long period that can lead to a high rate of morbidity in terms of voice quality in a substantial number of patients. Although not a routine practice in our service, possible care strategies may focus on voice therapy to optimize voice function after surgery, which may be beneficial for selected patients.

As a highly recurrent disease, RRP requires repeated manipulations of the larynx, increasing the risk of complications. Anterior glottic synechia, the most frequent reported late complication, is described in 1.8-41% of patients with RRP<sup>10,12-14</sup>. Posterior glottic and anterior commissure synechiae follow, occurring in 0.8-12% and 3.6-11.9% of patients, respectively<sup>10-16</sup>. Laryngeal or

**Table 2** – Distribution of sequelae among laser and cold forceps surgery groups

Type of sequela	Laser		Total
	No	Yes	
Glottic stenosis	2 (4.9%)	4 (44.4%)	6 (12%)
Anterior commissure synechia	15 (36.6%)	2 (22.2%)	17 (34%)
No sequela	24 (58.5%)	3 (33.3%)	27 (54%)
Total	41 (100%)	9 (100%)	50 (100%)

tracheal stenosis is found in up to 14% of cases<sup>10,15,16</sup>. Other less common sequelae include granulation tissue and laryngoceles<sup>12,17</sup>.

Our patients presented with anterior commissure synechia, anterior glottic stenosis, and posterior glottic stenosis. It is difficult to compare our findings to those reported by others, considering that a non-uniform nomenclature is used to describe laryngeal sequelae. Saleh<sup>13</sup>, Dedo and Yu<sup>14</sup>, and Preuss et al.<sup>10</sup> reported an incidence of 6.3-41% of anterior glottic synechia in their patients, however, they did not specify in which cases only the anterior commissure was affected, nor those with a greater extent. Similarly, Preuss et al.<sup>10</sup> used the term laryngeal stenosis, without specifying the type or location.

In our study, advanced stages of disease were associated with an increased risk of laryngeal sequelae development. The frequency of surgeries was not correlated to the development of laryngeal sequelae, diverging from the findings observed by Preuss et al.<sup>10</sup>. Age of symptom onset, age at first surgery, the total number of surgeries, and the commissures involvement by papilloma were not associated with either presence or absence of laryngeal sequelae.

The type of surgery may influence the surgical outcome. Conventional tweezers, CO<sub>2</sub> laser, and microdebrider are commonly used to treat RRP patients<sup>21</sup>. Neodymium-yttrium-aluminum-garnet laser (Nd-YAG) and pulsed light have also been used for RRP juvenile treatment<sup>24,25</sup>, in fewer cases. Reviews of a series of RRP treated with CO<sub>2</sub> laser reported 1.8-65% of cases of late complications<sup>11-14,17</sup>. In patients treated with NL surgical modalities this rate varies from 14.5-28.5%<sup>10,16</sup>.

Depending on the intensity of the laser beam in the spot area and time of exposing, the effect of laser may be excessive, causing injury to deep tissues. Moreover, the heat produced by the laser may be transmitted to the tissues around the target region, producing another damaged area<sup>4</sup>.

To decrease the risk of damaging adjacent tissue, special care and attention is recommended during the surgical procedures. Avoidance of deep resection of papillomas and maximum mucosa preservation, especially when the anterior commissure is involved, are recommended.

In the studied population, the incidence of glottic stenosis was higher among individuals with a history of L surgical treatment. However, these patients were referred from other institutions and specific information about the surgical procedure, such as laser exposure time, power settings, technique applied, surgeon experience, target area, and beam intensity was not obtained. Moreover, along with the fact that the number of CO<sub>2</sub> laser cases was relatively small, conclusions about the influence of the type of surgery (NL or L) on the development of laryngeal sequelae could not be drawn.

## CONCLUSION

Based on the results of our study, we concluded that laryngeal sequelae are a frequent complication of the surgical treatment of RRP in children, particularly anterior commissure synechia and glottic stenosis, and that they are often associated with an advanced stage of the disease.

## REFERENCES

1. Derkay CS. Task force on recurrent respiratory papillomas: a preliminary report. *Arch Otolaryngol Head Neck Surg.* 1995;121(12):1386-91.
2. Armstrong LR, Preston EJD, Reichert M, Phillips DL, Nisenbaum R, Todd NW, et al. Incidence and prevalence of recurrent respiratory papillomatosis among children in Atlanta and Seattle. *Clin Infect Dis.* 2000;31(1):107-9.
3. Silverberg MJ, Thorsen P, Lindeberg H, Ahdieh-Grant L, Shah KV. Clinical course of recurrent respiratory papillomatosis in Danish children. *Arch Otolaryngol Head Neck Surg.* 2004;130(6):711-6.
4. Derkay CS, Wiatrak B. Recurrent respiratory papillomatosis: a review. *Laryngoscope.* 2008;118(7):1236-47.
5. Tseng CJ, Lin CY, Wang RL, Chen LJ, Chang YL, Hsieh TT, et al. Possible transplacental transmission of human papillomaviruses. *Am J Obstet Gynecol.* 1992;166(1 Pt 1):35-40.
6. Doyle DJ, Gianoli GJ, Espinola T, Miller RH. Recurrent respiratory papillomatosis: juvenile versus adult forms. *Laryngoscope.* 1994;104(5 Pt 1):523-7.
7. Kashima H, Leventhal B, Mounds P, Hruban RH. Sites of predilection in recurrent respiratory papillomatosis. *Ann Otol Rhinol Laryngol.* 1993;102(8 Pt 1):580-3.
8. Armstrong LR, Derkay CS, Reeves WC. Initial results from the national registry for juvenile-onset recurrent respiratory papillomatosis. *Arch Otolaryngol Head Neck Surg.* 1999;125(7):743-8.
9. Reeves WC, Ruparella SS, Swanson KI, Derkay CS, Marcus A, Unger ER. National registry for juvenile-onset recurrent respiratory papillomatosis. *Arch Otolaryngol Head Neck Surg.* 2003;129(9):976-82.
10. Preuss SF, Klusmann JP, Jungehulsing M, Eckel HE, Guntinas-Lichius O, Damm M. Long-term results of surgical treatment for recurrent respiratory papillomatosis. *Acta Otolaryngol.* 2007;127(11):1196-201.
11. Ossoff RH, Wekhaven JA, Dere H. Soft-tissue complications of laser surgery for recurrent respiratory papillomatosis. *Laryngoscope.* 1991;101(11):1162-6.
12. Strong MS, Vaughan CW, Cooperband SR, Healy GB, Clemente MA. Recurrent respiratory papillomatosis. Management with the CO<sub>2</sub> laser. *Ann Otol Rhinol Laryngol.* 1976;85(4 Pt 1):508-16.
13. Saleh EM. Complications of treatment of recurrent laryngeal papillomatosis with the carbon dioxide laser in children. *J Laryngol Otol.* 1992;106(8):715-8.
14. Dedo HH, Yu KCY. CO<sub>2</sub> laser treatment in 244 patients with respiratory papillomatosis. *Laryngoscope.* 2001;111(9):1639-44.
15. Perkins JA, Inglis AF Jr, Richardson MA. Iatrogenic airway stenosis with recurrent respiratory papillomatosis. *Arch Otolaryngol Head Neck Surg.* 1998;124(3):281-7.
16. Cohen SR, Geller KA, Seltzer S, Thompson JW. Papilloma of the larynx and tracheobronchial tree in children. A retrospective study. *Ann Otol Rhinol Laryngol.* 1980;89(6 Pt 1):497-503.
17. Mesolella M, Motta G, Lagaurdia M, Galli L. Papillomatosis of the larynx: treatment with CO<sub>2</sub> laser. *B-ENT.* 2006;2(2):51-4.
18. Dedo HH, Jackler RK. Laryngeal papilloma: results of treatment with the CO<sub>2</sub> laser and podophyllum. *Ann Otol Rhinol Laryngol.* 1982;91(4 Pt 1):425-30.
19. Cole RR, Myer III CM, Cotton RT. Tracheotomy in children with recurrent respiratory papillomatosis. *Head Neck.* 1989;11(3):226-30.
20. Benjamin B, Parsons DS. Recurrent respiratory papillomatosis: a 10 year study. *J Laryngol Otol.* 1988;102(11):1022-8.
21. Shraff S, Derkay CS, Burke B, Lawson L. American Society of Pediatric Otolaryngology members' experience with recurrent respiratory papillomatosis and the use of adjuvant therapy. *Arch Otolaryngol Head Neck Surg.* 2004;130(9):1039-42.
22. Derkay CS, Malis DJ, Zalzal G, Wiatrak BJ, Kashima HK, Coltrera MD. A staging system for assessing severity of disease and response to therapy in recurrent respiratory papillomatosis. *Laryngoscope.* 1998;108(6):935-7.
23. Ruparella S, Unger ER, Nisenbaum R, Derkay CS, Reeves WC. Predictors of remission in juvenile-onset recurrent respiratory papillomatosis. *Arch Otolaryngol Head Neck Surg.* 2003;129(12):1275-8.
24. Janda P, Leunig A, Sroka R, Betz CS, Rasp G. Preliminary report of endolaryngeal and endotracheal laser surgery of juvenile-onset recurrent respiratory papillomatosis by Nd:YAG laser and a new fiber guidance instrument. *Otolaryngol Head Neck Surg.* 2004;131(1):44-9.
25. Hartnick CJ, Boseley ME, Franco RA, Cunningham MJ, Pransky S. Efficacy of treating children with anterior commissure and true vocal fold respiratory papilloma with the 585-nm pulsed-dye laser. *Arch Otolaryngol Head Neck Surg.* 2007;133(2):127-30.