

Nephrocalcinosis in a patient with Sjögren's syndrome/systemic lupus erythematosus

AMANDA CAROLINA DAMASCENO ZANUTO¹, TATIARA BUENO¹, VINICIUS DAHER ALVARES DELFINO², ALTAIR JACOB MOCELIN²

¹ Nephrology Residents, Hospital Evangélico de Londrina, Londrina, PR, Brazil

² Nephrology Department, Hospital Evangélico de Londrina, Londrina, PR, Brazil

Study conducted at Universidade Estadual de Londrina, Londrina, PR, Brazil

Correspondence to: Vinicius D. A. Delfino, Departamento de Nefrologia, Centro de Ciências da Saúde, Universidade Estadual de Londrina, Av. Robert Koch, 60 Vila Operária, 86038-440, Londrina – PR, Brazil – vddelfino@sercomtel.com.br

©2012 Elsevier Editora Ltda. All rights reserved.

A 46-year-old white woman has been followed in this nephrology clinic since 1995 due to recurrent nephrolithiasis and medullary nephrocalcinosis resulting from renal tubular acidosis (urinary pH of 8 in the context of systemic normal anion gap acidosis; serum potassium at lower limit, and 24-hour urine with normocalciuria but no detectable citrate) due to Sjögren's syndrome (SS). During follow-up, her adherence to alkali therapy had been suboptimal due to gastric intolerance to Shohl's solution, potassium citrate, and sodium bicarbonate. As consequence, she had progression in her nephrocalcinosis and passed several urinary calculi (biochemical analysis showed them to be composed of calcium phosphate and calcium oxalate). Currently, she presents normal estimated GFR (MDRD, 82 mL/min/1.73 m²) and no significant proteinuria, despite having presented, ten years after the diagnosis of SS, onset of systemic lupus erythematosus (SLE) with severe diffuse proliferative class IV lupus nephritis, treated successfully with corticosteroids and intravenous cyclophosphamide. Figure 1 shows the radiological appearance and Figure 2 depicts the ultrasonographic aspect of the patient's nephrocalcinosis.

Nephrocalcinosis is characterized by the presence of calcium deposits in the renal parenchyma; nephrolithiasis represents calcification within the lumen of the collecting system, ureter, and bladder¹. Recent observation suggests that nephrocalcinosis and calcium nephrolithiasis are to be considered independent pathologies, and that nephrocalcinosis may cause calcium nephrolithiasis only in certain conditions². Both types of renal calcification may be present in patients with SS. Nephrocalcinosis may be classified as cortical or medullary, according to the anatomic area involved³. When associated with SS, it is typically medullary and secondary to distal renal tubular acidosis (RTA). It is believed that the renal acidification problem seen in patients with SS is due to immune-mediated loss of proton regulation⁴. In addition to RTA, other disorders such as hyperparathyroidism, medullary sponge kidney, renal papillary necrosis, renal tuberculosis, hyperoxaluria, milk-alkali syndrome, sarcoidosis,

immobilization, and other conditions associated with hypercalcemia and hypercalciuria, may cause medullary nephrocalcinosis.

Nephrocalcinosis is usually identifiable by X-ray, but both ultrasonography (US) and computed tomography (CT) can detect it earlier than ordinary abdominal X-ray¹. US is considered to be an excellent diagnostic method for detection and monitoring of nephrocalcinosis³. The finding of hyperchogenic pyramids with a

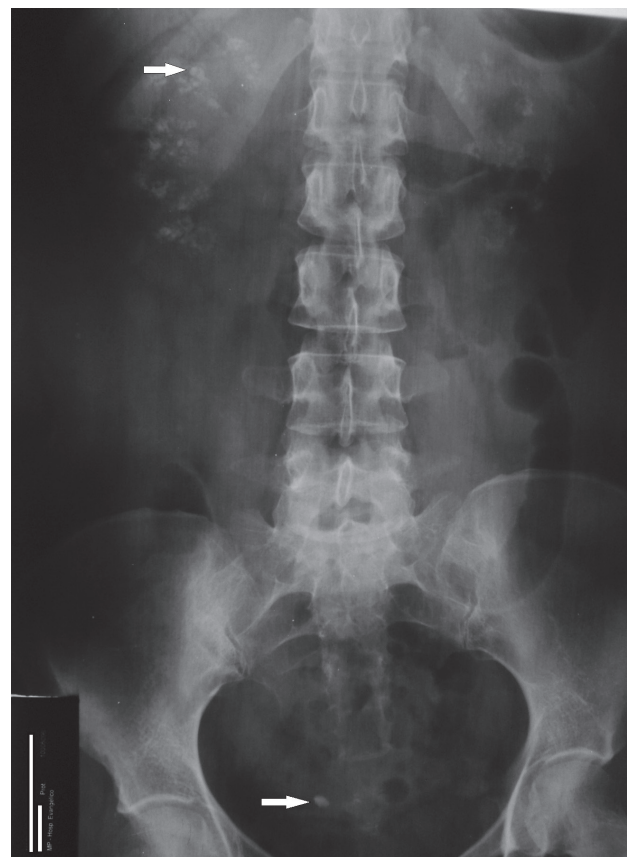

Figure 1 – Abdominal X-ray of the patient showing clustered calcifications in projection of the kidneys, more evident at the right side (upper arrow identifies one of these clusters). An 8-mm right distal ureteral stone is present (lower arrow).

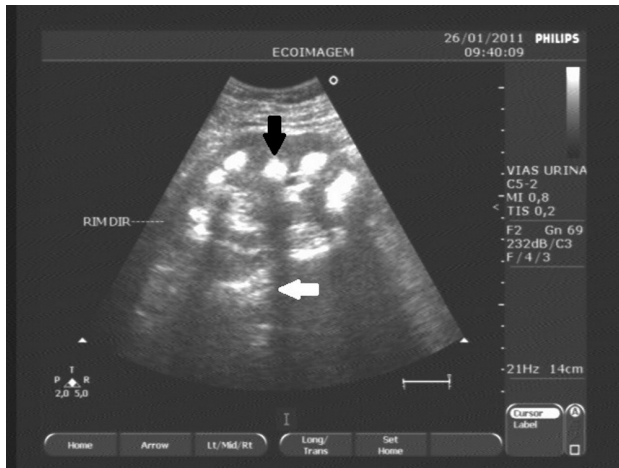


Figure 2 – Ultrasonographic appearance of patient's right kidney showing increased echogenicity of the renal medulla (medullary nephrocalcinosis). Black arrow shows a hyperechoic renal pyramid with dense posterior acoustic shadow (white arrow).

normally echogenic cortex is believed to be specific to medullary nephrocalcinosis^{3,5}. Despite being an excellent diagnostic method as well, CT (usually performed without radiocontrast) involves a considerable dose of radiation, which may limit its use for the follow-up of patients with nephrocalcinosis. Indeed, CT was found to be unnecessary for the clinical management of the patient.

Finally, the importance of investigating SS in patients with medullary nephrocalcinosis or nephrolithiasis associated with renal tubular acidosis, especially women, regardless of the presence of keratitis sicca or systemic symptoms, is emphasized, because it may be the first manifestation of the syndrome. Therapy for correction of acidosis is intended to control the nephrocalcinosis and preserve renal function⁶. This case corroborates that although RTA is a treatable urologic condition, incomplete treatment can lead to progression of nephrocalcinosis.

REFERENCES

1. Vanrenterghem Y, Kuypres D, Verswijvel G, Schepens D. Renal cortical nephrocalcinosis. *Nephrol Dial Transplant.* 2000;15:1080-2.
2. Vervaeck BA, Verhulst A, D'Haese PC, De Broe ME. Nephrocalcinosis: new insights into mechanisms and consequences. *Nephrol Dial Transplant.* 2009;24: 2030-5.
3. Hoppe B, Kemper MJ. Diagnostic examination of the child with urolithiasis or nephrocalcinosis. *Pediatr Nephrol.* 2010;25:403-13.
4. Evan AP, Lingeman J, Coe F, Shao Y, Miller N, Matlaga B, et al. Renal histopathology of stone-forming patients with distal renal tubular acidosis. *Kidney Int.* 2007;71:795-801.
5. Simões A, Domingos F, Prata MM. Nephrocalcinosis induced by furosemide in an adult patient with incomplete renal tubular acidosis. *Nephrol Dial Transplant.* 2001;16:1073-4.
6. Soriano JR. Renal tubular acidosis: the clinical entity. *J Am Soc Nephrol.* 2002;13:2160-70.