

Acute diverticulitis in a patient with intestinal malrotation

J.M. PERAZA CASAJÚS¹, I. BODEGA QUIROGA¹, M. GARCÍA-ORIA¹, NATALIA Z. ROSADO DAWID², P. VALLEJO DESVIAT³

¹Servicio de Cirugía General y del Aparato Digestivo, Hospital Central de la Defensa Gómez-Ulla, Madrid, Spain

²Servicio de Aparato Digestivo, Hospital Central de la Defensa Gómez-Ulla, Madrid, Spain

³Servicio de Radiodiagnóstico, Hospital Central de la Defensa Gómez-Ulla, Madrid, Spain

Study conducted at Hospital Central de la Defensa Gómez-Ulla, Madrid, Spain

Correspondence to: J.M. Peraza Casajús, Servicio de Cirugía General, Hospital Central de la Defensa "Gómez-Ulla", Glorieta del Ejército, s/n, 28047, Madrid, Spain – jesusmanuelper@msn.com

©2012 Elsevier Editora Ltda. All rights reserved.

CLINICAL CASE

61 year-old female, afebrile and hemodynamically stable, admitted to emergency room reporting abdominal pain of 5 days duration. Abdominal examination: soft and depressible abdomen, painful on palpation at left iliac fossa, without defense. TAC: multiple diverticula in the descending colon and sigmoid, thickened wall and discrete pericolic fat inflammatory changes (Figure 1), ansae of the small intestine in right iliac fossa (RIF) (Figure 2), in maximum intensity projection (MIP), intersection of the superior mesenteric artery in front of the vein, at the right of it (Figure 3).

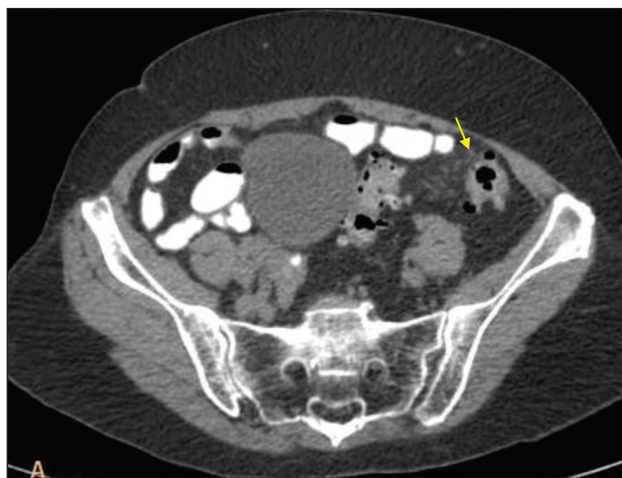


Figure 1 – Multiple diverticula in the descending colon and sigmoid with a colon segment showing thickened wall and discrete pericolic fat inflammatory changes.

DISCUSSION

Intestinal malrotation in adults has an approximate incidence of 0.19%¹. It can have an acute presentation (intestinal obstruction, volvulus, intestinal ischemia) or a chronic one, with crampy abdominal pain and bilious vomiting. Sometimes patients are asymptomatic, being an incidental discovery to find it on radiological explorations due to other reasons, as in the case presented here. All symptomatic patients should be treated surgically, by the Prophylactic

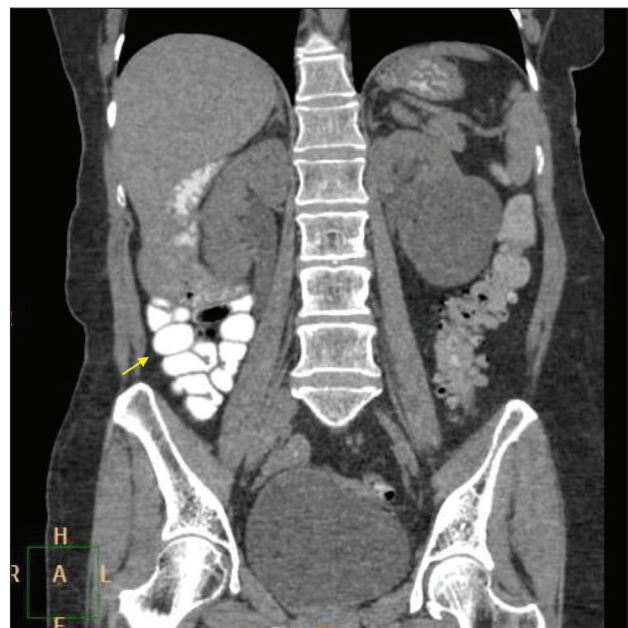


Figure 2 – Ansae of small intestine in RIF (right iliac fossa).

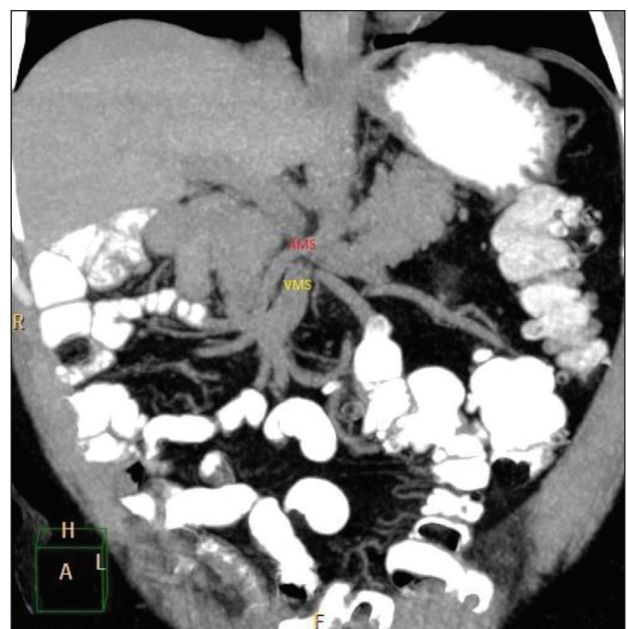


Figure 3 – Intersection of the superior mesenteric artery in front of the vein, at the right of it.

Ladd Procedure. Our patient had no previous abdominal symptoms due to the intestinal malrotation. In asymptomatic adults this procedure is uncertain due to the low incidence of small intestine volvulus in these patients^{2,3}.

REFERENCES

1. Lubinus Badillo FG, Rojas Rueda SP, Salcedo Hernández CJ. Intestinal malrotation as a cause for abdominal pain in adults. Case revision. *Med UNAB*. 2006;9:156-8.
2. Malek MM, Burd RS. Surgical treatment of malrotation after infancy: a population-based study. *J Pediatr Surg*. 2005;40:285-9.
3. Malek MM, Burd RS. The optimal management of malrotation diagnosed after infancy: a decision analysis. *Am J Surg*. 2006;191:45-51.