

Revista da
ASSOCIAÇÃO MÉDICA BRASILEIRA

www.ramb.org.br



Review article

**Breast cancer during pregnancy and chemotherapy:
a systematic review[☆]**

Denise Leite Maia Monteiro^{a,b,*}, Alexandre José Baptista Trajano^{b,c},
Daniela Contage Siccardi Menezes^{c,d}, Norma Luiza Machado Silveira^b,
Alessandra Caputo Magalhães^{d,e}, Fatima Regina Dias de Miranda^{b,c},
Barbara Caldas^b

^aCentro Universitário Serra dos Órgãos, Teresópolis, RJ, Brazil

^bMedical School, Universidade do Estado do Rio de Janeiro, Rio de Janeiro, RJ, Brazil

^cMedical School, Universidade do Grande Rio, Rio de Janeiro, RJ, Brazil

^dPerinatal Nucleus, Universidade do Estado do Rio de Janeiro, Rio de Janeiro, RJ, Brazil

^eMedical School, Universidade Gama Filho, Rio de Janeiro, RJ, Brazil

ARTICLE INFO

Article history:

Received 13 August 2012

Accepted 15 October 2012

Keywords:

Breast cancer

Pregnancy

Chemotherapy

A B S T R A C T

This study aimed to establish the safety of chemotherapy use in pregnant women with breast cancer, and to find possible effects in the fetus. A search of MEDLINE/PubMed, LILACS, SciELO, Cochrane, UpToDate, and Google Scholar databases was performed to identify publications. 86 articles published from 2001 to 2012 were retrieved and evaluated by two readers in accordance predetermined exclusion and inclusion criteria; 39 articles were selected. All the chemotherapy drugs used to treat breast cancer during pregnancy belonged to class D, and consisted of 5-fluorouracil (F), doxorubicin (A) or epirubicin (E) and cyclophosphamide (C), or the combination doxorubicin and cyclophosphamide (AC), a safe regimen when used after the first trimester of pregnancy. Few studies evaluated the use of taxanes (T), such as docetaxel (D) and paclitaxel (P), with no increase in the occurrence of fetal defects and other maternal complications when used in the second and third trimesters of pregnancy. The use of trastuzumab in pregnant women is associated with oligohydramnios and anhydramnios; thus, it is not recommended during pregnancy. As almost all studies were observational and retrospective, new prospective studies on the subject are needed.

© 2013 Elsevier Editora Ltda. All rights reserved.

[☆]Study conducted at Universidade do Estado do Rio de Janeiro, Rio de Janeiro, RJ, Brazil

*Corresponding author at: Núcleo Perinatal da UERJ (Universidade do Estado do Rio de Janeiro), Rua Prof. Manoel de Abreu, 500, Vila Isabel, Rio de Janeiro, RJ, 20550-170, Brazil

E-mail: denimonteiro2@yahoo.com.br (D.L.M. Monteiro)

Câncer de mama na gravidez e quimioterapia: revisão sistemática

R E S U M O

Palavras-chave:
Câncer de mama
Gravidez
Quimioterapia

O objetivo do estudo é estabelecer a segurança do uso da quimioterapia na gestante portadora de câncer de mama e verificar as possíveis intercorrências no feto. Para identificação de publicações foi realizada pesquisa bibliográfica nas bases de dados: MEDLINE/PubMed, LILACS, SciELO, Cochrane, Uptodate e Google acadêmico. A busca totalizou 86 artigos publicados de 2001 a 2012, que foram avaliados por dois revisores obedecendo aos critérios de exclusão e inclusão pré-estabelecidos, sendo selecionados 39 artigos para a elaboração deste estudo. Todos os quimioterápicos utilizados no tratamento do câncer de mama na gravidez pertencem à categoria D, consistindo no uso de 5-fluorouracil (F), doxorrubicina (A) ou epirubicina (E) e ciclofosfamida (C) ou na combinação de doxorrubicina e ciclofosfamida (AC), método seguro quando utilizado após o primeiro trimestre da gestação. Poucos estudos avaliaram o uso de taxanos (T) como docetaxel (D) e paclitaxel (P), não sendo demonstrado aumento da ocorrência de malformações fetais e outras complicações maternas quando utilizados no segundo e terceiro trimestres da gestação. O uso do trastuzumabe em gestantes encontra-se associado à oligodramnia e adramnia, não sendo recomendado na gravidez. Em função da quase totalidade dos estudos serem observacionais e retrospectivos, torna-se necessário a confecção de novos estudos prospectivos sobre o tema.

© 2013 Elsevier Editora Ltda. Todos os direitos reservados.

Introduction

Breast cancer is defined as associated with pregnancy when it is diagnosed during pregnancy, breastfeeding, or within the first year after birth. It is a challenging setting with a delicate management, whose treatment often generates problems and distress for the pregnant woman, her family, and health care professionals involved due to the dilemma created between the optimum therapy for the mother and well-being of the fetus. Delaying the treatment, with protection of the fetus in mind, may impair maternal health.¹⁻³

Breast cancer incidence may rise in coming years due to the secular trend of lower parity and first birth delay, brought about by changes in the lifestyle of modern women. Studies indicate that the incidence of pregnancy associated with breast cancer ranges from 1:3,000 to 1:10,000 pregnancies; the disease is mostly diagnosed in an advanced stage and has a worse prognosis than in non-pregnant women.^{1,4,5} In Sweden, an increase was observed between 1963 and 2002 from 16 to 37.4 per 100,000 births, that is, an absolute frequency of 1,161 cases of breast cancer associated with pregnancy.⁶

The goal of treating pregnant women with breast cancer is the same pursued for non-pregnant women: local control of the disease and prevention of systemic metastases. However, the treatment mode needs to be carefully evaluated in view of the potential adverse effects on the fetus.¹ Surgery seems to be reasonably safe, and is the ultimate treatment for breast carcinoma in pregnant women. The surgery risks during pregnancy include miscarriage and preterm birth, with no increased risk of congenital defects.^{4,5}

Radiation therapy should be delayed whenever possible until the postpartum period. Most pregnant women with breast cancer are candidates for systemic chemotherapy. Recent evidence suggests that several agents used in breast cancer treatment present a good safety profile, particularly when they

are started after the first trimester of pregnancy, resulting in live births and low morbidity.^{2,3,5,7,8}

This study aims to identify in the scientific literature evidence related to chemotherapy safety in pregnant women with breast cancer, and to find possible effects for the mother and the fetus.

Methods

A wide literature review was performed, searching digital databases. Publications in MEDLINE/PubMed were identified through the following search strategy: ("Breast Neoplasms" [MeSH] AND "Pregnancy Complications, Neoplastic" [MeSH] AND ("Drug Therapy" [MeSH] OR "Chemotherapy, Adjuvant" [MeSH]) AND ("humans" [MeSH Terms]) AND ("women" [MeSH Terms] OR "female" [MeSH Terms])); 76 articles were retrieved. For the LILACS, SciELO, Cochrane, and Google Scholar researches, the following keywords were used: breast neoplasms, pregnancy, chemotherapy, *câncer de mama*, *gravidez*, and *quimioterapia*; 10 additional articles were retrieved.

No randomized studies were retrieved, probably due to the low prevalence of the disease during pregnancy, which led to the inclusion of descriptive studies, since almost all articles retrieved were retrospective studies, case reports, and case series. Overall, the search resulted in 86 articles published between 2001 and 2012. The articles were evaluated by two readers who applied predefined exclusion and inclusion criteria, resulting in a final selection of 27 articles. The following inclusion criteria were considered: 1) pregnant patients; 2) patients had breast cancer; 3) the study addressed chemotherapy as treatment for breast cancer during pregnancy; 4) the article was written in English, Portuguese, Spanish, or French; 5) the study described systemic effects of chemotherapy on mother and fetus.

Studies published before 2001, those whose complete text was not available, and those that evaluated puerperal patients solely, addressed other treatments for pregnant women with breast cancer, evaluated non-pregnant patients, were written in foreign languages other than those mentioned, or assessed fertility and the possibility of pregnancy after chemotherapy were excluded. 12 other references were used to assist in elaborating the introduction and the discussion of results.

Figure 1 details the selection of articles used to make this study.

Results

The most often used chemotherapy regimen during the second or third trimester of pregnancy consists of 5-fluorouracil (F), doxorubicin (A) or epirubicin (E) and cyclophosphamide (C), or of the combination doxorubicin and cyclophosphamide (AC), all of which are considered class D in pregnancy.

Of the articles that met the selection criteria for this study, 12 addressed the use of these drugs; those chemotherapy regimens had the highest number of related studies. Epirubicin is the structural analog of doxorubicin, and has the advantage of causing less heart toxicity. Chemotherapy use in the first trimester is associated with malformations in 10% to 20% of fetuses, including micrognathia, hand and foot defects, and ventriculomegaly;^{9,10} however, it has been shown to be safe after that period (Table 1).

No data are available regarding the optimum dosage in regimens containing anthracyclines during pregnancy, whether or not associated with taxanes. The use of taxanes (T), such as docetaxel (D) and paclitaxel (P), was reported in five studies, and they appear to offer a limited risk to both mother and fetus, but their safety is poorly documented. Paclitaxel pharmacokinetics were studied in a case of twin pregnancy, with low fetal exposition to the drug.¹⁸

In the studies reviewed, no significant differences in maternal and perinatal results were identified with these drugs (Table 2).

Published data regarding trastuzumab use in pregnant women with breast cancer are included in ten case reports. In four, trastuzumab was used in association with other drugs, such as tamoxifen, docetaxel, and vinorelbine.²³⁻²⁶ The other six reports used trastuzumab alone. The time in the pregnancy when the drug was used varied among the studies.

The available evidence in these reports strongly suggests that the use of trastuzumab leads to reduced amniotic fluid volume, since in eight of ten studies oligohydramnios or anhydramnios was observed. In only one of the reports the amniotic fluid was found to be normal after discontinuation of the drug;²⁷ fetal death occurred in three of them (Table 3).^{23,28,29}

Discussion

Most pregnant women with breast cancer are candidates for chemotherapy. Due to the serious consequences for maternal health when treatment is delayed, pregnancy should not be considered a deterrent to appropriate therapy.^{1,2,3,33} Overall,

these patients can be treated in accordance with the guidelines set for the treatment in non-pregnant women. However, it is important to stress that almost all chemotherapy drugs used belong to class D, that is, they are potentially harmful for the developing fetus, but the requirements of treatment can warrant their use.

The informed consent is essential in approaching the case. The patient and her family should be informed of the therapeutic options and respective risks, and the treatment decision should be made together. Although pregnancy termination may be considered after the diagnosis of breast cancer, there is no evidence that it is necessary in order to improve maternal-fetal prognosis.³³ The approach must be individualized, mainly as a consequence of the gestational age and the patient's clinical condition.

The 27 studies selected in this review were observational. Most (25/27) were case reports or case series. This type of study is particularly used in infrequently seen clinical settings, such as breast cancer during pregnancy. They are applied to document uncommon medical events and can represent the first evidence to identify new conditions or adverse effects, e.g., teratogenic effects on the fetus in mothers undergoing chemotherapy during pregnancy.³⁴ The low incidence of this condition prevents other study designs that might generate better-quality scientific evidence, such as interventional studies/trials. Thus, the current review is limited by the quality of the studies included, due to a lack of more robust studies on the subject.

The therapy regimen most often used by pregnant women with breast cancer includes the anthracyclines epirubicin and doxorubicin, combined with cyclophosphamide and 5-fluorouracil (Table 1). This therapeutic regimen was used in 12 of the studies included in this review, describing 124 cases. Of these, only 4 cases underwent chemotherapy in the first trimester: there was one case of miscarriage³ and 2 cases of malformed neonates.^{9,10} There is also a report on one case with normal neonate after chemotherapy in all three trimesters of pregnancy.¹⁶ Despite the impossibility of a causative association between chemotherapy treatment in the first trimester and the malformations found, there is a consensus on avoiding its use during this period. New studies to assure the safety of using these drugs in early pregnancy are needed.

The study including the greatest number of cases of pregnant women with breast cancer treated with the FAC regimen in the second and third trimesters (57) showed that 40 women reached disease-free survival (three had recurrences, 12 died from breast cancer, one died from another cause, and one was lost to follow-up). All fetuses exposed to the therapy were live births with no malformations, except for three cases: one had Down syndrome, one had congenital clubfoot, and one had bilateral ureteral reflux. The small size of the sample impairs the comparison with the incidence of these alterations in the general population, and does not allow the causal association with the use of chemotherapy drugs is set. The authors reported no significant neonatal complications. The most common neonatal complication was supplemental oxygen, required in 10% of neonates, presumably due to prematurity. One neonate had a subarachnoid hemorrhage on the second day after vaginal delivery. Regarding long-term adverse effects,

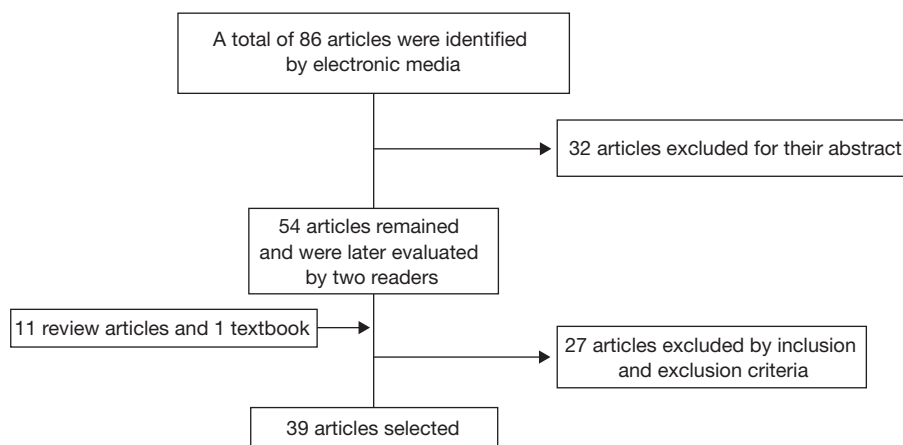


Fig. 1 – Flowchart explaining the bibliographic research and article selection.

such as fertility, cognition, and heart function disorders, the cases presented in this study did not have complications and presented evidences of normal development throughout the study period. These infants' follow-up ranged from 2 to 157 months. The authors concluded that using the FAC regimen during the second and third trimesters of pregnancy is safe and well-tolerated.⁵ Another study of 26 cases, with a follow-up for up to 84 months also did not evidence remote adverse effects.⁷

Regarding taxanes use, there are not many literature reports describing their use in pregnant women with breast

cancer. Taxanes are a group of antineoplastic drugs with antimetabolic activity that appear to improve the prognosis for women with breast cancer, particularly those having node involvement.³⁵ Animal studies demonstrate that these drugs may cause fetal demise and intrauterine growth restriction, in addition to conditions related to ossification.²⁰ However, none of the five case reports selected in this review demonstrated neonate involvement from medication use in the second and third trimesters (Table 2). One report on a fetus with hydrocephalus spontaneously reversed after birth. It is important to highlight, however, that the use of docetaxel

Table 1 – Evaluation of maternal and fetal effects of using 5-fluorouracil, doxorubicin or epirubicin, and cyclophosphamide.

Study/Year	Study Design	Sample	Substance (n)	Pregnancy period	Maternal effects	GA at birth	Fetal effects
Leyder et al. (2011) ⁹	Case report	1	FEC	1 st trim.	–	19 w	Micrognathia/hand and foot defects
Logue (2009) ¹¹	Case report	1	FAC	2 nd trim.	–	37 w	Normal neonate
Sharma et al. (2009) ¹²	Case report	1	FEC	3 rd trim.	Leucopenia	36 w	Normal neonate
Azim et al. (2008) ⁷	Cohort	26	E (23) A (3)	2 nd trim.	–	±35 w	Normal neonates
Hahn et al. (2006) ⁵	Cohort	57	FAC	2 nd and 3 rd trim.	–	±37 w	97% normal neonates (1 Down syndrome, 1 clubfoot, 1 ureteral reflux)
Skrablin et al. (2005) ¹³	Case report	1	AC	2 nd trim.	–	37 w	Normal neonate
Ring et al. (2005) ³	Case series	28	A (16)	2 nd trim.	1 miscarriage	37 w	Normal neonates
							FMC (12)
Mathelin et al. (2005) ¹⁴	Case report	2	FA	2 nd trim.	–	37 w	Normal neonates
Kerr (2005) ¹⁵	Case report	1	AC	2 nd trim.	–	31 w	Normal neonate
Paskulin et al. (2005) ¹⁰	Case report	1	FAC	1 st trim.	–	38 w	Ventriculomegaly, high palate, microcephaly, syndactyly, deficient growth and development
Andreadis et al. (2004) ¹⁶	Case report	1	FEC-1 st trim./ associated with RT/AZ/TX	1 st , 2 nd , and 3 rd trim.	Anemia hyperemesis	35 w	Normal neonate
Kuerer (2002) ¹⁷	Case report	4	FAC	3 rd trim.	–	36 w	Normal neonates

1st trim., 1st trimester of pregnancy; 2nd trim., 2nd trimester of pregnancy; 3rd trim, third trimester of pregnancy; A, doxorubicin; AC, doxorubicin + cyclophosphamide; AZ, zolendronic acid; C, cyclophosphamide; E, epirubicin; F, 5-fluorouracil; RT, radiation therapy (28 Gy); TX, tamoxifeno.

Table 2 – Evaluation of effects of docetaxel and paclitaxel use on the mother and the fetus.

Study/Year	Study Design	Sample	Substance (n)	Pregnancy period	Maternal effects	GA at birth	Fetal effects
Nieto et al. (2006) ¹⁹	Case report	1	FAC + docetaxel	2 nd and 3 rd trim.	–	39 w	Normal neonate
Lycette et al. (2006) ¹⁸	Case report	1 (twin)	Docetaxel	2 nd and 3 rd trim.	TPL	38 w	Normal neonate, up to 16-month follow-up
Potluri et al. (2006) ²⁰	Case report	2	AC+ docetaxel	2 nd and 3 rd trim.	Preeclampsia	34 w	Reversed hydrocephalus, N 28-month follow-up
Gonzalez-Angulo et al. (2004) ²¹	Case report	1	AC+ docetaxel	2 nd and 3 rd trim.	Preeclampsia	35 w	Normal neonate, 9-month follow-up
Gadducci et al. (2003) ²²	Case report	1	E+ paclitaxel	2 nd and 3 rd trim.	–	37 w	Normal neonate, 12-month follow-up
						36 w	Normal neonate, 36-month follow-up

2nd trim., 2nd trimester of pregnancy; 3rd trim, third trimester of pregnancy; N, normal; TPL, threatened premature labor.

by this patient occurred from 26 weeks of pregnancy and, by this time, hydrocephalus had already been diagnosed.²⁰ One patient with a twin pregnancy had contractions at the second docetaxel cycle, and nifedipino was used in subsequent cycles. The pregnancy proceeded uneventfully, and a C-section was performed at 38 weeks.¹⁸

A systematic literature review conducted in 2010 evidenced a favorable toxicity profile for taxanes during the second and third trimesters of pregnancy. However, as pregnancy induces pharmacokinetic changes, the conclusion was that taxane

efficacy is limited, thus suggesting that new studies assessing the pharmacokinetics, as well as placental crossing, are needed to confirm the safety profile in pregnant women with breast cancer.³⁶

Trastuzumab is a monoclonal antibody targeting the human epidermal growth factor receptor 2 (HER2). When this receptor is highly expressed, it leads to increased cell growth and proliferation, thus indicating that the breast tumor is more aggressive. Treatment with trastuzumab showed better outcomes and survival in the treatment of HER2-positive breast tumors.³⁷

Table 3 – Evaluation of effects of trastuzumab use on the mother and the fetus.

Study/Year	Study Design	Sample	Substance (n)	Pregnancy period	Maternal effects	GA at birth	Fetal effects
Beale et al. (2009) ²³	Case report	1 (twin)	Trastuzumab + tamoxifeno	1 st and 2 nd trim.	Oligohydramnios PL and PROM	32 w	Kidney injury – 1 st twin death at age of three months
Azim et al. (2009) ³⁰	Case report	1	Trastuzumab	Preconcep. and 1 st trim.	None	39 w	N development within fourteen months
Pant et al. (2008) ³¹	Case report	1	Trastuzumab	1 st and 2 nd trim.	Oligohydramnios	32 w	N development within five years
Weber & Schaefer (2008) ²⁸	Case report	1	Trastuzumab	1 st and 2 nd trim.	Oligohydramnios PA	27 w	< kidney perfusion, death at the age of four months
Bader et al. (2007) ²⁴	Case report	1	Trastuzumab + paclitaxel	2 nd and 3 rd trim.	Oligohydramnios Reduced fetal renal function	32 w	Neonatal sepsis, transient respiratory failure
Witzel et al. (2008) ²⁹	Case report	1	Trastuzumab	2 nd and 3 rd trim.	Oligohydramnios and vaginal bleeding	28 w	Respiratory failure, capillary fragility, and neonatal death
Sekar et al. (2007) ²⁵	Case report	1	Trastuzumab and docetaxel	2 nd and 3 rd trim.	Reversed oligohydramnios IUGR	36 w	
Shrim et al. (2007) ³²	Case report	1	Trastuzumab	1 st and 2 nd trim.	Reversed heart failure	37 w	Transient tachypnea, N development within two months
Fanale et al. (2005) ²⁶	Case report	1	Trastuzumab and Vironelbine	2 nd and 3 rd trim.	Oligohydramnios	34w	N development within six months
Watson et al. (2005) ²⁷	Case report	1	Trastuzumab	1 st and 2 nd trim.	Reversed oligohydramnios after drug withdrawal	37 w	N development within six months

1st trim., 1st trimester of pregnancy; 2nd trim., 2nd trimester of pregnancy; 3rd trim, third trimester of pregnancy; IUGR, intrauterine growth restriction; N, normal; PA, placental abruption; PL, premature labor; PROM, premature rupture of membranes.

The studies in pregnant women with breast cancer demonstrated an association with oligohydramnios or anhydramnios. One hypothesis to explain this reduced fluid volume is trastuzumab's secondary effect on the fetal renal epithelium, where epidermal growth factor receptors are highly expressed, and are blocked by this drug,^{30,31} leading to a decreased fetal urinary output, which was evidenced by empty fetal bladder visualization in the presence of echographically-normal kidneys. Pant et al.³¹ suggested that this oligohydramnios might be secondary to an altered expression of vascular endothelial growth factor (VEGF), which regulates amniotic fluid production and reabsorption by changing fetal membrane permeability.

Regarding the neonatal course, six cases of admission to a neonatal unit were observed.^{23,24,28,29,32} Irreversible kidney failure with demise of the first twin,²³ respiratory failure and capillary fragility with neonatal death²⁹, and decreased kidney perfusion with death at the age of four months were reported.²⁸ Other cases were successfully managed, with further normal development.^{26,27,30-32} Trastuzumab administration is associated with cardiotoxicity, with reduced ventricular ejection fraction.³⁸ Only one case of reversible heart failure was reported in the review.³² However, information on maternal heart evaluation is found only in two other studies describing normal maternal echocardiograms.^{27,30}

Thus, data regarding trastuzumab use in pregnancy are limited to few case reports, impairing conclusions. There were no malformation reports, although unfavorable neonatal outcomes have occurred. It is important to stress the prevalent observation of oligohydramnios, making thorough monitoring of the amniotic fluid volume, a fetal kidney function marker and a fetal well-being indicator, a mandatory measure in cases where the drug is an option. Likewise, maternal heart condition should be monitored due to the known cardiotoxicity of trastuzumab. Thus, trastuzumab use during pregnancy, especially extended use, is not encouraged,³⁸ and should be restricted to cases where treatment benefits for the mother outweigh pulmonary hypoplasia, skeletal abnormalities, kidney injury, and neonatal death risks.^{23,27,29,36}

When planning the therapy for pregnant women, delivery is scheduled within two or three weeks after the last chemotherapy cycle, in order to avoid maternal and/or fetal neutropenia, and thus reducing the risk of complications.⁵

The selection of a chemotherapy regimen to treat metastatic disease is extremely controversial, and experts prefer to use anthracycline drugs. Evidence shows that anthracycline use is safe in the second and third trimesters of pregnancy, with evidence level 2B (Oxford Level of Evidence [LOE] 2B). Given the lack of scientific evidence, recommendations of new cytotoxic drugs during pregnancy, such as taxanes, are not the consensus (LOE 5),⁸ and trastuzumab use should also be avoided.^{23,25,27,29,31,36}

The prospect of a future pregnancy is important for young women with breast cancer. Studies show that pregnancy occurrence in women with previous breast cancer history after successful management has no significant impact on survival. A meta-analysis including 1,244 women who conceived after breast cancer treatment and 18,145 controls confirmed these results and suggested that pregnancy after breast cancer may

have a protective effect, with a reduction of death risk by 42% (OR = 0.42), compared with the group that did not conceive after cancer treatment.³⁹

Conversely, there are cases of patients with breast cancer that conceive during chemotherapy with potentially teratogenic drugs. This demonstrates the importance of contraception in women of reproductive age requiring chemotherapy, through an intrauterine device, barrier methods, or combined non-hormonal methods.

Recommendations

1. Chemotherapy in pregnant women with breast cancer should not be delayed, and additional care should be taken to protect the fetus.
2. Chemotherapy can be safely administered during the second and third trimesters with minimal risk to the fetus.
3. Regimens based on anthracycline use should be preferred.
4. Chemotherapy should be avoided within three or four weeks from delivery in order to prevent neonatal transient myelosuppression.
5. Trastuzumab use is not recommended during pregnancy, due to the risk of oligohydramnios, anhydramnios, fetal pulmonary hypoplasia, skeletal and developmental abnormalities, and fetal demise.

Conflict of interest

All authors declare to have no conflict of interest.

REFERENCES

1. Loibl S, von Minckwitz G, Gwyn K, Ellis P, Blohmer JU, Schlegelberger B, et al. Breast carcinoma during pregnancy. International recommendations from an expert meeting. *Cancer*. 2006;106:237-46.
2. Woo JC, Yu T, Hurd TC. Breast cancer in pregnancy: a literature review. *Arch Surg*. 2003;138:91-8.
3. Ring AE, Smith IE, Jones A, Shannon C, Galani E, Ellis PA. Chemotherapy for breast cancer during pregnancy: an 18-year experience from five London teaching hospitals. *J Clin Oncol*. 2005;23:4192-7.
4. Keinan-Boker L, Lerner-Geva L, Kaufman B, Meirou D. Pregnancy-associated breast cancer. *Isr Med Assoc J*. 2008;10:722-7.
5. Hahn KM, Johnson PH, Gordon N. Treatment of pregnant breast cancer patients and outcomes of children exposed to chemotherapy in utero. *Cancer*. 2006;107:1219-26.
6. Andersson TM, Johansson AL, Hsieh CC, Cnattingius S, Lambe M. Increasing incidence of pregnancy-associated breast cancer in Sweden. *Obstet Gynecol*. 2009;114:568-72.
7. Azim HA Jr, Peccatori FA, Scarfone G, Acaia B, Rossi P, Cascio R, et al. Anthracyclines for gestational breast cancer: course and outcome of pregnancy. *Ann Oncol*. 2008;19:1511-2.
8. Loibl S, Ring A, von Minckwitz G. Breast cancer during pregnancy: a prospective and retrospective European registry (GBG-20/BIG02-03). *Eur J Cancer Suppl*. 2008;6:68.
9. Leyder M, Laubach M, Breugelmanns M, Keymolen K, De Greve J, Foulon W. Specific congenital malformations after exposure

- to cyclophosphamide, epirubicin and 5-fluorouracil during the first trimester of pregnancy. *Gynecol Obstet Invest.* 2011;71:141-4.
10. Paskulin GA, Zen PRG, Pinto LLC, Rosa R, Graziadio C. Combined chemotherapy and teratogenicity. 2005. *Birth Defects Res. (Part A)* 2005;73:634-7.
 11. Logue K. Pregnancy-associated breast cancer. *Clin J Oncol Nurs.* 2009; 13:25-7.
 12. Sharma JB, Pushparaj M, Kumar S, Roy KK, Raina V, Malhotra N. Successful pregnancy outcome with 5-fluorouracil, epirubicin, cyclophosphamide chemotherapy, and hemostatic radiotherapy with abdominal shielding for metastatic invasive intraductal breast carcinoma. *Arch Gynecol Obstet.* 2009;279:415-7.
 13. Skrablin S, Banovic V. Adriamycin and cyclophosphamide chemotherapy in advanced breast cancer in pregnancy. *Eur J Obstet Gynecol Reprod Biol.* 2007;133:247-53.
 14. Mathelin C, Annane K, Dufour P, Liegeois P, Bergeral JP. Chemotherapy for breast cancer during pregnancy. *Eur J Obstet Gynecol Reprod Biol.* 2005;123:260-2.
 15. Kerr JR. Neonatal effects of breast cancer chemotherapy administered during pregnancy. *Pharmacotherapy.* 2005;25: 438-41.
 16. Andreadis C, Charalampidou M, Diamantopoulos N, Chouchos N, Mouratidou D. Combined chemotherapy and radiotherapy during conception and first two trimesters of gestation in a woman with metastatic breast cancer. *Gynecol Oncol.* 2004;95:252-5.
 17. Kuerer HM, Gwyn K, Ames FC, Theriault RL. Conservative surgery and chemotherapy for breast carcinoma during pregnancy. *Surgery.* 2002;131:108-10.
 18. Lycette JL, Dul CL, Munar M, Belle D, Chui SY, Koop DR, et al. Effect of pregnancy on the pharmacokinetics of paclitaxel: a case report. *Clin Breast Cancer.* 2006;7:342-4.
 19. Nieto Y, Santisteban M, Aramendia JM, Fernandez-Hidalgo O, Garcia-Manero M, López G. Docetaxel administered during pregnancy for inflammatory breast carcinoma. *Clin Breast Cancer.* 2006;6:533-4.
 20. Potluri V, Lewis D, Burton GV. Chemotherapy with taxanes in breast cancer during pregnancy: case report and review of the literature. *Clin Breast Cancer.* 2006; 7:167-70.
 21. Gonzalez-Angulo AM, Walters RS, Carpenter RJJ, Ross MI, Perkins GH, Gwyn K, et al. Paclitaxel chemotherapy in a pregnant patient with bilateral breast cancer. *Clin Breast Cancer.* 2004;5:317-9.
 22. Gadducci A, Cosio S, Fanucchi A, Nardini V, Roncella M, Conte PF, et al. Chemotherapy with epirubicin and paclitaxel for breast cancer during pregnancy: case report and review of the literature. *Anticancer Res.* 2003;23(6D):5225-9.
 23. Beale JMA, Tuohy J, McDowell, SJ. Herceptin (trastuzumab) therapy in a twin pregnancy with associated oligohydramnios. *Am J Obst Gynecol.* 2009;201:e13-e14.
 24. Bader AA, Schlembach D, Tamussino KF, Pristauf G, Petru E. Anhydramnios associated with administration of trastuzumab and paclitaxel for metastatic breast cancer during pregnancy. *Lancet Oncol.* 2007;8(1):79-81.
 25. Sekar R, Stone PR. Trastuzumab use for metastatic breast cancer in pregnancy. *Obstet Gynecol.* 2007; 110(2 Pt 2):507-10.
 26. Fanale MA, Uyei AR, Theriault RL, Adam K, Thompson RA. Treatment of metastatic breast cancer with trastuzumab and vinorelbine during pregnancy. *Clin Breast Cancer.* 2005;6:354-6.
 27. Watson WJ. Herceptin (trastuzumab) therapy during pregnancy: association with reversible anhydramnios. *Obstet Gynecol.* 2005;105:642-3.
 28. Weber-Schoendorfer C, Schaefer C. Trastuzumab exposure during pregnancy. *Reprod Toxicol* 2008;25:390-1.
 29. Witzel ID, Mueller V, Harps E, Jaenicke F, Wit M. Trastuzumab in pregnancy associated with poor fetal outcome. *Ann Oncol.* 2008;19:191-2.
 30. Azim HA, Peccatori FA, Liptrott SJ, Catania C, Goldhirsch A. Breast cancer and pregnancy: how safe is trastuzumab?. *Clin Oncol.* 2009;6:367-70.
 31. Pant S, Landon MB, Blumenfeld M, Farrar W, Shapiro CL. Treatment of breast cancer with trastuzumab during pregnancy. *J Clin Oncol.* 2008;26:1567-9.
 32. Shrim A, Garcia-Bournissen F, Maxwell C, Farine D, Koren G. Favorable pregnancy outcome following trastuzumab (herceptin) use during pregnancy - case report and updated literature review. *Reprod Toxicol.* 2007;23:611-3.
 33. Yip CH, Taib NA, Abdullah MM, Wahid I. Breast cancer in pregnancy: our experience with six patients in the university hospital, Kuala Lumpur. *Med J Malay.* 2000;55:308-10.
 34. Hennekens CH, Buring JE. *Epidemiology in medicine. Descriptive studies.* Chapter 5. New York: Little Brown and Company; 1987. p.101-31.
 35. Early Breast Cancer Trialists' Collaborative Group (EBCTCG), 2012. Comparisons between different polychemotherapy regimens for early breast cancer: meta-analyses of long-term outcome among 100000 women in 123 randomized trials. *Lancet.* 2012;379:432-44.
 36. Mir O, Berveiller P, Goffinet F, Treluyer JM, Serreau R, Goldwasser F, et al. Taxanes for breast cancer during pregnancy: a systematic review. *Ann Oncol.* 2010;21:425-33.
 37. Romond EH, Perez EA, Bryant J, Suman VJ, Geyer CE Jr, Davidson NE, et al. Trastuzumab plus adjuvant chemotherapy for operable HER2 positive breast cancer. *N Engl J Med.* 2005;353: 1673-84.
 38. Perez EA. Cardiac toxicity of ErbB2-targeted therapies: what do we know? *Clin Breast Cancer.* 2008;8(Suppl 3):S114-S120.
 39. Azim HA Jr, Santoro L, Pavlidis N, Gelber S, Kroman N, Azim H, et al. Safety of pregnancy following breast cancer diagnosis: a meta-analysis of 14 studies. *Eur J Cancer.* 2011;47:74-83.