

Acute appendicitis in pregnancy: literature review

ANTÔNIO HENRIQUES DE FRANCA NETO¹, MELANIA MARIA RAMOS DO AMORIM², BIANCA MARIA SOUZA VIRGOLINO NÓBREGA³

¹Master's degree and coordinator of the PRM in Obstetrics and Gynecology at the Federal University of Campina Grande (UFCG), Campina Grande, PB, Brazil

²PhD and professor of Gynecology at the UFCG, Campina Grande, PB, Brazil

³Specialist and resident physician of Obstetrics and Gynecology at the Faculty of Nursing and Medicine Nova Esperança (FAMENE), João Pessoa, PB, Brazil

SUMMARY

Introduction: suspected appendicitis is the most common indication for surgery in non-obstetric conditions during pregnancy and occurs in about one in 500 to one in 635 pregnancies per year. This occurs more often in the second trimester of pregnancy. Acute appendicitis is the most common general surgical problem encountered during pregnancy.

Methods: a literature review on research of scientific articles, under the terms “acute appendicitis” and “pregnancy”, in PubMed, Lilacs/SciELO, Scopus, Cochrane Library and Uptodate databases.

Results: the clinical manifestations of appendicitis are similar to non-pregnant women, however, without a classic presentation, which often occurs, diagnosis is difficult and must be supported by imaging.

Discussion: clinical diagnosis should be strongly suspected in pregnant women with classic findings such as abdominal pain that migrates to the right lower quadrant. The main purpose of imaging is to reduce delays in surgical intervention due to diagnostic uncertainty. A secondary objective is to reduce, but not eliminate, the negative appendectomy rate. Differential diagnosis of suspected acute appendicitis usually includes pathologies considered in non-pregnant people.

Conclusion: the imaging study of choice is ultrasound, MRI may be used when the former is not conclusive and, as a last resort, a CT scan can be performed. The treatment remains appendectomy by laparotomy, since the feasibility of video-assisted surgery in these cases remains controversial.

Keywords: appendicitis, pregnancy, pregnancy complications.

Study conducted at the Federal University of Campina Grande, Campina Grande, PB, Brazil

Article received: 3/19/2014
Accepted for publication: 7/3/2014

*Correspondence
Address: Rua Carlos Chagas, SN
São José
Campina Grande, PB – Brazil
Postal code: 58100-000
antoniomed1@gmail.com

<http://dx.doi.org/10.1590/1806-9282.61.02.170>

Conflict of interest: none

INTRODUCTION

Suspected appendicitis is the most common indication for surgery for non-obstetric conditions during pregnancy and occurs in approximately one in 500 to one in 635 pregnancies per year.^{1,2} Appendicitis occurs most often in the second trimester of pregnancy.¹⁻³ Abdominal surgery during pregnancy, particularly appendectomy, can increase the risk of unfavorable outcomes.⁴

Diagnosis is particularly difficult during pregnancy, because of the relatively high prevalence of abdominal discomfort and gastrointestinal complaints, as well as anatomical changes related to the increase in uterine volume and the physiological leukocytosis that occurs during this period. A ruptured appendix is more common in pregnant women, especially in the third trimester, possi-

bly due to these difficulties and the reluctance to operate on pregnant women, which ultimately delays diagnosis and treatment.²

METHODS

A search of scientific articles was performed using the terms “appendicitis” and “pregnancy” in the PubMed, Lilacs/SciELO, Scopus and Cochrane Library databases, in addition to Uptodate, last reviewed on February 28th, 2014. 68 scientific articles were analyzed and included in this review.

RESULTS

Acute appendicitis is confirmed in 1/800 to 1/1500 pregnancies.³⁻⁶ Pregnant women seem less likely to have appendicitis than non-pregnant women matched by age

(OR 0.78, 95% CI 0.73% - 0.82%), with a slightly higher incidence in the second trimester of pregnancy.⁷

Clinical characteristics

Classically, patients describe the appearance of abdominal pain as the first symptom. It begins with periumbilical pain, which then migrates to the right lower quadrant to the extent that the inflammation progresses.^{8,9} Anorexia, nausea and vomiting, if present, appear after the pain. Fever of up to 38.3°C and leukocytosis may subsequently develop.⁹

Many patients have atypical presentation, with symptoms such as heartburn, bowel irregularity, flatulence and/or nonspecific discomfort. If the appendix is retrocecal, patients complain of diffuse pain in the right lower quadrant, rather than localized sensitivity. Digital rectal or vaginal examination in these patients generally causes more pain than the abdominal examination. A pelvic appendix can cause sensitivity below McBurney's point, complaints of an increase in urinary frequency and dysuria or rectal symptoms, such as tenesmus, which can confuse the examiner and delay diagnosis.¹⁰

Pregnant women are less likely to have a classic presentation of appendicitis, but the most common symptom of appendicitis, i.e. pain in the lower right quadrant, occurs near McBurney's point in most pregnant women, irrespective of the stage of pregnancy.^{5,11,12} As the location of the appendix migrates a few centimeters toward the head with the increase in uterine volume, in the third trimester, the pain may be located in the flank or in the right upper quadrant.^{13,14}

McBurney's sign is described as pain upon palpation about 1.5 to 2.0 centimeters from the anterior superior iliac spine in a straight line from that point to the navel.¹⁵ This sensitivity may be less prominent during pregnancy because the pregnant uterus lifts and stretches the anterior abdominal wall, increasing the distance to the inflamed appendix.^{16,17} Since direct contact between the area of inflammation and parietal peritoneum is prevented, there is less sensitivity, pain upon decompression or abdominal guarding. The pregnant uterus may also prevent contact between the omentum and inflamed appendix, which increases the possibility of diffuse peritonitis, since the fetal membranes would not be able to block the inflammatory process.¹⁷

The largest review, which describes the frequency of clinical signs and symptoms of appendicitis during pregnancy, included 720 cases with 75% relating to acute inflammation and 25%, to perforation.¹⁸ However, it has

several limitations, including the selection of non-consecutive cases in addition to those diagnosed before the widespread use of current diagnostic imaging procedures. Table 1 presents the signs and symptoms of appendicitis reported in this review.

TABLE 1 Percentage appearance of signs and symptoms of acute appendicitis.

Symptoms	Percentage appearance
Abdominal pain	95% Right lower quadrant: 75% Right upper quadrant: 20%
Nausea	85%
Vomiting	70%
Anorexia	65%
Dysuria	8%
Signs	Percentage appearance
Sensitivity in the lower right quadrant	85%
Pain upon decompression	80%
Abdominal guarding	50%
Rectal sensitivity	45%
Sensitivity in the upper right quadrant	20%

About 80% of non-pregnant patients with appendicitis have preoperative leukocytosis of over 10,000 cells/mL with a left shift.¹⁸⁻²¹ However, mild leukocytosis may be a normal finding in pregnant women: the total leukocyte count can reach 16,900 cells/mL in the third trimester, rising to levels of around 29,000 cells/mL during labor, including a slight left shift.²²

Microscopic hematuria and leukocyturia may occur when the inflamed appendix is located near the bladder or ureter, but these results are reported in less than 20 percent of patients.^{16,18,23,24} Slight increases in the total serum bilirubin have been described as a marker for perforation of the appendix (70% sensitivity and 86% specificity²⁵). C-reactive protein also rises in appendicitis, but it is a nonspecific sign of inflammation.²¹

Diagnosis

Acute appendicitis is a histological diagnosis. Clinical diagnosis should be strongly suspected in pregnant women with classic findings, such as abdominal pain, which migrates to the right lower quadrant, tenderness in the right lower quadrant, nausea and/or vomiting, fever and leukocytosis with a left shift.¹

With an atypical presentation, which often occurs during pregnancy, imaging studies are recommended.³

The main objective of these examinations is to reduce delays in surgical interventions due to diagnostic uncertainty. A secondary objective is to reduce, but not eliminate, the negative appendectomy rate. In such cases, ultrasounds can reveal the possible cause of the patient's symptoms (e.g. ovarian cyst or torsion, degeneration or torsion of myoma, nephrolithiasis, cholecystitis).³

Diagnosis of acute appendicitis in a patient during labor requires a high level of suspicion, is especially difficult and may not be possible. Labor may be associated with pain, which may be lateralized, fever and chorioamnionitis, leukocytosis and vomiting. Persistence or progression of these symptoms after delivery should be followed by a detailed physical examination and imaging studies to evaluate appendicitis.¹

Imaging

The initial method of choice for imaging the appendix in pregnancy is ultrasound.²⁶ The main finding is the identification of a non-compressible, blind-ended tubular structure in the lower right quadrant, with a maximum diameter exceeding 6 mm (Figure 1).^{27,28}

The diagnosis should not be excluded if the appendix looks normal, unless the ultrasound findings suggest a possible alternative diagnosis (e.g. ovarian torsion, nephrolithiasis).²⁸

Several studies have reported non-visualization of the appendix in a large percentage of pregnant women with suspected appendicitis.²⁹⁻³³ However, in a review of studies on the value of ultrasound diagnostics during appendicitis in pregnancy, sensitivity ranged from 67 to 100% and specificity of 83 to 96%, compared with the general

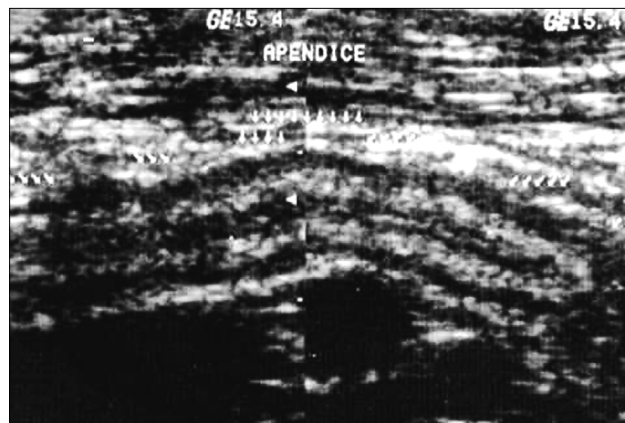


FIGURE 1 Ultrasonography. Appendix with thickened walls (4 mm) and loss of normal stratification.

Available at: http://www.scielo.br/scielo.php?script=sci_arttext&pid=S010039842003000200004. Webpage visited on 3/5/2014.

population, in which sensitivity and specificity were 86 and 96%, respectively.³⁴ Several factors influence the performance of ultrasound diagnosis of appendicitis in pregnancy, including gestational age, body mass index (BMI), and most importantly, the training and experience of the examiner.³⁵

Nuclear magnetic resonance imaging (MRI) is an excellent method to exclude acute appendicitis in pregnant women when the clinical examination and ultrasound are inconclusive.³⁶ MRI is an attractive alternative to computerized tomography (CT), avoiding exposure to ionizing radiation (Figure 2).

Gadolinium is not administered routinely because of theoretical concerns about fetal safety, but can be used if essential.³⁷ According to the American College of Radiology, the preferred test after an inconclusive ultrasound in the evaluation of suspected appendicitis during pregnancy is MRI.³⁸ However, conduct should not be delayed awaiting magnetic resonance imaging, as the increased risk of rupture over time must be considered.³⁸

A meta-analysis, evaluating MRI in pregnant women with suspected appendicitis, included six studies with 12 to 148 patients, of which 2 to 14 patients had acute appendicitis confirmed.³⁶ The combined sensitivity was 91% (CI 95% 54-99%), the combined specificity was 98% (CI 95% 87-99%), and positive and negative predictive values were 86 and 99%, respectively. Sensitivity, specificity and positive and negative predictive values for MRI

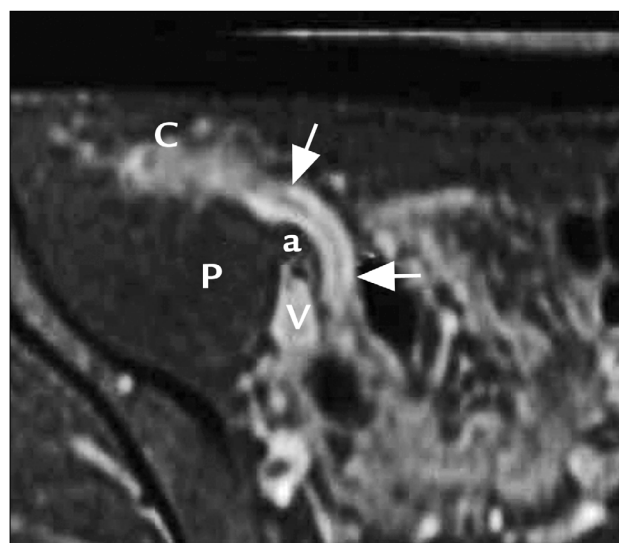


FIGURE 2 Acute suppurative appendicitis. Thickened and inflamed appendix (arrow).

Available at: <http://emedicine.medscape.com/article/363818-overview#a21>. Webpage visited on 3/5/2014.

in the diagnosis of appendicitis were 100, 93, 61 and 100%, respectively.

Computed tomography (CT) is generally more available than MRI, but is still inaccessible in many places in Brazil. The main appendicitis findings in CT are inflammation in the lower right quadrant, a hollow elongated tubular structure and/or appendicolith/fecalith (Figure 3).⁴⁰

The initial experience with helical computed tomography for the diagnosis of appendicitis in pregnancy seems promising, but the data are limited to small series of cases.³⁹ Changes to the CT protocol can limit exposure to fetal radiation estimated at less than 3 mGy, well below the doses related to adverse fetal effects (30 mGy for the risk of carcinogenesis, 50 mGy for deterministic effects)^{36,40}

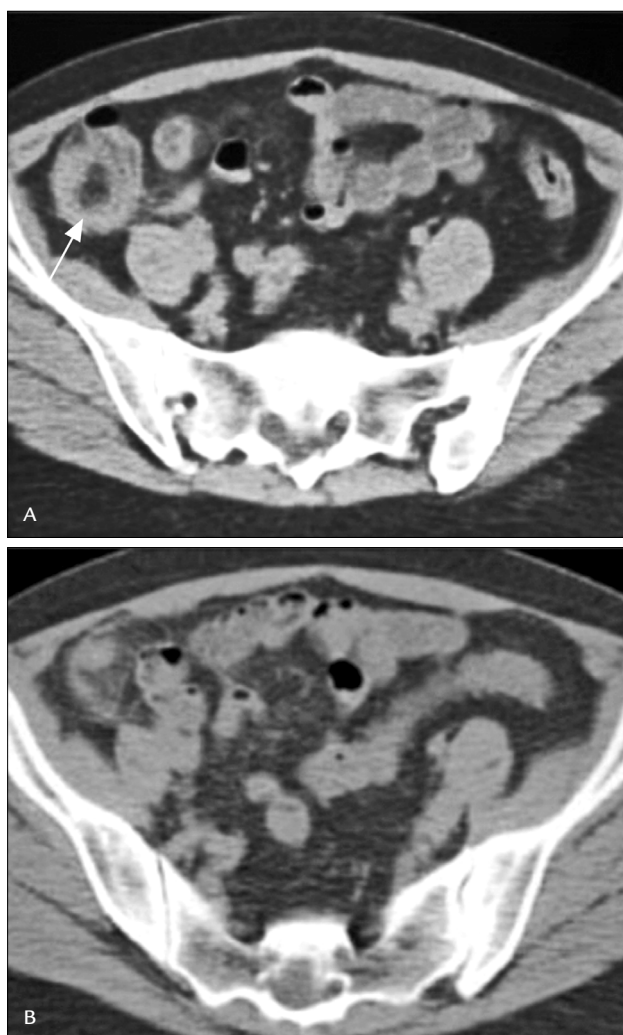


FIGURE 3 Computed Tomography. Acute appendicitis. (A) Thickening of the cecum (arrow), (B) blurring of peritoneal fat and thickening of the appendix.

Available at: http://www.scielo.br/scielo.php?pid=S010039842007000300012&script=sci_arttext.

without limiting diagnostic performance.^{39,41} A digital abdominal CT protocol with a preparation of intravenous and oral contrast, especially for the visualization of the appendix, may also be used but is associated with increased fetal exposure to radiation (20 to 40 mGy).^{40,42}

CT is indicated when the clinical findings and ultrasound results are inconclusive and MRI is not available, given the proven diagnostic value of CT in non-pregnant persons: overall sensitivity of 94% (CI 95% 91-95%), specificity of 95% (CI 95% 93-96%), positive predictive value of 13.3% (CI 95% 9.9-17.9%) and negative predictive value of 0.09% (CI 95% 0.07-0.12%).⁴³

Data from studies of pregnant women are more limited. A meta-analysis of three retrospective studies on pregnant women reported the following sensitivity and specificity parameters, for CT in cases of normal or questionable ultrasound results: sensitivity 85.7% (CI 95% 63.7-96%) and specificity 97.4% (CI 95% 86.2-99.9%).⁴⁴ These studies included between 2 and 49 patients with appendicitis. In one study, negative laparotomy rates among patients who underwent (1) clinical examination alone, (2) clinical and ultrasound examination, and (3) clinical assessment, and ultrasound followed by CT were 54 (7/13) 36 (20/55) and 8% (1/13), respectively.⁴⁵

Differential diagnosis

Differential diagnosis of suspected acute appendicitis usually includes pathologies considered in non-pregnant people. In addition, the causes related to pregnancy leading to abdominal pain, fever, leukocytosis, nausea/vomiting, and changes in bowel function are to be considered.³⁵

The possibility of ectopic pregnancy should be excluded for any woman with a positive pregnancy test and pain in the right lower quadrant.³⁵

Indigestion, bowel irregularity, nausea and/or vomiting, and malaise are common symptoms for appendicitis and normal early pregnancy. In appendicitis, nausea and vomiting, if they occur, happen after the onset of pain, while the nausea and vomiting of pregnancy are not associated with pain.³⁵

Round ligament pain is a common cause of light pain in the right lower quadrant in early pregnancy, but is not associated with other symptoms and is not progressive.³⁵

Pyelonephritis is more common in pregnant women than in non-pregnant women. Pregnant women with pain on the right side, fever, leukocytosis and leukocyturia may be treated for pyelonephritis without investigation, where the effective diagnosis of appendicitis may be delayed.³⁵

In the second half of pregnancy, pre-eclampsia and HELLP syndrome may be associated with nausea, vomit-

ing and abdominal pain, but in contrast to appendicitis, the pain is usually in the upper right quadrant or epigastric; hypertension is usually present and fever and leukocytosis are atypical.³⁵

Premature detachment of the placenta and uterine rupture are associated with median or lateral lower abdominal pain. Unlike appendicitis, both diagnoses are often associated with vaginal bleeding, changes in fetal heart rate and significant increase of the uterine tonus (stiffness).³⁵

In postpartum patients, ovarian vein thrombophlebitis (OVT) should be considered. Symptoms usually occur within one week of birth, and symptoms may include fever and abdominal pain and tenderness localized to the right, if the right ovarian vein is affected. Nausea and other gastrointestinal symptoms may occur but are generally mild, which may be useful in distinguishing between OVT on the right side and appendicitis.³⁵

DISCUSSION

Appendectomy

The treatment of acute appendicitis is appendectomy, which is curative. Perioperative antibiotics should cover Gram-negative and Gram-positive bacteria (for example, second generation cephalosporin) and also anaerobes (e.g. metronidazole or clindamycin). Antibiotic therapy alone is not recommended as it is associated with poor outcomes in the short and long term, with minimum data on pregnant patients.⁴⁶ Despite a recent meta-analysis published in the British Medical Journal suggesting that antibiotic therapy may be effective in patients with uncomplicated appendicitis, these data cannot be extrapolated to pregnant women.⁴⁷

Immediate diagnosis and surgery are recommended, since surgical intervention delayed for more than 24 hours after onset of symptoms increases the risk of perforation,^{2,29} which occurs in 14 to 43% of such patients. Maternal morbidity after appendectomy is comparable to that of non-pregnant women,⁴⁶ except in patients in whom the appendix perforates. The risk of fetal loss is increased when the appendix perforates (fetal loss 36 *versus* 1.5% without perforation)⁴⁸ or when there is a generalized peritonitis or abscess (fetal loss 6 *versus* 2%, premature delivery 11 *versus* 4%).⁴⁸

Given the difficulties in the clinical diagnosis of appendicitis and significant risk of fetal death in cases of appendicitis with perforation, a higher negative laparotomy rate (from 20 to 35%) compared to non-pregnant women is generally considered acceptable. Aggressive use of radiologic imaging, magnetic resonance imaging (MRI) and computerized tomography (CT) has the potential to

reduce the incidence of negative appendectomy. There is some evidence suggesting that the higher negative laparotomy rate in pregnant women is associated, at least in part, to a reluctance to perform the pre-operative CT in such patients.^{45,49}

A seemingly normal appendix must be removed for histological examination, as it may then reveal acute inflammation; excision avoids the potential for further evaluation, and intervention for suspected appendicitis and appendectomy is associated with a very low risk of complications.³⁵

Cesarean section is rarely indicated at the time of appendectomy. For patients who remain pregnant, the risk of dehiscence of the appendectomy incision during labor and vaginal delivery should not be increased when the aponeurosis is properly approximated.⁶

Management of a perforated appendix depends on the nature of the perforation: free *versus* locked. Free perforation may cause intraperitoneal dissemination of purulent and/or fecal material. Such patients are usually very serious cases and may be septic, which exposes them to increased risk of premature birth and fetal loss.⁴⁸ Urgently laparotomy is needed for appendectomy with thorough washing and drainage of the peritoneal cavity.⁴⁸

Non-pregnant patients who have a long duration of symptoms (over five days) and have been diagnosed with a perforation contained by the omentum, may initially be treated with antibiotics, intravenous fluids, bowel rest and careful monitoring. These patients often have a palpable mass on physical examination and imaging may reveal a phlegmon or abscess. Many will not respond to nonsurgical treatment given that the inflammatory process of the appendix has been blocked. Furthermore, immediate surgery in patients with long-term symptoms and phlegmon formation is associated with increased morbidity, as appendectomy may require extensive dissection in such cases, which can lead to damage to adjacent structures. Complications such as abscess or postoperative enterocutaneous fistula may arise, requiring ileocelectomy or cecostomy. Because of these potential complications, a non-surgical approach is a reasonable option if the patient progresses well. However, studies supporting this approach in pregnant women are scarce^{44,50} and therefore it is not a recommended alternative.

Surgical approach

When the diagnosis is relatively certain, appendectomy is suggested to be effected through a transverse incision in McBurney's point or, more commonly, on the point of maximum sensitivity.^{11,12} When the diagnosis is less cer-

tain, an umbilical midline vertical incision is recommended, since it allows for proper exposure of the abdomen for the diagnosis and treatment of surgical conditions that mimic appendicitis. A vertical incision can also be used for a Cesarean section, if subsequently necessary, for the usual obstetrical indications. It is prudent to minimize traction and handling of the uterus, although an association between these maneuvers and prematurity is not proven.¹¹

In relation to laparoscopic appendectomy, reports, case studies and small cohort studies have been published suggesting that this procedure can be performed successfully during all trimesters with few complications.^{3,51-62} Although long-term data on the safety and efficacy of laparoscopic appendectomy during pregnancy are limited, meta-analyses of observational studies, including a total of more than 500 laparoscopic appendectomies, have shown an increase in the fetal loss rate with this approach, when compared with open appendectomy.^{63,64} In a 2012 meta-analysis (11 studies, 3,415 women, 599 in the laparoscopic and 2,816 in the open group), the total relative risk of fetal loss for laparoscopic appendectomy against open surgery in pregnant women was OR 1.91, 95% CI 1.31 to 2.77%.⁶⁴ The largest of the studies included demonstrated that fetal loss rates in the laparoscopic and open surgery groups were 7.3 and 3.3%, respectively. All of the studies included in the systematic review were retrospective and did not take into account potential confounding factors, such as patient age, duration of pregnancy, complicated appendicitis, the surgeon's ability, etc. A subgroup analysis was also not conducted in relation to the anesthetic technique used in video-assisted surgeries, and this may be a factor that could make a difference and should be elucidated in future studies.⁶⁴

The Cochrane Library Systematic Review about laparoscopy in the management of acute abdominal pain in the lower abdomen of women of childbearing age⁶⁵ examined eight randomized clinical trials, in which laparoscopy was compared to open appendectomy. Laparoscopy was associated with an increased rate of specific diagnoses, but there was no evidence of a reduction in the rates of adverse events. In four randomized clinical trials, laparoscopy was compared to conservative clinical conduct. There was a significant difference favoring laparoscopy in specific diagnostic rates but there was no difference in adverse event rates. Therefore, the authors of the review concluded that the benefits of laparoscopy in women with nonspecific abdominal pain and suspected appendicitis include a high rate of specific diagnoses and low rate of removal of normal appendices, compared with the open technique. There was no evidence of an increase in adverse events with any of the strategies.⁶⁵

The decision to proceed with the laparoscopic approach should take into consideration the skills and experience of the surgeon, and clinical factors, such as the size of the pregnant uterus. Suggestions for modification of the laparoscopic technique during pregnancy include a slightly left decubitus position of the patient during the second half of pregnancy, avoiding the use of any instruments in the cervix, the use of open entry techniques or placement of trocars under direct vision, and limiting the intra-abdominal pressure levels equal to or lower than 12 mmHg.⁶⁶

The long-term prognosis for women undergoing appendectomy during pregnancy appears to be good, but the data are limited to small series of observations. Such women do not seem to be at increased risk of infertility or other complications.⁶⁷ There is little information about the long term outcome in the offspring. In a small series of appendectomies in all stages of pregnancy, the babies had normal development at age 13 to 17 months.⁶⁸

CONCLUSION

As the diagnosis of appendicitis can be difficult during pregnancy, imaging studies are recommended in order to reduce delays in surgery due to diagnostic uncertainty and reduce the rate of negative appendectomies. We recommend ultrasound exams in pregnant patients with suspected appendicitis. Appendicitis is diagnosed if a non-compressible tubular structure is displayed in the lower right quadrant, with a maximum diameter greater than 6mm. If clinical and ultrasound findings are inconclusive, magnetic resonance imaging (MRI) is indicated when available, given that it prevents fetal exposure to ionizing radiation and has performed well in the diagnosis of disorders in the lower abdomen. Computed tomography (CT) may be performed when MRI is not available, due to its proven value in non-pregnant individuals. The decision to perform laparotomy should be based on clinical findings, diagnostic imaging and clinical evaluation. Delays over 24 hours for intervention increase the risk of perforation. When the diagnosis is relatively certain, appendectomy is suggested to be effected through an incision on the point of maximum sensitivity (Grade 2C). When the diagnosis is less certain, we suggest a vertical incision in the lower midline (Grade 2C).

RESUMO

Apêndicite aguda na gestação: revisão de literatura.

Introdução: suspeita de apêndicite é a indicação mais comum de cirurgia para condições não obstétricas durante a gravidez e ocorre em cerca de 1:500 a 1:635 gestações por ano. Ocorre com mais frequência no segundo trimestre da

gestação. A apendicite aguda é o problema cirúrgico geral mais comum encontrado durante a gravidez.

Método: revisão de literatura com pesquisa de artigos científicos por meio dos unitermos “apendicite aguda” e “gestação” nas bases de dados PubMed, Lilacs/SciELO, Scopus, Biblioteca Cochrane e Uptodate.

Resultados: as manifestações clínicas da apendicite são semelhantes às de mulheres não grávidas; no entanto, pode ocorrer a apresentação não clássica, o que pode dificultar o diagnóstico, devendo ser subsidiado por exames de imagem.

Discussão: o diagnóstico clínico deve ser fortemente suscitado em mulheres grávidas com achados clássicos, como dor abdominal que migra para o quadrante inferior direito. O principal objetivo da imagem é reduzir atrasos na intervenção cirúrgica decorrentes da incerteza diagnóstica. Um objetivo secundário é o de reduzir, mas não eliminar, a taxa de apendicetomia negativa. O diagnóstico diferencial de suspeita de apendicite aguda inclui patologias geralmente consideradas em pessoas não grávidas.

Conclusão: o exame de imagem de primeira escolha é a ultrassonografia, podendo-se utilizar a ressonância nuclear magnética quando aquela não for conclusiva, e, em último caso, a tomografia computadorizada. O tratamento indicado permanece sendo a apendicetomia por laparotomia, uma vez que a viabilidade da cirurgia videoassistida ainda permanece controversa.

Palavras-chave: apendicite, gravidez, complicações na gravidez.

REFERENCES

- Guttman R, Goldman RD, Koren G. Appendicitis during pregnancy. *Can Fam Physician*. 2004;50:355-7.
- Bickell NA, Aufses AH Jr, Rojas M, Bodian C. How time affects the risk of rupture in appendicitis. *J Am Coll Surg*. 2006;202(3):401-6.
- Andersen B, Nielsen TF. Appendicitis in pregnancy: diagnosis, management and complications. *Acta Obstet Gynecol Scand*. 1999;78(9):758-62.
- Al-Qudah MS, Amr M, Sroujeh A, Issa A. Appendectomy in pregnancy: the experience of a university hospital. *J Obstet Gynaecol*. 1999;19(4):362-4.
- Mourad J, Elliott JP, Erickson L, Lisboa L. Appendicitis in pregnancy: new information that contradicts long-held clinical beliefs. *Am J Obstet Gynecol*. 2000;182(5):1027-9.
- Mazze RI, Källén B. Appendectomy during pregnancy: a Swedish registry study of 778 cases. *Obstet Gynecol*. 1991;77(6):835-40.
- Birnbaum BA, Wilson SR. Appendicitis at the millennium. *Radiology*. 2000;215(2):337-48.
- Lee SL, Walsh AJ, Ho HS. Computed tomography and ultrasonography do not improve and may delay the diagnosis and treatment of acute appendicitis. *Arch Surg*. 2001;136(5):556-62.
- Chung CH, Ng CP, Lai KK. Delays by patients, emergency physicians, and surgeons in the management of acute appendicitis: retrospective study. *Hong Kong Med J*. 2000;6(3):254-9.
- Richards C, Daya S. Diagnosis of acute appendicitis in pregnancy. *Can J Surg*. 1989;5(32):358-60.
- Hodjati H, Kazerooni T. Location of the appendix in the gravid patient: a re-evaluation of the established concept. *Int J Gynaecol Obstet*. 2003; 81(3):245-7.
- Popkin CA, Lopez PP, Cohn SM, Brown M, Lynn M. The incision of choice for pregnant women with appendicitis is through McBurney's point. *Am J Surg*. 2002;183(1):20-2.
- Oto A, Srinivasan PN, Ernst RD, Koroglu M, Cesani F, Nishino T, et al. Revisiting MRI for appendix location during pregnancy. *AJR Am J Roentgenol*. 2006;186(3):883-7.
- Pates JA, Avendano TC, Avendano TC, McIntire DD, Twickler DM. The appendix in pregnancy: confirming historical observations with a contemporary modality. *Obstet Gynecol*. 2009;114(4):805-8.
- McBurney C. Experience with early operative interference in cases of disease of the vermiform appendix. *NY Med J*. 1889;50:676.
- Cunningham FG, McCubbin JH. Appendicitis complicating pregnancy. *Obstet Gynecol*. 1975;45(4):415-20.
- Sivanesaratnam V. The acute abdomen and the obstetrician. *Baillieres Best Pract Res Clin Obstet Gynaecol*. 2000;14(1):89-102.
- Mahmoodian S. Appendicitis complicating pregnancy. *South Med J*. 1992;85(1):19-24.
- Coleman C, Thompson JE Jr, Bennion RS, Schmit PJ. White blood cell count is a poor predictor of severity of disease in the diagnosis of appendicitis. *Am Surg*. 1998;64(10):983-5.
- Tehrani HY, Petros JG, Kumar RR, Chu Q. Markers of severe appendicitis. *Am Surg*. 1999;65(5):453-5.
- Thompson MM, Underwood MJ, Dookeran KA, Lloyd DM, Bell PR. Role of sequential leucocyte counts and C-reactive protein measurements in acute appendicitis. *Br J Surg*. 1992;79(8):822-4.
- Lurie S, Rahamim E, Piper I, Golan A, Sadan O. Total and differential leukocyte counts percentiles in normal pregnancy. *Eur J Obstet Gynecol Reprod Biol*. 2008;136(1):16-9.
- Tundidor Bermúdez AM, Amado Diéguez JA, Montes de Oca Mastrapa JL. Manifestaciones urológicas de la apendicitis aguda. *Arch Esp Urol*. 2005;58(3):207-12.
- Puskar D, Bedalov G, Fridrih S, Vuckovic I, Banek T, Pasini J. Urinalysis, ultrasound analysis, and renal dynamic scintigraphy in acute appendicitis. *Urology*. 1995;459(1):108-12.
- Sand M, Bechara FG, Holland-Letz T, Sand D, Mehnert G, Mann B. Diagnostic value of hyperbilirubinemia as a predictive factor for appendiceal perforation in acute appendicitis. *Am J Surg*. 2009;198(2):193-8.
- Wang PI, Chong ST, Kielar AZ, Kelly AM, Knoepp UD, Mazza MB, et al. Imaging of pregnant and lactating patients: part 2, evidence-based review and recommendations. *AJR Am J Roentgenol*. 2012;198(4):785-92.
- Barloon TJ, Brown BP, Abu-Yousef MM, Warnouck N, Berbaum KS. Sonography of acute appendicitis in pregnancy. *Abdom Imaging*. 1995;20(2):149-51.
- Lim HK, Bae SH, Seo GS. Diagnosis of acute appendicitis in pregnant women: value of sonography. *AJR Am J Roentgenol*. 1992;159(3):539-42.
- Yilmaz HG, Akgun Y, Bac B, Celik Y. Acute appendicitis in pregnancy--risk factors associated with principal outcomes: a case control study. *Int J Surg*. 2007;5(3):192-7.
- Pedrosa I, Levine D, Eyvazzadeh AD, Siewert B, Ngo L, Rofsky NM. MR imaging evaluation of acute appendicitis in pregnancy. *Radiology*. 2006;238(3):891-9.
- Cobben LP, Groot I, Haans L, Blickman JG, Puylaert J. MRI for clinically suspected appendicitis during pregnancy. *AJR Am J Roentgenol*. 2004;183(3):671-5.
- Israel GM, Malguria N, McCarthy S, Copel J, Weinreb J. MRI vs. ultrasound for suspected appendicitis during pregnancy. *J Magn Reson Imaging*. 2008;28(2):428-33.
- Lehnert BE, Gross JA, Linnau KF, Moshiri M. Utility of ultrasound for evaluating the appendix during the second and third trimester of pregnancy. *Emerg Radiol*. 2012;19(4):293-9.
- Williams R, Shaw J. Ultrasound scanning in the diagnosis of acute appendicitis in pregnancy. *Emerg Med J*. 2007;24(5):359-60.
- Barth WH Jr, Goldberg JE. Acute appendicitis in pregnancy. Uptodate. [cited 2014 Feb 28]. Available at: <http://uptodate.com>.
- Long SS, Long C, Lai H, Macura KJ. Imaging strategies for right lower quadrant pain in pregnancy. *AJR Am J Roentgenol*. 2011;196(1):4-12.
- Kanal E, Barkovich AJ, Bell C, Borgstede JP, Bradley WG Jr, Froelich JW, et al. ACR guidance document for safe MR practices: 2007. *AJR Am J Roentgenol*. 2007;188(6):1447-74.
- The American College of Radiology. ACR Appropriateness Criteria: Right lower quadrant pain-suspected appendicitis. AHRQ National Guidelines Clearinghouse. [cited 2014 Feb 28]. Available at: <http://guidelines.gov/content.aspx?id=23816>.

39. Ames Castro M, Shipp TD, Castro EE, Ouzounian J, Rao J. The use of helical computed tomography in pregnancy for the diagnosis of acute appendicitis. *Am J Obstet Gynecol.* 2001;184(5):954-7.
40. Hurwitz LM, Yoshizumi T, Reiman RE, Goodman PC, Paulson EK, Frush DP, et al. Radiation dose to the fetus from body MDCT during early gestation. *AJR Am J Roentgenol.* 2006;186(3):871-6.
41. Wagner LK, Huda W. When a pregnant woman with suspected appendicitis is referred for a CT scan, what should a radiologist do to minimize potential radiation risks? *Pediatr Radiol.* 2004;34(7):589-90.
42. Damilakis J, Perisinakis K, Voloudaki A, Gourtsoyiannis N. Estimation of fetal radiation dose from computed tomography scanning in late pregnancy: depth-dose data from routine examinations. *Invest Radiol.* 2000;35(9):527-33.
43. Terasawa T, Blackmore CC, Bent S, Kohlwes RJ. Systematic review: computed tomography and ultrasonography to detect acute appendicitis in adults and adolescents. *Ann Intern Med.* 2004;141(7):537-46.
44. Basaran A, Basaran M. Diagnosis of acute appendicitis during pregnancy: a systematic review. *Obstet Gynecol Surv.* 2009;64(7):481-8.
45. Wallace CA, Petrov MS, Soybel DI, Ferzoco SJ, Ashley SW, Tavakkolizade HA. Influence of imaging on the negative appendectomy rate in pregnancy. *J Gastrointest Surg.* 2008;12(1):46-50.
46. Young BC, Hamar BD, Levine D, Roqué H. Medical management of ruptured appendicitis in pregnancy. *Obstet Gynecol.* 2009;114:453-6.
47. Varadhan KK, Neal KR, Lobo DN. Safety and efficacy of antibiotics compared with appendectomy for treatment of uncomplicated acute appendicitis: meta-analysis of randomised controlled trials. *BMJ.* 2012;344:e2156.
48. Silvestri MT, Pettker CM, Brousseau EC, Dick MA, Ciarleglio MM, Erekson EA. Morbidity of appendectomy and cholecystectomy in pregnant and nonpregnant women. *Obstet Gynecol.* 2011;118(6):1261-70.
49. McGory ML, Zingmond DS, Tillou A, Hiatt JR, Ko CY, Cryer HM. Negative appendectomy in pregnant women is associated with a substantial risk of fetal loss. *J Am Coll Surg.* 2007;205(4):534-40.
50. Ito K, Ito H, Whang EE, Tavakkolizadeh A. Appendectomy in pregnancy: evaluation of the risks of a negative appendectomy. *Am J Surg.* 2012;203(2):145-50.
51. Vasireddy A, Atkinson S, Shennan A, Bewley S. Management of appendicitis. Surgical management remains best option during pregnancy. *BMJ.* 2012;344:e3575.
52. Curet MJ, Allen D, Josloff RK, Pitcher DE, Curet LB, Miscall BG, et al. Laparoscopy during pregnancy. *Arch Surg.* 1996;131(5):546-50.
53. Gurbuz AT, Peetz ME. The acute abdomen in the pregnant patient. Is there a role for laparoscopy? *Surg Endosc.* 1997;11(2):98-102.
54. Affleck DG, Handrahan DL, Egger MJ, Price RR. The laparoscopic management of appendicitis and cholelithiasis during pregnancy. *Am J Surg.* 1999;178(6):523-9.
55. Wu JM, Chen KH, Lin HF, Tseng LM, Tseng SH, Huang SH, et al. Laparoscopic appendectomy in pregnancy. *J Laparoendosc Adv Surg Tech A.* 2005;15(5):447-50.
56. Donkervoort SC, Boerma D. Suspicion of acute appendicitis in the third trimester of pregnancy: pros and cons of a laparoscopic procedure. *JLSLS.* 2011;15(3):379-83.
57. Holzer T, Pellegrinelli G, Morel P, Toso C. Appendectomy during the third trimester of pregnancy in a 27-year old patient: case report of a "near miss" complication. *Patient Saf Surg.* 2011;5(1):11.
58. Machado NO, Grant CS. Laparoscopic appendectomy in all trimesters of pregnancy. *JLSLS.* 2009;13(3):384-90.
59. Lemieux P, Rheume P, Levesque I, Biyold E, Brochu G. Laparoscopic appendectomy in pregnant patients: a review of 45 cases. *Surg Endosc.* 2009;23(8):17015.
60. Sador E, Telem DA, Arora M, Butala P, Nguyen SQ, Divino CM. Laparoscopy: a safe approach to appendicitis during pregnancy. *Surg Endosc.* 2010;24(4):383-9.
61. Hannan MJ, Hoque MM, Begum LN. Laparoscopic appendectomy in pregnant women: experience in Chittagong, Bangladesh. *World J Surg.* 2012;36(4):767-70.
62. Kirshtein B, Perry ZH, Avinoach E, Mizrahi S, Lantsberg I. Safety of laparoscopic appendectomy during pregnancy. *World J Surg.* 2009;33(3):475-80.
63. Jeong JS, Ryu DH, Yun HY, Jeong EH, Choi JW, Jang LC. Laparoscopic appendectomy is a safe and beneficial procedure in pregnant women. *Surg Laparosc Endosc Percutan Tech.* 2011;21(1):24-7.
64. Walsh CA, Tang T, Walsh SR. Laparoscopic versus open appendectomy in pregnancy: a systematic review. *Int J Surg.* 2008;6(4):339-44.
65. Gaitán HG, Reveiz L, Farquhar C. Laparoscopy for the management of acute lower abdominal pain in women of childbearing age. *The Cochrane Library,* 2011;19(1):CD007683.
66. Wilasrusmee C, Sukrat B, McEvoy M, Attia J, Thakkinstian A. Systematic review and meta-analysis of safety of laparoscopic versus open appendectomy for suspected appendicitis in pregnancy. *Br J Surg.* 2012;99(11):1470-8.
67. Al-Fozan H, Tulandi T. Safety and risks of laparoscopy in pregnancy. *Curr Opin Obstet Gynecol.* 2002;14(4):375-9.
68. Viktrup L, Hée P. Fertility and long-term complications four to nine years after appendectomy during pregnancy. *Acta Obstet Gynecol Scand.* 1998;77(7):746-50.