

***Strongyloides stercoralis* hyperinfection: an unusual cause of gastrointestinal bleeding**

HIPERINFECÇÃO POR *STRONGYLOIDES STERCORALIS*: UMA CAUSA INCOMUM DE HEMORRAGIA DIGESTIVA

JULIANA TRAZZI RIOS¹, MATHEUS CAVALCANTE FRANCO^{2*}, BRUNO DA COSTA MARTINS³, ELISA RYOKA BABA¹, ADRIANA VAZ SAFATLE-RIBEIRO⁴, PAULO SAKAI⁵, FELIPE ALVES RETES⁶, FAUZE MALUF-FILHO⁴

¹MD – Collaborating Physician of the Endoscopy Service, Instituto do Câncer de São Paulo (ICESP), São Paulo, SP, Brazil

²MD, MSc – Collaborating Physician of the Endoscopy Service, ICESP São Paulo, SP, Brazil

³MD, MSc – Assistant Physician of the Endoscopy Service, ICESP, São Paulo, SP, Brazil

⁴MD, PhD – Post-doctoral Professor, Faculdade de Medicina, Universidade de São Paulo (FMUSP), São Paulo, SP, Brazil

⁵MD, PhD – Associate Professor, FMUSP São Paulo, SP, Brazil

⁶MD – Assistant Physician of the Endoscopy Service, ICESP São Paulo, SP, Brazil

Study conducted at Instituto do Câncer de São Paulo (ICESP), Faculdade de Medicina, Universidade de São Paulo (USP), São Paulo, SP, Brazil

Article received: 9/4/2014

Accepted for publication: 9/9/2014

*Correspondence:

Address: Av. Dr. Arnaldo, 251
Sumaré

São Paulo, SP – Brazil

Postal code: 01255-000

mcavalcantefranco@gmail.com

<http://dx.doi.org/10.1590/1806-9282.61.04.311>

SUMMARY

Strongyloidiasis is a parasitic disease that may progress to a disseminated form, called hyperinfection syndrome, in patients with immunosuppression. The hyperinfection syndrome is caused by the wide multiplication and migration of infective *larvae*, with characteristic gastrointestinal and/or pulmonary involvement. This disease may pose a diagnostic challenge, as it presents with nonspecific findings on endoscopy.

Keywords: gastrointestinal hemorrhage, gastrointestinal endoscopy, parasitic diseases, *Strongyloides stercoralis*.

INTRODUCTION

Strongyloides stercoralis is a parasite endemic of tropical and subtropical regions, with the capacity of completing its life cycle within its host through an auto-infective cycle. The low level of suspicion for the diagnosis of strongyloidiasis can lead physicians to miss or delay the final diagnosis.¹

CASE REPORT

A 76-year-old male, resident of São Paulo, Brazil, was referred to the hospital in May 2014, with a 2-month history of nausea, vomiting, anorexia, and 10-lb weight loss. Past medical history of metastatic castration-resistant prostate cancer, with recent palliative treatment with chemotherapy, and corticosteroids.

Laboratory tests during admission revealed mild anemia (hemoglobin: 11.1 mg/dL), normal total leukocyte count, normal peripheral blood eosinophil count and an increased C-reactive protein. Upper gastrointestinal endoscopy (UGE) showed gastric mucosal erythema, areas of atrophy, intestinal metaplasia, and pyloric stenosis due to cicatricial retraction. Duodenal mucosa presented a crispy surface with enlarged and rigid villousities, diffuse erythema, edema and friability (Figures 1 and 2). Biopsy

from duodenum revealed larval form of *Strongyloides stercoralis* in mucosal crypts (Figure 3). Patient was treated with ivermectin for 2 days, and with high doses of proton pump inhibitors (PPI).

During hospitalization, he presented massive melena and hemorrhagic shock. Fluids and blood transfusion were started. UGE repeated during the gastrointestinal bleeding showed diffuse hemorrhagic duodenitis and bleeding erosions, which were endoscopically treated with argon plasma coagulation and hemoclips. Patient died after 11 days of hospitalization from *Strongyloides stercoralis* hyperinfection syndrome and sepsis.

DISCUSSION

Strongyloidiasis is often an asymptomatic infection of upper small intestine. Immunosuppression may lead to hyperinfection with dissemination of *S. stercoralis* to almost all organs, with bacterial sepsis.² The hyperinfection syndrome is frequently associated with corticosteroid administration, and other immunosuppressive conditions, such as malignancies.³ This disease is potentially lethal, with mortality rates up to 87%, and it is characterized by gastrointestinal and/or pulmonary involvement.⁴ Clinical manifestations

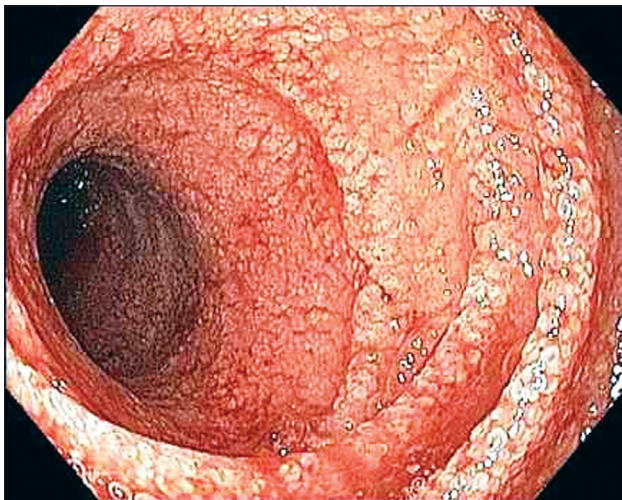


FIGURE 1 Severe bulbo-duodenitis with mild diffuse bleeding.

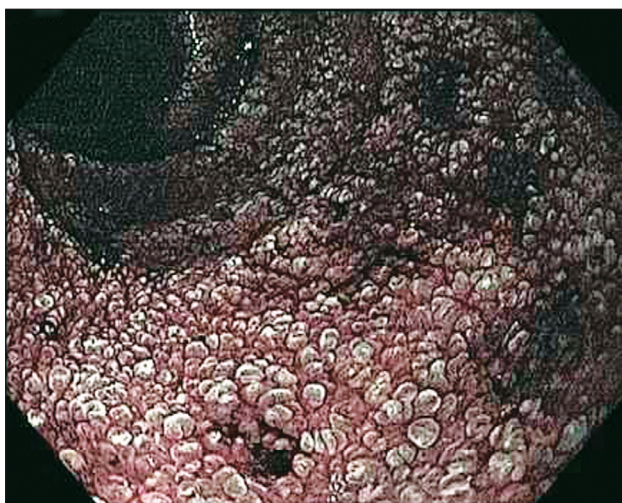

FIGURE 2 At close inspection with narrow-band imaging (NBI), enlarged and rigid duodenal villousities are seen.

of gastrointestinal impairment include abdominal pain, diarrhea, bleeding, nausea and vomiting. Diagnosis is challenging due to non-specific clinical features, and can be done by biopsy of suspicious changes at upper endoscopy.⁵

RESUMO

Hiperinfecção por *Strongyloides stercoralis*: uma causa incomum de hemorragia digestiva

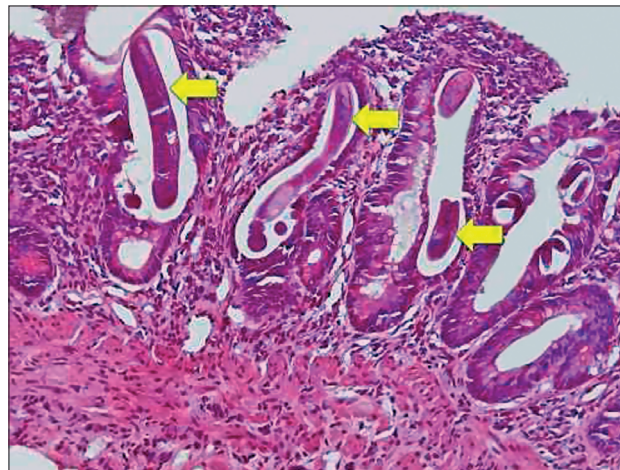


FIGURE 3 Duodenal biopsy showing *Strongyloides stercoralis* larval infection in the mucosal crypts (arrow) (HE).

A estrogiloidíase é uma parasitose que pode evoluir para uma forma disseminada, denominada síndrome de hiperinfecção, nos pacientes em estados de imunossupressão. A síndrome de hiperinfecção é ocasionada pela grande multiplicação e migração de larvas infectantes, com envolvimento gastrointestinal e/ou pulmonar característico. Essa doença pode representar um desafio diagnóstico, pois apresenta-se em achados inespecíficos à endoscopia.

Palavras-chave: hemorragia gastrointestinal, endoscopia gastrointestinal, doenças parasitárias, *Strongyloides stercoralis*.

REFERENCES

1. Agrawal V, Agarwal T, Ghoshal UC. Intestinal strongyloidiasis: a diagnosis frequently missed in the tropics. *Trans R Soc Trop Med Hyg.* 2009; 103(3):242-6.
2. Lim S, Katz K, Krajden S, Fuksa M, Keystone JS, Kain KC. Complicated and fatal *Strongyloides* infection in Canadians: risk factors, diagnosis and management. *CMAJ.* 2004; 171(5):479-84.
3. Machado ER, Teixeira EM, Gonçalves-Pires MDRF, Loureiro ZM, Araújo RA, Costa-Cruz JM. Parasitological and immunological diagnosis of *Strongyloides stercoralis* in patients with gastrointestinal cancer. *Scand J Infect Dis.* 2008; 40(2):154-8.
4. Marcos LA, Terashima A, Dupont HL, Gotuzzo E. *Strongyloides* hyperinfection syndrome: an emerging global infectious disease. *Trans R Soc Trop Med Hyg.* 2008; 102(4):314-8.
5. Keiser PB, Nutman TB. *Strongyloides stercoralis* in the immunocompromised population. *Clin Microbiol Rev.* 2004; 17(1):208-17.