

Development of exclusively cutaneous sarcoidosis in patient with rheumatoid arthritis during treatment with etanercept

MARCELLA AMARAL HORTA BARBOSA VIEIRA^{1*}, MARIA ISABEL RAMOS SARAIVA², LARISSA KARINE LEITE DA SILVA²,
RAFAEL CAVANELLAS FRAGA³, PRISCILA KAKIZAKI⁴, NEUSA YURIKO SAKAI VALENTE⁵

¹MD (Graduate degree in Dermatology), Resident in Dermatology, São Paulo, SP, Brazil

²Resident in Dermatology, Hospital do Servidor Público Estadual (HSPE), São Paulo, SP, Brazil

³Dermatologist, Specialist degree from the HSPE, São Paulo, SP, Brazil

⁴Dermatologist, Preceptor/Clinical Instructor, Instituto de Assistência Médica ao Servidor Público Estadual (IAMSPE), São Paulo, SP, Brazil

⁵PhD in Dermatology from Faculdade de Medicina da Universidade de São Paulo (FMUSP). Head Dermatologist at the HSPE. Assistant Physician, Dermatology Service, Hospital das Clínicas, FMUSP São Paulo, SP, Brazil

SUMMARY

We report the case of a patient with rheumatoid arthritis who, after 2 months of treatment with etanercept, showed disseminated asymptomatic violaceous papules. Biopsy of the skin lesion showed chronic granulomatous dermatitis with negative staining for fungi and acid-fast bacilli (AFB). After discontinuation of etanercept, the patient's condition improved. Although apparently paradoxical, cases of cutaneous and systemic sarcoidosis after anti-TNF medications have been reported in the literature, with very few cases presenting exclusive cutaneous involvement.

Keywords: sarcoidosis, tumor necrosis factor-alpha, chronic granulomatous disease, rheumatoid arthritis.

Study conducted at Hospital do Servidor Público Estadual (HSPE), São Paulo, SP, Brazil

Article received: 6/16/2015
Accepted for publication: 11/8/2015

*Correspondence:
Address: Rua Borges Lagoa, 1755
São Paulo, SP – Brazil
Postal code: 04038-004
marcella_ahb@hotmail.com

<http://dx.doi.org/10.1590/1806-9282.62.08.718>

INTRODUCTION

Sarcoidosis is a systemic granulomatous disease of unknown etiology.¹ It commonly affects the lungs, lymphoid system, and skin.² Diagnosis is based on clinical presentation and histopathological findings.³

Tumor necrosis factor is produced by inflammatory cells such as macrophages, keratinocytes, and T helper 1 (Th1) lymphocytes.⁴ It is implicated in the pathogenesis of granulomatous inflammatory diseases. Granuloma formation requires a Th1 pattern of response involving macrophages and CD4+ T lymphocytes activated with interferon (IFN) and IL-2 secretion, and macrophage activation causes increased production of tumor necrosis factor-alpha (TNF- α). There is a positive correlation between TNF- α levels and sarcoidotic disease activity.^{3,4}

Thus, sarcoidosis would be effectively treated with TNF- α blockers. However, cases of cutaneous, pulmonary, and ocular sarcoidosis due to an unexpected and paradoxical effect of these medications have been reported.^{3,4} One of the hypotheses that have been reported is that the increased incidence of infections treated with anti-TNF- α could lead to the development of granulomas.⁵

We report the case of a patient who developed sarcoidotic skin lesions during treatment with etanercept

(ETN), without associated systemic manifestations. Similar cases reported in the literature are rare.

CASE REPORT

A 62-year-old female patient diagnosed with rheumatoid arthritis for 13 years, treated with etanercept for 4 months. Two months after the beginning of this immunobiological treatment, violaceous papules appeared, which were asymptomatic, diffuse throughout the trunk and proximal areas of the limbs, and the face (Figure 1). The patient reported fever coinciding with the onset of skin lesions, with no other associated symptoms. She denied comorbidities or the use of further medication. Histopathological examination of a lesion on the left shoulder revealed chronic granulomatous dermatitis (Figure 2). Staining for fungi and acid-fast bacilli yielded negative results. Blood count, lipid profile, blood glucose, renal and liver function were normal. A chest tomography was requested, but showed no signs of granulomatous disease. Tuberculin skin test was negative. We chose to switch from etanercept to abatacept, with progressive improvement in a few weeks until complete clearance of the lesion. The patient is still being monitored at the dermatology and rheumatology outpatient clinics, and she did not develop new lesions 8 months after

etanercept discontinuation. The current treatment is done with prednisone and abatacept.

DISCUSSION AND CONCLUSION

The observation of granulomatous disease during treatment with TNF- α blocking agents seems paradoxical. However, the temporal relationship between beginning of therapy/onset of disease and regression of lesions after discontinuation of treatment strongly suggests that the TNF- α blocker is involved with the development of a granuloma.⁶ Based on the clinical history, histopathology, and chronological sequence of events, our case report suggests the diagnosis of ETN-induced sarcoidosis.

Cases of sarcoidosis have been reported in the literature after use of TNF- α blockers. The use of anti-TNF

agents would result in increased T lymphocyte reactivity and imbalance of cytokines, altering the homeostasis of the immune system responsible for the formation and maintenance of granuloma.^{7,8} Diagnosis remains a challenge probably because the safety profile of TNF- α blockers is mainly directed to infections. This should be taken into account in case of lung symptoms and negative cultures. Angiotensin converting enzyme has a good sensitivity (90%) and may help in the diagnosis.⁹

In a systematic review, we observed that more cases of sarcoidosis have been reported as a consequence of therapy with ETN (soluble TNF- α fusion protein), compared with other TNF- α inhibitors such as infliximab (IFX) and adalimumab (ADA). This could be related to the different binding characteristics of each of the three

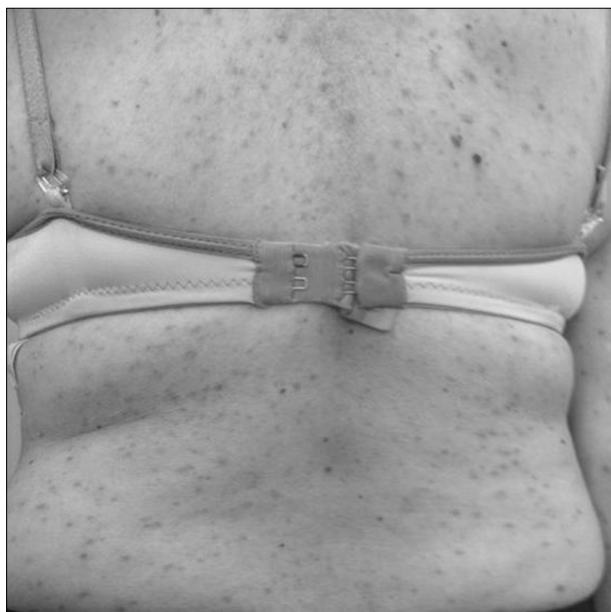


FIGURE 1 Numerous erythematous-violaceous papules on the back.

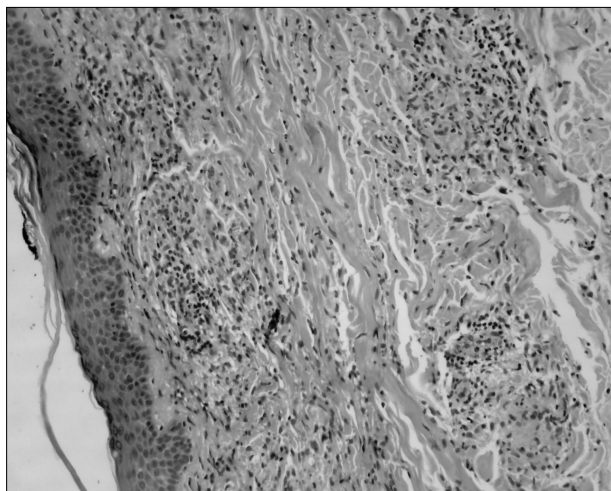


FIGURE 2 Epidermis slightly rectified. Dermis with epithelioid and multinucleated histiocytes forming granulomas.

TNF- α inhibitors (ETN, IFX, and ADA), since they present different clearances and binding avidities.⁴

ETN is a fusion protein that primarily neutralizes soluble TNF- α , with reduced binding activity to membrane TNF- α compared with IFX.^{6,10} Given that TNF- α is only partially neutralized by ETN, there may be a redistribution of bioavailable cytokines that travel to low concentration sites such as the lungs. A new stimulus could thus result in the formation of granulomas.⁶

In the literature review, to date, we have found only nine reported cases of sarcoidosis induced by TNF- α blockers, whose clinical presentation was exclusively cutaneous. The period between beginning of treatment and the onset of sarcoidosis ranged from 1 to 60 months. Cutaneous manifestations included papular eruptions, nodular eruptions (including facial nodules), scar lesions, and erythema nodosum. The non-cutaneous clinical manifestations reported included constitutional symptoms, hilar lymphadenopathy, pulmonary interstitial infiltrate, pulmonary nodules and micronodules, pleural effusion, uveitis, and hepatic involvement. Most cases involved organs other than the skin.⁴ In most cases, there was regression after discontinuation of anti-TNF- α therapy, with an average time of 4, 6 and 8 months for IFX, ADA, and ETN, respectively.¹¹

Thus, ETN may trigger cutaneous and/or systemic sarcoidosis, so that cutaneous manifestation may be the first or only manifestation of the disease. Physicians should be aware of this potential cutaneous and/or systemic adverse effect for early diagnosis and initiation of the appropriate therapy for each patient.⁴

RESUMO

Desenvolvimento de sarcoidose exclusivamente cutânea em paciente com artrite reumatoide, durante tratamento com etanercepte

Relata-se caso de uma paciente com artrite reumatoide que, após 2 meses de tratamento com o medicamento

imunobiológico anti-TNF- α etanercepte, apresentou quadro cutâneo compatível com sarcoidose. Notavam-se pápulas violáceas disseminadas e assintomáticas, cuja histopatologia revelou dermatite crônica granulomatosa, com pesquisa de fungos e bacilos álcool-ácido resistentes negativa. Após suspensão do etanercepte, houve regressão do quadro cutâneo. Apesar de paradoxal, têm sido relatados na literatura casos de sarcoidose cutânea e sistêmica após uso de medicações anti-TNF, sendo raríssimos os casos com acometimento cutâneo exclusivo.

Palavras-chave: sarcoidose, fator de necrose tumoral alfa, doença granulomatosa crônica, artrite reumatoide.

REFERENCES

1. Santos G, Sousa LE, João AM. Exacerbation of recalcitrant cutaneous sarcoidosis with adalimumab – a paradoxical effect? A case report. *An Bras Dermatol*. 2013; 88(6 Suppl 1):26-8.
2. Buss G, Cattin V, Spring P, Malinverni R, Gilliet M. Two cases of interferon-alpha-induced sarcoidosis Koebnerized along venous drainage lines: new pathogenic insights and review of the literature of interferon-induced sarcoidosis. *Dermatology*. 2013; 226(4):289-97.
3. Daïen CI, Monnier A, Claudepierre P, Constantin A, Eschard JP, Houvenagel E, et al. Club Rhumatismes et Inflammation (CRI). Sarcoid-like granulomatosis in patients treated with tumor necrosis factor blockers: 10 cases. *Rheumatology (Oxford)*. 2009; 48(8):883-6.
4. Lamrock E, Brown P. Development of cutaneous sarcoidosis during treatment with tumour necrosis alpha factor antagonists. *Australas J Dermatol*. 2012; 53(4):e87-90.
5. Dhaille F, Viseux F, Caudron A, Dadban A, Tributou C, Boumier P, et al. Cutaneous sarcoidosis occurring during anti-TNF-alpha treatment: report of two cases. *Dermatology*. 2010; 220(3):234-7.
6. Toussirot E, Pertuiser E, Kantelip B, Wendling D. Sarcoidosis occurring during anti-TNF- α treatment for inflammatory rheumatic diseases: report of two cases. *Clin Exp Rheumatol*. 2008; 26(3):471-5.
7. Wallis RS, Ehlers S. Tumor necrosis factor and granuloma biology: explaining the differential infection risk of etanercept and infliximab. *Semin Arthritis Rheum*. 2005; 34(Suppl 1):34-8.
8. Gifre L, Ruiz-Esquide V, Xaubet A, Gómez-Puerta JA, Hernández MV, Sanmartí R. Lung sarcoidosis induced by TNF antagonists in rheumatoid arthritis: a case presentation and a literature review. *Arch Bronconeumol*. 2011; 47(4):208-12.
9. Vigne C, Tebib JG, Pacheco Y, Coury F. Sarcoidosis: an underestimated and potentially severe side effect of anti-TNF-alpha therapy. *Joint Bone Spine*. 2013; 80(1):104-7.
10. Tong D, Manolios N, Howe G, Spencer D. New onset sarcoid-like granulomatosis developing during anti-TNF therapy: an under-recognised complication. *Intern Med J*. 2012; 42(1):89-94.
11. Fok KC, Ng WW, Henderson CJ, Connor SJ. Cutaneous sarcoidosis in a patient with ulcerative colitis on infliximab. *J Crohns Colitis*. 2012; 6(6):708-12.