

Hypopigmented mycosis fungoides with 20 years evolution*

*Micose fungóide hipopigmentar com 20 anos de evolução**

Rodrigo Pereira Duquia¹
Joel Schwartz⁴

Paulo Ricardo Martins Souza²
Auro Prochnau⁵

Roberto Lopes Gervini³
Hiram Larangeira de Almeida Jr⁶

Abstract: Hypopigmented mycosis fungoides is a rare variant of the cutaneous T-cell lymphoma, in which hypopigmented lesions are seen without the classical lesions. Only three cases are found in the Latin-American literature. We report the case of a 29-year-old black male patient, who first presented with these lesions 20 years ago. The treatment is similar to the classical forms of the disease: psoralen plus ultraviolet A (PUVA) and topical nitrogen mustard are most often used.

Keywords: Phototherapy; Hypopigmentation; Mycosis fungoides.

Resumo: A micose fungóide hipopigmentar é uma forma rara de linfoma cutâneo de células T, em que lesões hipopigmentadas ocorrem na ausência de lesões clássicas dessa neoplasia. Na literatura latino-americana existem apenas três casos; relata-se aqui o caso de um homem negro, de 29 anos com lesões há 20 anos. O tratamento é semelhante ao de outros tipos de linfomas T cutâneos, sendo o psoraleno mais ultravioleta A (Puva) e a mostarda nitrogenada tópica os mais relatados.

Palavras-chave: Fototerapia; Hipopigmentação; Micose fungóide.

Mycosis fungoides (MF) is defined as a neoplasm of the T-helper lymphocyte subset¹⁻³ primarily affecting the skin. It remains without extracutaneous manifestations for several years.

The typical form of this disease's presentation consists of three patterns: a premycotic stage with non-specific erythematous and scaling lesions, which recalls psoriasis and parapsoriasis. The second stage is characterized by the infiltration of pre-existing erythematous-squamous plaques, emergence of new infiltrated plaques and nodules. A third stage is identified by the appearance of tumors of various sizes

with an erythematous light-brown color, although initial tumor forms are rare.

In the pure hypopigmentary variant there do not occur any classic mycosis fungoides lesions.¹

A 29 year-old male patient presented with extensive hypochromic spots since nine year of age. The spots were slightly scaling in the bilateral gluteal region. In the region close to the thighs, they were not pruriginous. Similar lesions on the right arm improved after being exposed to the sun.

The dermatological examination showed hypochromic spots on the buttocks and in the region

Received on November 24, 2003.

Approved by the Consultive Council and accepted for publication on September 10, 2004.

* Study carried out at the Medical Dermatology Residency Service, Santa Casa de Porto Alegre, Posto G - Federal University of Rio Grande do Sul, Brazil.

¹ Dermatologist of Santa Casa de Porto Alegre (RS).

² Preceptor, Dermatology Service of Santa Casa de Porto Alegre (RS).

³ Head and Preceptor of the Dermatology Service of Santa Casa de Porto Alegre (RS).

⁴ Associate Professor, Faculty of Medicine, UFRGS (RS).

⁵ Dermatologist of Santa Casa de Porto Alegre (RS).

⁶ Adjunct Professor of Dermatology at Federal University of Pelotas and Catholic University of Pelotas (Masters degree course in Health and Behavior) (RS)

close to the thighs, with fine pityriasiform scaling. (Figure 1).

The histopathologic examination revealed the presence of acanthosis and atypical lymphocitary infiltrate in the upper reticular dermis and papillary dermis. Lymphocytes were seen to invade the epidermis, especially at the base where small groups (Pautier's microabscesses) would sometimes form.

Immunohistochemistry demonstrated that the epidermotropic lymphocytes were marked with CD 45 (Figure 2) and CD 8.

The therapy instituted was PUVA owing to several factors. It is one of the most described therapies in the literature,¹⁻⁵ and is easy to access at the service. In addition, PUVA was favored by the fact that the patient referred to a previous arm lesion, identical to the case on the buttocks, which improved after being exposed to the sun.

Hypopigmentary MF (HMF) was first described by Ryan in 1973, followed by Smith in 1978. In 1982, Breathnach in a pioneering move suggested that MF belongs to the differential diagnosis for hypochromic macules.⁶

The hypochromic variant has shown its own specific epidemiological characteristics in relation to the classical form. In addition to being rarer in white patients in relation to age, this variant is clear at the onset in young patients, and shows no male/female preference. In most cases, there was a quick response to treatment.

There exist few articles in the literature on this variant. Most articles are case reports or revisions thereof. This makes an adequate epidemiological analysis difficult. There also exist several patient reports concomitantly showing typical erythematous

lesions merely described as a hypochromic variant.⁷

Ardigó et al. demonstrated in their study that, of the seven patients assessed with HMF, five presented with CD4 lymphocyte infiltrate. In addition, they reported previously described cases in which the predominant phenotype was also CD4, contradicting some authors who have described a CD8 infiltrate as typical in these cases.⁷

Histologically, atrophy is absent. Moderate-to-severe exocytosis, tending toward weak epidermotropism, is a rare characteristic in premature MF.³

The clinical response in various studies has proved to be faster than in classical MF, irrespective of the therapy utilized. Recurrences have been frequent after periods of one to three years without maintenance therapy, but respond after reinitiating therapy.⁵

In the literature, various therapeutic options are described, such as ultraviolet radiation as a monotherapy, occlusive corticoid, electron bath, bis-chloronitrosourea (BCNU). But the most described and best assessed modalities were phototherapy with UVA and UVB, and topical nitrogen mustard.

Immunohistochemical findings manifested a higher frequency of CD8 cells in juvenile onset mycosis fungoides and in dark-skinned patients. In older light-skinned patients, CD4 lymphocyte infiltrates are frequent.^{1,8}

In 1999, Berti, while studying primary cutaneous lymphocytes with an aggressive behavior, identified CD8 as a bad prognosis factor due to dissemination to the central nervous system, lungs, testicles and oral mucosa.⁹

The T CD8 cell finding has been a controversial factor in relation to the prognosis, because in pagetoid reticulosis and lymphomatoid papulosis, known

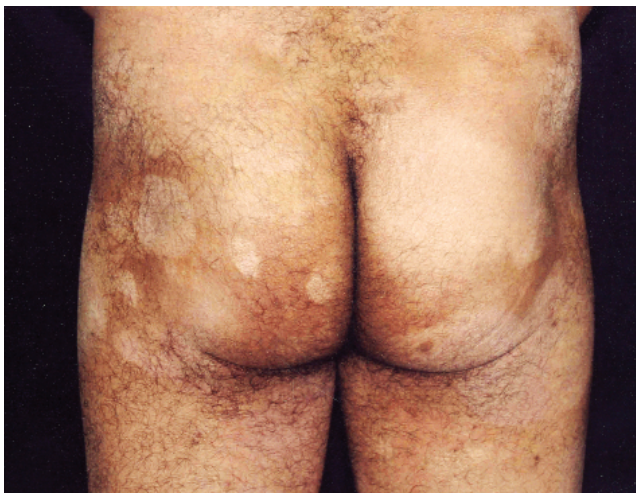

FIGURE 1: Hypochromic spots on the buttocks.

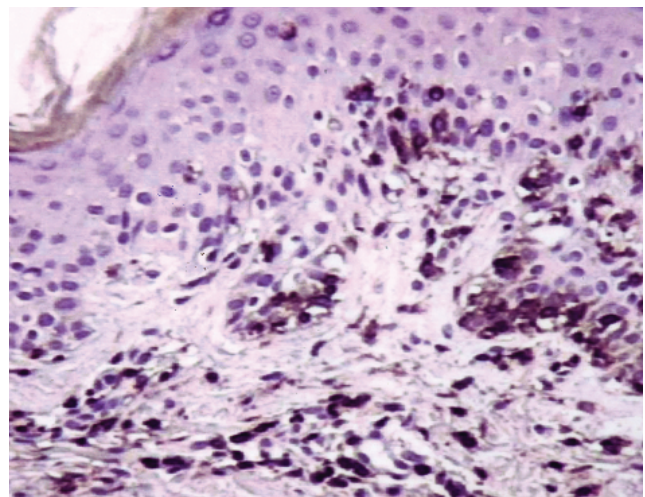


FIGURE 2: Immunohistochemistry showing epidermotropism of the CD 45 marked lymphocytes (100x).

for being the best prognosis, the immunohistochemical findings are similar to aggressive lymphomas.

In Brazil, there has only been one case of this variant reported in a Brazilian clinical medicine journal.¹⁰

It is worth emphasizing the histologic importance of the hypochromic lesions in young patients

with a high phototype (Fitzpatrick) to eliminate the diagnosis of HMF prior to attributing hypopigmentation to the most common diseases, like vitiligo, pityriasis alba, indeterminate hanseniasis, atopic dermatitis, among others. In addition, the use of immunophenotyping may complement the diagnosis, and show cell monoclonality. □

REFERENCES

1. Shabrawi-Calen LE, Cerroni L, Medeiros LJ, McCalmont TH. Hypopigmented mycosis fungoides. *Am J Surg Pathol*. 2002; 26:450-7.
2. Stone ML, Styles AR, Cockerell CJ, Pandya AG. Hypopigmented mycosis fungoides: A report of 7 cases and review of the literature. *Cutis*. 2001;67:133-8.
3. Lambroza E, Cohen SR, Phelps R, Lebowitz M, Braverman IM, DiCostanzo D. Hypopigmented variant of mycosis fungoides: Demography, histopathology, and treatment of seven cases. *J Am Acad Dermatol*. 1995;32:987-93.
4. Whitmore SE, Simmons O'Brien E, Rotter FS. Hypopigmented mycosis fungoides. *Arch Dermatol*. 1994;130:476-80.
5. Akaraphanth R, Douglass MC, Lim HW. Hypopigmented mycosis fungoides: Treatment and a 6 ½-year follow-up of 9 patients. *J Am Acad Dermatol*. 2000;42:33-9.
6. Cooper D, Jacobson M, Bart RS. Hypopigmented macules. *Arch Dermatol*. 1992;128:1268-70.
7. Ardigó M, Borroni G, Muscardin L, Kerl H, Cerroni L. Hypopigmented mycosis fungoides in Caucasian patients: A clinicopathologic study of 7 cases. *J Am Acad Dermatol*. 2003;49:264-71.
8. Whittam LR, Calonje E, Orchard G, Fraser-Andrews EA, Woolford A, Russell-Jones R. CD8-positive juvenile onset mycosis fungoides: an immunohistochemical and genotypic analysis of six cases. *Br J Dermatol*. 2000;143:1199-204.
9. Berti E, Tomasini D, Vermeer MH, Meijer CJ, Alessi E, Willemze R. Primary cutaneous CD8-positive epidermotropic cytotoxic T cell lymphomas: a distinct clinicopathological entity with an aggressive clinical behavior. *Am J Pathol*. 1999;155:483-92.
10. Silva ACLG, Rito RA, Pires MC, Valente NYS, Sittart JAS. Micose fungóide hipocrômica. *Rev Bras Clin Ter*. 1997;23:192-4.

MAILING ADDRESS: / ENDEREÇO PARA CORRESPONDÊNCIA:

Rodrigo Pereira Duquia
 Rua Engenheiro Alfredo Corrêa Daudt, 205
 90480-120 Porto Alegre RS
 E-mail: rodrigoduquia@terra.com.br