

# *Livedo reticularis* with ulcers in a patient with IgA anticardiolipin antibodies\*

## *Livedo reticularis ulcerado em paciente com anticorpo anticardiolipina tipo IgA\**

Carlos Eduardo Magro<sup>1</sup>  
Lismari Mesquita<sup>4</sup>

Fernanda Guidolin<sup>2</sup>  
Thelma Skare<sup>5</sup>

Francisco Bezerra Neto<sup>3</sup>

**Abstract:** The authors describe a case of livedo reticularis with ulcers caused by IgA anticardiolipin antibodies. The correct identification of the etiologic factor and anticoagulation led to regression of the clinical picture and healing of ulcers.

**Keywords:** Antibodies, anticardiolipin; Skin diseases, vascular; Leg ulcer

**Resumo:** Os autores descrevem um caso de livedo reticularis com ulceração em paciente portadora de anticorpo anticardiolipina do tipo IgA. A identificação do elemento causal e o estabelecimento de anticoagulação permitiu considerável melhora do quadro clínico com cicatrização das lesões.

**Palavras-chave:** Anticorpos anticardiolipina; Dermatopatias vasculares; Úlcera da perna

*Livedo reticularis* presents as a painless reddish blue reticular skin lesion that is more common in extremities.<sup>1</sup> Although its etiology is unknown in a group of patients in whom the disease is considered idiopathic, in other individuals livedo reticularis can be a manifestation of an underlying condition, such as systemic lupus erythematosus, polyarteritis nodosa, thyroid diseases, oxalosis, vascular obstructive diseases, hyperviscosity states, use of drugs (including amantadine) and antiphospholipid antibodies syndrome.<sup>1</sup>

The search for antiphospholipid antibodies is part of the diagnostic workup of these patients, including assessment of the main antibodies of this group: lupus anticoagulant, IgG anticardiolipin antibody; IgM anticardiolipin antibody.

The authors would like to share the experience of a case of livedo reticularis, in which the final diagnosis was antiphospholipid antibody syndrome, probably caused by an IgA anticardiolipin antibody.

The patient was a 22-year-old white female

who was admitted with painful leg ulcers for two months. She had been treated in her hometown as if it were brown spider bite (*Loxosceles sp*) but with no success. Two years before, she had paresthesia and paresis on the left arm, which were diagnosed as ulnar neuritis. She was treated with carbamazepine and gradually recovered her function and sensitivity. She discontinued treatment since she felt better. One year before, *livedo reticularis* appeared in both legs but was not treated. The patient smoked one pack of cigarettes a day and was on birth control pills.

On physical examination, blood pressure was 120x80 mmHg and pulse rate was 72/ minute. Chest and abdomen examination were normal. She had painful leg ulcer and livedo reticularis bilaterally (Figure 1). Other peripheral segments were normal. Laboratory investigation showed negative ANA (antinuclear antibodies), C3, C4, ENA profile, VDRL, IgG and IgM anticardiolipin antibodies and lupus anticoagulant, and serology for B and C hepatitis. Electrolyte levels, thyroid function and a mesenteric

Received on September 19, 2003.

Approved by the Consultive Council and accepted for publication on December 13, 2004.

\* Work done at Rheumatology and Pathological Anatomy Services of the Hospital Universitário Evangélico de Curitiba - HUEC - Curitiba (PR), Brazil.

<sup>1</sup> Resident of the Service of Rheumatology of the Hospital Universitário Evangélico de Curitiba - HUEC - Curitiba (PR), Brazil.

<sup>2</sup> Resident of the Service of Rheumatology of the Hospital Universitário Evangélico de Curitiba - HUEC - Curitiba (PR), Brazil.

<sup>3</sup> Residency preceptor of the Service of Rheumatology at Hospital Universitário Evangélico de Curitiba - HUEC - Curitiba (PR), Brazil.

<sup>4</sup> Assistant professor of the Discipline of Pathological Anatomy of the Medical Course, at Faculdade Evangélica do Paraná - HUEC - Curitiba (PR), Brazil.

<sup>5</sup> Adjunct professor of the Discipline of Rheumatology of the Medical Course, at Faculdade Evangélica do Paraná - HUEC - Curitiba (PR), Brazil.

©2005 by Anais Brasileiros de Dermatologia

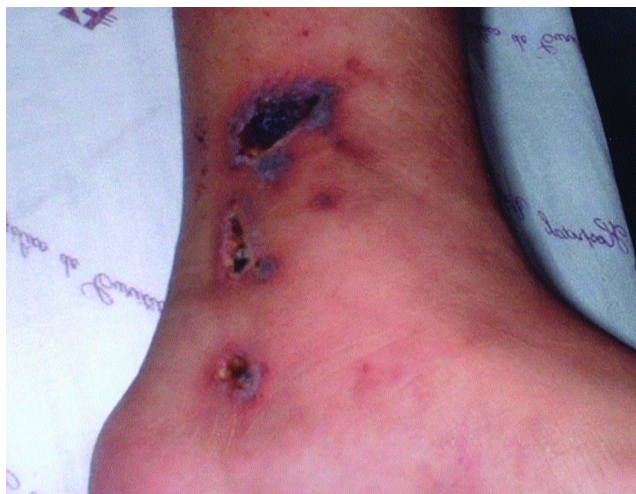

FIGURE 1: Aspect of skin ulcers before treatment

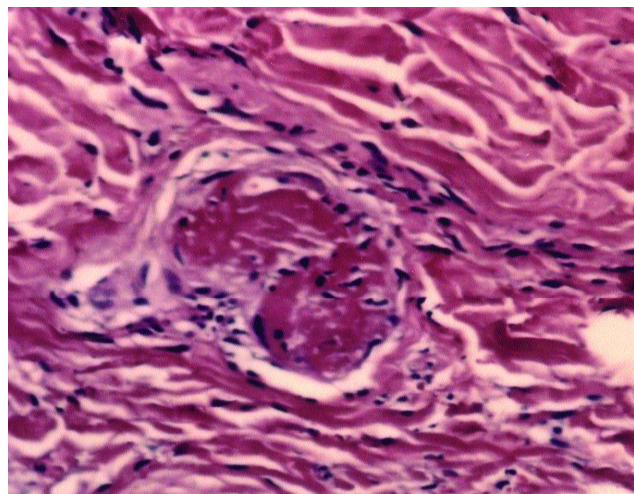


FIGURE 2: Pathological aspect a thrombus in dermal arteriole

angiography (performed to rule out polyarteritis nodosa) were normal. Skin biopsy near the leg ulcers showed capillary microthrombus in dermis with no inflammatory infiltrate (Figure 2). Based on biopsy report, a second laboratory test for antiphospholipid antibodies (IgG and IgM anticardiolipin, lupus anticoagulant) was required and the results were negative. Test for IgA anticardiolipin antibody was positive at titer of 19 APL/ml (normal value = below 10 APL/ml).

The patient was treated with oral anticoagulant (warfarin) and chloroquine. She gave up smoking and discontinued birth control pills. Her picture improved, 80% of ulcers healed in three months and the livedo was less evident. A year later the ulcers healed.

Antiphospholipid antibodies can be found isolated (in the primary form of disease) or associated with others conditions, such as systemic lupus, infections and use of medications.<sup>2</sup> They are directed against negatively charged phospholipids and are strongly associated with clinical manifestations, such as recurrent arterial/venous thrombosis, neuropsychiatric disorders, *livedo reticularis*, myocardial infarc-

tion, stroke, thrombocytopenia and recurrent miscarriages.<sup>2</sup> Cervera et al. studied one thousand patients with this syndrome and found *livedo reticularis* in about 20% of subjects.<sup>3</sup>

To clarify the etiology of *livedo reticularis* is important to prescribe treatment correctly. In the case of antiphospholipid antibodies, treatment is done with anticoagulants and platelet aggregation inhibitors.<sup>2</sup> Recently antimalarial drugs have been used due to beneficial antiplatelet action. Chloroquine and hydroxychloroquine have antiplatelet action for inhibiting arachidonic acid release from platelet membrane; they inhibit the interaction of fibrinogen with platelet receptors and inhibit platelet aggregation induced by collagen and adenosine-diphosphate.<sup>4</sup>

Testing for IgA anticardiolipin is not routinely performed and it could be easily missed, like in the case described. Because of this experience, the authors advise that the test for IgA anticardiolipin antibodies should be included in all cases of obscure *livedo reticularis*, since treatment may be more effective in case of positive antibody detection. □

## REFERENCES

1. Cuadrado MJ. Hugues antiphospholipid syndrome: Clinical features. *Rheum Dis Clin North Am.* 2001;27: 507-23.
2. Sefer G. Antiphospholipid syndrome. *Dis Mon.* 2003; 49: 691-742.
3. Cervera R, Piette JC, Font J, Khasmashta MA, Shoenfeld Y, Camps MT et al. Antiphospholipid syndrome: clinical and immunologic manifestations and patterns of disease expression in a cohort of 1.000 patients. *Arthritis Rheum.* 2002; 46:1019.
4. Van Beek M, Piette WW. Antimalarials. *Dermatol Clin.* 2001;19:147-60.

### MAILING ADDRESS:

*Thelma L. Skare*

*João Alencar Guimarães, 796*

*80310-420 - Curitiba - PR*

*E-mail: tskare@onda.com.br*