

Scleromyxedema: a case treated with oral prednisone*

*Escleromixedema: um caso tratado com prednisona oral**

Pedro Bezerra da Trindade Neto¹
Aldavânea Cabral de Oliveira e Silva³

Alexandre de Oliveira Sales²
Juliana Cristina Soares Nunes⁴

Abstract: Scleromyxedema is an idiopathic cutaneous mucinosis characterized by a papular eruption, skin induration and paraproteinemia. Histologically, fibroblast proliferation can be observed in the upper dermis associated with a mucine deposition. Treatment is difficult and at present there is no totally effective therapeutic modality to control the disease. The present report is on a 68-year-old patient with scleromyxedema without systemic manifestation, who responded to oral steroid therapy.

Keywords: Adrenal cortex hormones; Hyaluronic acid; Hypergammaglobulinemia; Mucinoses

Resumo: O escleromixedema é uma mucinose cutânea idiopática caracterizada por erupção papulosa, induração da pele e paraproteinemia. Histologicamente, se observa proliferação de fibroblastos na derme superior associada a depósito de mucina. O tratamento é difícil, não existindo na atualidade modalidade terapêutica totalmente eficaz para controlar a enfermidade. Relata-se o caso de um paciente de 68 anos com escleromixedema, sem manifestação sistêmica, que respondeu à terapia oral com corticosteroide.

Palavras-chave: Ácido hialurônico; Corticosteróides; Hipergammaglobulinemia; Mucinoses

INTRODUCTION

Scleromyxedema is a primary cutaneous mucinosis of unknown origin, characterized by infiltrating lesions in the skin, a mucine deposit in the upper dermis and monoclonal paraproteinemia.^{1,2} The myxedematous lichen spectre (papular mucinosis) was originally described by Dubreuilh and Reitman, in 1906.³

In 1953, Montgomery and Underwood⁴ classified the myxedematous lichen into four clinical forms: (1) generalized lichenous papular eruption; (2) non-confluent papular form; (3) localized or generalized lichenous plaques; and (4) urticaria-like plaques and nodular lichenous eruptions.

In 1954, Gottron and Arndt introduced the term *scleromyxedema* to refer to a variant of papular mucinosis which corresponds to a generalized diffuse lichenous eruption with skin sclerosis and normal thyroid function.^{1,5}

As a response to the indiscriminate use of the terms papular mucinosis, myxedematous lichen, and scleromyxedema, in 2001, Rongioletti et al.,⁶ based on anatomic-clinical criteria, adopted a new classification for this group of diseases: (1) generalized myxedematous lichen (scleromyxedema); (2) localized myxedematous lichen; (3) atypical forms of myxedematous lichen.

Even though there have been reports of diverse therapeutic regimens, the benefits for this condition are variable.⁷

The objective of this paper is to describe a case of this rare entity, stressing the favorable clinical response to the systemic use of a corticosteroid.

CASE REPORT

68-year-old male, anos, do sexo masculino, married, agricultural worker, born in and coming from

Received on August 01, 2004.

Approved by the Consultative Council and accepted for publication on December 07, 2005.

* Work done at Dermatology Service of the Hospital Universitário Onofre Lopes/Universidade Federal do Rio Grande do Norte – UFRN - (RN), Brazil

Conflict of interests: None

¹ Associate Professor of Dermatology at the Universidade Federal do Rio Grande do Norte – UFRN – Rio Grande do Norte (RN), Brazil. Ph.D. in Dermatology from the Universidade Federal do Rio de Janeiro – UFRJ – Rio de Janeiro (RJ), Brazil.

² Pathologist at the Hospital Universitário Onofre Lopes Universidade Federal do Rio Grande do Norte – UFRN – Rio Grande do Norte (RN), Brazil.

³ Resident Physician at Dermatology Service of the Hospital Universitário Onofre Lopes - Universidade Federal do Rio Grande do Norte – UFRN – Rio Grande do Norte (RN), Brazil.

⁴ Resident Physician at Dermatology Service of the Hospital Universitário Onofre Lopes - Universidade Federal do Rio Grande do Norte – UFRN – Rio Grande do Norte (RN), Brazil.

Espirito Santo, state of Rio Grande do Norte. For one year the patient has presented confluent erythema accompanied by slight pruritus, initially on the face and upper portion of the thorax, extending to the rest of the body, with the further appearance of progressive skin hardening. The dermatological exam revealed diffuse skin infiltration associated to multiple papules, sparse or confluent, with diameters ranging from 2 to 4 mm, located symmetrically on the extending surface of the arms, retroauricular areas (Figure 1) thorax and face, with intensification in the forehead folds and glabellar area (Figure 2). A scarcity of hair was also observed in the eyebrows and axillae.

Hemogram and liver, kidney and thyroid functions were normal. Electrophoresis of serum proteins revealed hypergammaglobulinemia. Quantitatively, there was an increase of IgG immunoglobulin: 2.110mg/dl (normal: 564-1765mg/dl), but with normal values for IgE, IgM, and IgA. Serum immunoelectrophoresis by immunofixation showed monoclonal paraprotein of the IgG type with a predominance of the lambda chain.

The histopathological examination of the skin showed a separation of collagen beams by a slightly basophilous amorphous material in the high papillar and reticular dermis, with a proliferation of enlarged fusiform fibroblasts (Figure 3). By means of alcian blue and colloidal iron dyeing the mucine deposit was made evident. (Figure 4).

The diagnostic criteria proposed for scleromyxedema included the presence of skin infiltration, the deposition of mucinous material on the dermis, exclusion of clinical and lab-tested thyroid dysfunction, as well as demonstration of paraproteinemia.

The patient began treatment with prednisone, 60mg/day, having had previous prophylaxis for disseminated strongiloidiasis with cambendazol (5 mg/kg) at a single dose. The second month of follow-up showed a reduction of erythema and pruritus. After six months there was a regression of papular eruption, skin infiltration, and IgG paraprotein was reduced to 1.11 ng/dl. By the ninth month of prednisone therapy and the clinical improvement of the lesions (Figure 5), steroid reduction was begun.

DISCUSSION

Scleromyxedema is an idiopathic cutaneous mucinosis with a chronic, progressive course, characterized by general papular eruption with skin induration, frequently associated with a peculiar monoclonal paraproteinemia (83.2% of cases).⁶

The role of paraproteinemia in the pathogenesis of this disease remains unclarified. Habitually, it is a lambda chain IgG, although some patients may present kappa chain or IgA.⁵

The paraproteinemia differs from normal IgG because it is extremely basic globulin of a small size (molecular mass: 110Kda; normal: 160Kda)⁸ and because of the absence of the significant antigen portion of the Fd fragment.^{5,9} In the reported case, the lambda IgG type monoclonal paraproteinemia was observed.

The disease affects adults between 30 and 70 years of age without gender preference. The cutaneous feature is the erythema associated with papular eruption, as well as the diffuse sclerodermiform thickening. The 1-4 mm papules are normally disposed in a symmetrical manner, either isolated or confluent, and they are located preferentially on the back of

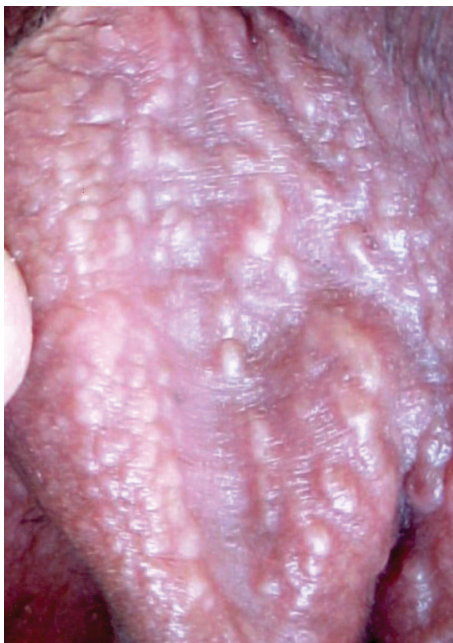

FIGURE 1: Small lichenous papules behind the ear

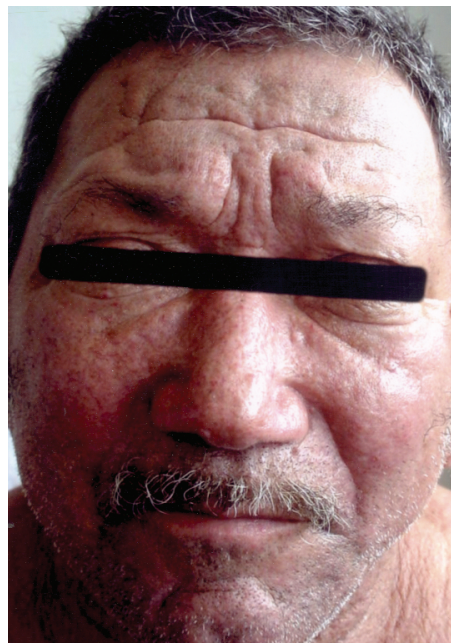

FIGURE 2: Diffuse face infiltration

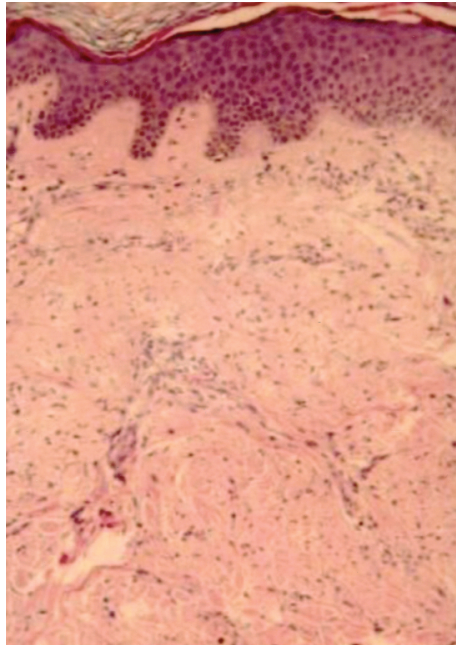


FIGURE 3: Accumulation of amorphous material separating collagen fibers and fibroblast proliferation in the high papillary and reticular dermis (HE x200)

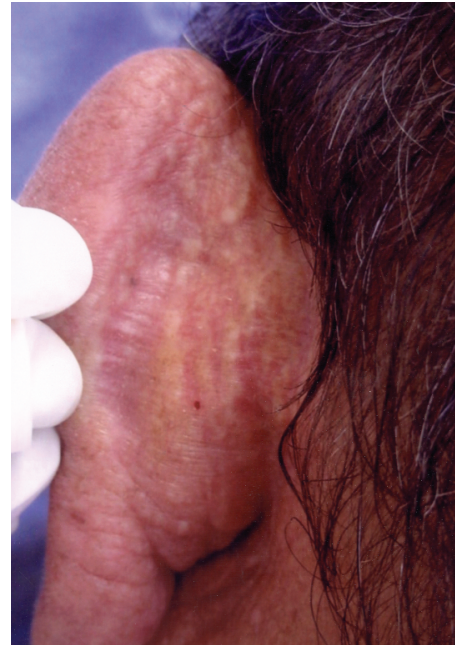


FIGURE 5: Improvement of skin lesions after nine months of treatment

hands, face, extending surface of arms, upper region of thorax and legs, and it spares the scalp and mucosae.^{8,10} The Koebner phenomenon has been described.¹¹

The eruption may be asymptomatic, even though some patients report intense pruritus. In the studied patient multiple clinical findings were encountered that were compatible with the ones described in the literature, such as the confluent erythema, initiated in the face and upper portion of the trunk and evolving towards progressive skin infiltration and papular eruption.

Papular coalescence, particularly in the face, may give rise to a lion-like appearance and the notable cutaneous infiltrate may, during movement, cause cap-

illary compression in skin folds and thus cause local pallor due to ischemia.^{9,12} When the disease reaches advanced stages, induration may prevent the patient to move lips or close eyelids. Opposite to what happens in scleroderma, this skin thickening presents mobility relative to the deep planes.¹¹

Histological finds are characteristic. Usually, there are no abnormalities in the epidermis, the pathological changes are limited to high papillary and reticular dermis. Typically, the proliferation of fusiform fibroblasts is found in an irregular arrangement on the superior dermis. There is an accentuated separation of collagen beams by a mucinous substance that is positively colored with Alcian Blue at pH 2.5.³

The mucinous material is made up of mucopolysaccharide acids with a predominance of hyaluronic acid.¹¹ Elastic fibers are usually fragmented and reduced in number. There may be a discrete perivascular inflammatory infiltrate.

The disease involves primarily the skin. However, there have been reports – not seen in the case presently under discussion – of systemic manifestations such as proximal myopathy,¹³ esophageal dysfunction,² neurological disorders,¹³ blood disorders,² and heart and kidney abnormalities. Currently, the presence of scleromyxedema in HIV affected persons,¹⁴ has been observed and 13 cases have been described in medical literature.¹⁴

Differential diagnosis of scleromyxedema must be made against amyloidosis, scleredema, clear lichen, drug-induced lichenous eruption, sclerodermy, disseminated syringoma, pillar pythiriasis, Hanseniasis, lichenous tuberculide.

Although there are reports of spontaneous remission,¹⁵ therapeutic schemes for scleromyxedema

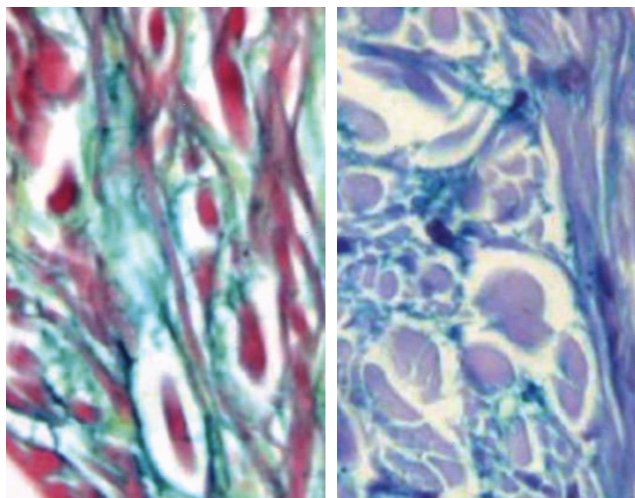


FIGURE 4: Detail of mucine deposit between collagen beams as shown by colloidal iron and alcian blue x400

have been disappointing, reflecting the lack of knowledge of the pathogenesis of such a rare condition.

Therapy with melfalan antimetabolite¹³ has shown satisfactory results, even if its use is limited due to serious side-effects of leucopenia, thrombocytopenia, and sepsis.

Cosmetically, dermal abrasion⁵ and CO₂ laser,¹⁰ have been used, but the treatment does not prevent the appearance of new lesions.

Other therapy modalities that have been reported, with inconsistent results, include conventional radiation therapy,⁵ chemotherapy agents,⁷ extracorporeal photochemotherapy,⁵ isotretinoin, talidomide, plasmapheresis,¹³ Puva,⁵ cloroquin³ and IV immunoglobulin.

The use of a corticosteroid with the purpose of reducing skin infiltration by means of the inhibition both of mucopolysaccharides and collagen formation and fibroblastic proliferation has been reported with excellent clinical response but without long-term effective results.^{3,5,12} Because strogiloidiasis is an intestinal parasitosis frequently found in tropical and

subtropical regions and its dissemination is related to the use of high doses of steroids for long periods¹⁶ prophylactic treatment is recommended, independently from the results of feces tests.

The patient reported here presented favorable clinical response with the oral use of prednisone. Until this moment, after a 10-month follow-up period, no systemic manifestation or complications have been observed. However, clinical follow-up of the patient is planned with a view to early detection of any abnormality. □

ACKNOWLEDGEMENTS

The authors thank Angelica Vanessa Moreira Neves Fonseca and Liliane Martins Negreiros de Miranda, Dermatology specialists, Federal University of Rio Grande do Norte, for their help and suggestions in the preparation of this paper.

REFERENCES

1. Bata-Csargo Z, Husz S, Foldes M, Korom I. Scleromyxedema. *J Am Acad Dermatol.* 1999; 41:343-6.
2. Dinneen AM, Dicken CH. Scleromyxedema. *J Am Acad Dermatol.* 1995; 33:37-43.
3. Vidarte OG, Rivitti E. Escleromixedema: Tratamiento con cloroquina. *Dermatol Peru.* 1997;7:71-3.
4. Montgomery H, Underwood LJ. Lichen myxedematosus: differentiation from cutaneous myxedemas or mucoid states. *J Invest Dermatol.* 1953; 20: 213-36.
5. Berkson M, Lazarus GS, Uberti-Benz M. Extracorporeal photochemotherapy: a potentially useful treatment for scleromyxedema. *J Am Acad Dermatol.* 1991; 25:724-8.
6. Rongioletti F, Rebora A. Update classification of papular mucinosis, lichen myxedematosus, and scleromixedema. *J Am Acad Dermatol.* 2001; 44:273-81.
7. Davis LS, Sanal S, Sanguenza OP. Treatment of scleromyxedema with 2-chlorodeoxyadenosine. *J Am Acad Dermatol.* 1996; 35:288-9.
8. Truhan AP, Roenigk HH. The cutaneous mucinosis. *J Am Acad Dermatol.* 1986; 14:1-18.
9. Fleishmajer R. Papular mucinosis. In: Fitzpatrick TB, Freedberg IM, Eisen AL, Wolff K, Goldsmith LA, Katz SI. *Dermatology in General Medicine.* New York: MC Graw-Hill 1999; p.2129-31.
10. Harris AO, Altman AR, Tschen JA, Wolf JE Jr. Scleromyxedema. *Int J Dermatol.* 1989; 28:661-7.
11. Pomann J, Rudner EJ. Scleromyxedema revisited. *Int J Dermatol.* 2003; 43: 31-5.
12. Rayson D, Lust JA, Duncan A. Scleromyxedema: a complete response to prednisone. *Mayo Clin Proc.* 1999; 74:481-4.
13. Nieves DS, Bondi EE, Walmark J, Raps EC. Scleromyxedema: successful treatment of cutaneous and neurologic symptoms. *Cutis.* 2000; 65:89-92.
14. Rongioletti F, Rebora A, Ghigliotti G, Marchi RD. Cutaneous Mucinosis and HIV infection. *Br J Dermatol.* 1998; 139:1077-80.
15. Kwon OS, Moon SE, Kim JA. Lichen myxedematosus with rapid spontaneous regression. *Br J Dermatol.* 1997;136:295-6.
16. Nozais JP, Thellier M, Detry M. Disseminated strongyloidiasis. *Presse Med.* 2001; 813-8.

MAILING ADDRESS:

Pedro Bezerra da Trindade Neto

*Av. Amintas Barros, 3390 - Ap. 401 - Lagoa Nova
59075-250 - Natal - RN*

Tel.: (84) 234-6530 / 222-0591

Fax: (84) 234-6530

E-mail: ptrindade@uol.com.br