

Case for diagnosis*

*Caso para diagnóstico**

Valdilene Loures de Souza¹
Rodolfo Vieira Valverde⁴

Juliana Cristina Silva Fraga²
Aloísio Gamonal⁵

Débora Gaburri³

HISTORY OF THE DISEASE

Seven-day-old white male patient, born in Juiz de Fora, MG, from normal full term delivery and uneventful gestation, with proper weight and height for gestational age, was seen at the Dermatology Outpatient Clinic presenting two erythematous-bluish nodules, with soft consistency, measuring approximately 3 cm each, located in the proximal third of the left arm and mid third of the right thigh (Figure 1). Lesions had been present

since birth, and family history was negative for similar cases.

A biopsy was performed for histopathological study (Figure 2), revealing a tumor of vascular origin, constituted by vascular lumens of various sizes, externally involved by typical glomus cells.

Treatment was expectant, and, after six months of follow-up, there was an almost complete spontaneous regression of the lesions (Figure 3).

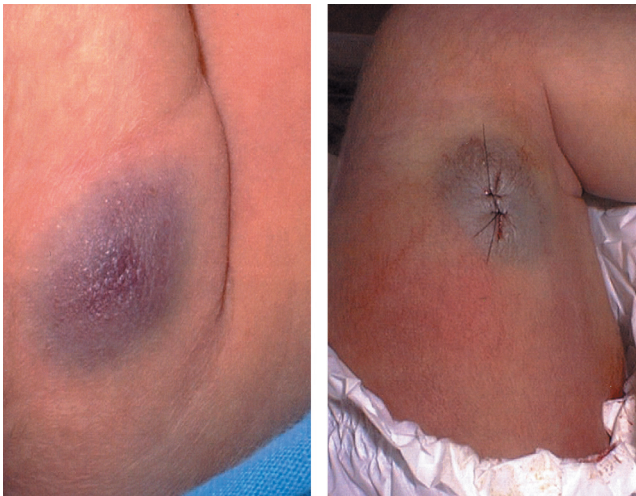


FIGURE 1: Erythematous-bluish lesion located in the proximal third of the left arm (left) and mid third of the right thigh (right)

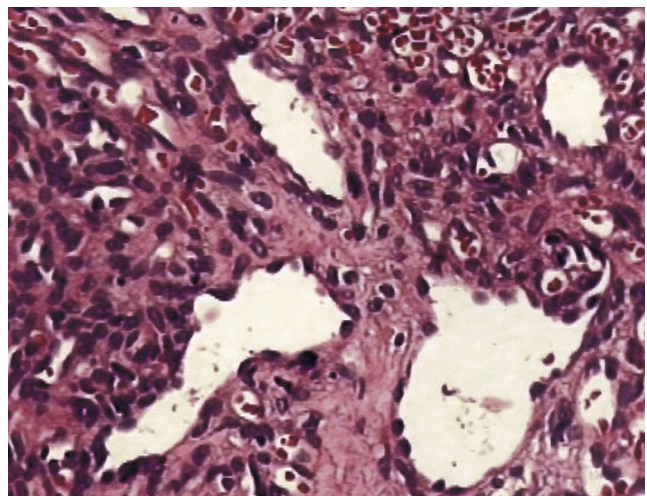


FIGURE 2: Histopathology showing vascular lumens of various sizes, externally involved by typical glomus cells

Received on November 03, 2005.

Approved by the Consultive Council and accepted for publication on June 19, 2006.

* Work done at Dermatology Department of the Universidade Federal de Juiz de Fora - UFJF - Juiz de Fora (MG), Brazil.

Conflict of interests: None

¹ Resident Doctor at the Department of Dermatology, Hospital Universitário da Universidade Federal de Juiz de Fora - UFJF - Juiz de Fora (MG), Brazil.

² Resident Doctor at the Department of Dermatology, Hospital Universitário da Universidade Federal de Juiz de Fora - UFJF - Juiz de Fora (MG), Brazil.

³ Specialist in Dermatology at the Faculdade de Ciências Médicas de Santos - Santos (SP) and SBD. Master's Degree Student in Brazilian Health at the Universidade Federal de Juiz de Fora - UFJF - Juiz de Fora (MG), Brazil.

⁴ Specialist in Dermatology at Universidade Estadual do Rio de Janeiro - UERJ - Rio de Janeiro (RJ) and SBD. Professor de Professor of Dermopathology of the Medical Residency in the Dermatology Program at Universidade Federal de Juiz de Fora - UFJF - Juiz de Fora (MG), Brazil.

⁵ PhD in Dermatology, Universidade Federal de São Paulo - UNIFESP - São Paulo (SP). Head of the Department of Dermatology at Universidade Federal de Juiz de Fora - UFJF - Juiz de Fora (MG), Brazil.

COMMENTS

Congenital glomangioma

Glomus tumor is an uncommon benign neoplasia originating from neuromyoarterial cells (glomus cells) that surround arteriovenous anastomoses located in the deep dermis, which have the function of temperature regulators.^{1,2} It more often presents as a solitary bluish nodule, even though there are multiple forms, both acquired and congenital. Histologically, three varieties are described: solid glomus tumor proper, glomangioma and glomangiomyoma, depending on the proportion of glomic cells, vascular spaces or smooth muscle cells.²

Classically, glomus tumor presents as a solitary encapsulated lesion and in only 10% of cases as multiple lesions. Solitary tumors are more frequent in young adults between the third and fourth decades of life, are bluish-red, painful and located in the extremities. Multiple presentations are usually glomangiomas and occur more commonly in men. They are generally bigger than solitary ones, are not capsulated and show a greater number of irregular vascular spaces. They may be located in any body region, either disseminated or as congenital nodules and.^{2,3}

Congenital glomangioma is present at birth, increases proportionally to child's growth in weight and stature and can be extremely painful. Some patients have positive family history for glomangioma, suggesting autosomal dominant inheritance.^{1,3} They are extremely rare, with less than 20 well documented cases in world literature.^{3,4} Malignant degeneration has not been reported, in contrast to mediasti-

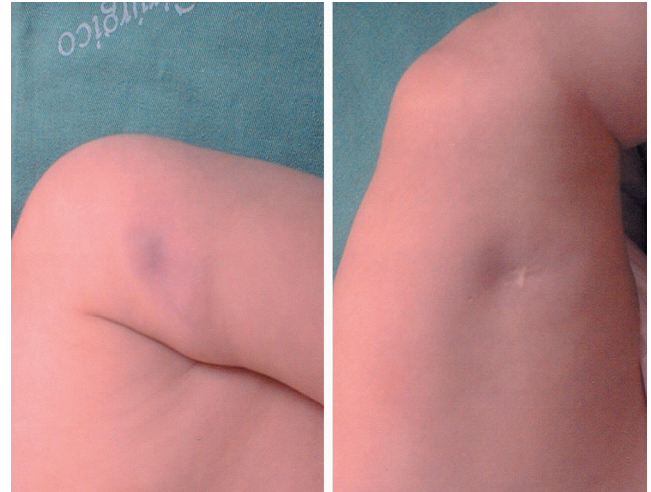


FIGURE 3: Almost complete spontaneous regression of the lesions in left arm (left) and right lower limb (right) after six months of evolution

nal glomus tumors. Around 11 patients were young with less than 20 years of age.³ No gender predominance has been observed. Lesions of the plaque type were predominant over nodules, and positive family history was reported in five cases.³ One case of congenital multiple tumor showed partial spontaneous regression.⁵

Diagnosis is confirmed by histopathological examination, and described treatment ranges widely, from expectant, as adopted in the present case, to surgical excision, laser and sclerotherapy of the lesions. □

Abstract: Glomus tumors are benign lesions that are derived from the glomus cells surrounding arteriovenous anastomoses that serve as temperature regulators. They can be classified into solitary and multiple, acquired or congenital and, histopathologically, into 3 variants: glomus tumor proper, glomangioma and glomangiomyoma. Congenital glomangiomas are extremely rare and less than 20 cases have been documented in the world literature. We report a case of congenital multiple glomangioma present from birth with spontaneous partial regression after six months of follow-up.

Keywords: Classification; Glomus tumor; Neoplasms/congenital

Resumo: Tumor glômico é neoplasia benigna originada de células glômicas que circundam anastomoses arteriovenosas e têm função de reguladores de temperatura. São classificados em solitários e múltiplos, adquiridos ou congênitos e histopatologicamente em tumor glômico sólido propriamente dito, glomangioma e glomangiomioma. Os glomangiomas congênitos são extremamente raros, com menos de 20 casos documentados na literatura mundial. Descreve-se caso de glomangioma congênito múltiplo em recém-nato, com regressão parcial espontânea após seis meses de acompanhamento.

Palavras-chave: Classificação; Neoplasias/congênito; Tumor glômico

REFERENCES

1. Blume-Peytavi U, Adler YD, Geillen CC, Ahmad W, Christiano A, Goerdts S, et al. Multiple familial cutaneous glomangioma: a pedigree of 4 generations and critical analysis of histologic and genetic differences of glomus tumors. *J Am Acad Dermatol.* 2000;42:633-9.
2. Yang JS, Ko JW, Suh KS. Congenital multiple plaque-like glomangiomyoma. *Am J Dermatopathol.* 1999;21:454-7.
3. Carvalho VO, Taniguchi K, Giraldi SJ, Bertogna LP, Marinoni JN, Fillus JS, et al. Congenital plaque-like glomus tumor in a child. *Pediatr Dermatol.* 2001;18:223-6.
4. Allombert-Blaise CJ, Batard ML, Segard M, Martin de Lassalle E, Brevière GM, Piette F, et al. Type 2 segmental manifestation of congenital multiple glomangiomas. *Dermatology.* 2003;206:321-5.
5. Kato N, Masanobu K, Ohkawara A. Localized form of multiple glomus tumors: report of the first case showing partial involution. *J Dermatol.* 1990;17:423-8.

MAILING ADDRESS:

Valdilene Loures de Souza

Travessa Regina, 85 - Centro

35300-036 - Caratinga - MG - Brazil

*Tels.: +55 (33) 3321-1867 / +55 (21) 9101-7795 /
+55 (32) 9944-5536*

E-mail: val.loures@ig.com.br

Dear colleague,

The "What is your Diagnosis?" section aims to present clinical cases in which the final diagnosis is questionable. If you have an article that fits this section, please contribute to the Anais Brasileiros de Dermatologia by sending it to us, our address is:

Av. Rio Branco, 39 / 18º andar - Centro - Rio de Janeiro - RJ - Brazil CEP: 20090-003