

Langerhans cell histiocytosis with nail involvement in childhood – a case report.*

*Histiocitose de células de Langerhans com envolvimento ungueal em criança – relato de caso**

Wellington Luiz Mendes¹
Fernando Augusto Soares⁴

Claudia Zavaloni Melotti²
Beatriz de Camargo⁵

Alanna Mara Bezerra³

Abstract: Langerhans cell histiocytosis may appear in a variety of ways. The authors present the case report of a 3-year-old white boy with a main complaint about chronic media otitis and a tumor lesion in right mastoid bone. Pathology revealed histiocytosis. The patient had severe dermatitis on the scalp and dystrophic changes with onycholysis, pustules, and nail plate deformity underneath all fingernails and toenails. These lesions responded to antineoplastic therapy. Development of nail dystrophics in Langerhans cell histiocytosis is unusual in children. This case suggests that treatment with antineoplastic therapy might be effective.

Key-words: Child; Langerhans cell histiocytosis; Langerhans cell histiocytosis/diagnosis; Langerhans cell histiocytosis/therapy; Nails; Nails/lesions

Resumo: A histiocitose de células de Langerhans pode apresentar-se de diversas formas clínicas. Neste trabalho, os autores relatam caso de menino de três anos de idade com queixa de otite média crônica e tumoração na região da mastóide direita. O exame anatomopatológico revelou histiocitose. O paciente apresentava dermatite importante no couro cabeludo e alterações distróficas com onicólise, pústulas e deformidades ungueais nos dedos das mãos e pés. As lesões responderam à terapia antineoplásica. O aparecimento de lesões distróficas ungueais na histiocitose de células de Langerhans é raro em crianças. Esse caso clínico sugere que o tratamento com terapia antineoplásica pode ser eficaz.

Palavras-chave: Criança; Histiocitose de células de Langerhans; Histiocitose de células de Langerhans/diagnóstico; Histiocitose de células de Langerhans/terapia; Unhas; Unhas /lesões

INTRODUCTION

The disease formally known as histiocytosis X is currently referred to as Langerhans Cell Histiocytosis (LCH).¹ LCH may present itself in a variety of clinical forms ranging from the spontaneous regression of the single bone lesion to a severe multi-systemic disorder. In every case, the single histological finding is the proliferation of Langerhans cells.²

LCH diagnosis is made in a presumptive manner when the typical morphological features of Langerhans cells are observed through optical microscopy, as well as when immunohistochemical assays for S100 protein are positive. The confirmation of the diagnosis is obtained if the reaction with CD1a is positive or when cytoplasm organelles

Received on July 27 of 2004

Approved by the Consultive Council and accepted for publication on Oct. 30 of 2006

* Work carried out at the Cancer Hospital Treatment and Research Center – São Paulo, Brazil.

Conflict of interests: None

¹ Physician, Department of Oncological Pediatrics, Cancer Hospital Treatment and Research Center – São Paulo, Brazil.

² Physician, Department of Dermatology / Cutaneous Oncology, Cancer Hospital Treatment and Research Center – São Paulo, Brazil.

³ 3rd. Year Resident Physician, Department of Pathology, Cancer Hospital Treatment and Research Center – São Paulo, Brazil.

⁴ Chair, Department of Pathology, Cancer Hospital Treatment and Research Center – São Paulo, Brazil.

⁵ Chair, Department of Oncological Pediatrics, Cancer Hospital Treatment and Research Center – São Paulo, Brazil.

(Birbeck granules) are seen in electronic microscopy.¹

Although LCH is a specific disease, its clinical findings vary from single bone lesions to multiple skeletal lesions, which are frequently associated with a variety of manifestations in visceral sites, such as the skin, lymphnodes, bone marrow, liver, spleen and central nervous system.

Nail alterations in LCH are unusual and they are characterized by longitudinal grooves, purpureal striations, hyperkeratosis, dense deformities under nails, nail plate loss, and paronychia. Some reports suggest that nail involvement indicates an unfavorable prognosis for the disease.³

The purpose of this case report is to emphasize the nail manifestations in LCH in a three-year-old boy diagnosed with LCH. The therapy addressed to histiocytosis treatment resulted in an improvement of nail lesions, as well as other cutaneous changes and involvement of systemic sites.

CASE REPORT

Three-year-old boy whose main complaint was chronic otitis media. He was submitted to mastoidectomy in another service due to a tumoral lesion in the region. The anatomopathological examination revealed histiocytosis. The patient was then referred to the Department of Pediatrics of the Cancer Hospital Treatment and Research Center.

A general physical examination was performed upon admission. Otoroscopy revealed purulent drainage of the right external auditory channel. The exam of the oral cavity showed ulcerated lesion of the mucosa close to the right upper molar, and the cutaneous tissue revealed scales and crusts on the scalp, suggesting the appearance of seborrheic dermatitis. Nail alterations were also seen, including paronychia, onycholysis, nail hyperkeratosis, pustules, and purpureal striations visible under all finger and toenails (Figure 1).

It is important to stress that all such changes were limited to the nail bed, not reaching the matrix. Lymphnodes and liver appeared to be normal, as well as the rest of the physical examination.

Blood test, hemossedimentation speed, liver and kidney functions, urine I and bone marrow aspirate were normal. Cultures for bacteria and fungi from the nail lesions were negative, as well as the potassium hydroxide (KOH) preparation. The CT scan of head and neck revealed an erosive lesion in the left mastoid bone. Chest and long bone X-rays were normal.

The mastoid bone lesions were reexamined, but the finger- and toenail lesions were not submitted to biopsy. Histopathological findings were characterized by a dense histiocytic infiltrate, made up mainly

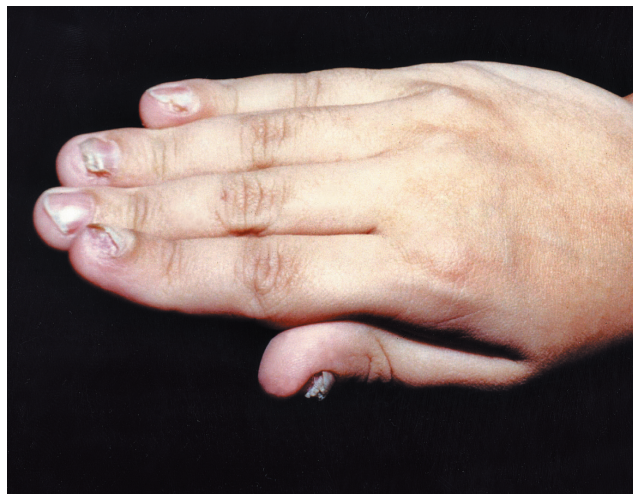

FIGURE 1: Fingernail involvement showing different degrees of onycholysis and hyperkeratosis

of Langerhans cells with a homogeneous rose cytoplasm and lobed nucleus. Some cells showed nuclear longitudinal grooves. No mitosis was identified and phagocytosis was absent. Numerous eosinophils were also present. This inflammatory infiltrate was not accompanied by necrosis. The mastoid bone involvement had an infiltrative pattern in trabecular bone.

Immunohistochemistry revealed a strong positivity for proteins S100, CD 68, and CD 1a in the histiocytic Langerhans cells (Figure 2).

Before the beginning of treatment, the patient presented symptoms of diabetes *insipidus*, with polyuria and polydipsia, which were easily controlled by means of desmopressine (1-desamino-8-D arginine vasopressine [DDAVP]) after the water deprivation test confirmed the diagnosis.

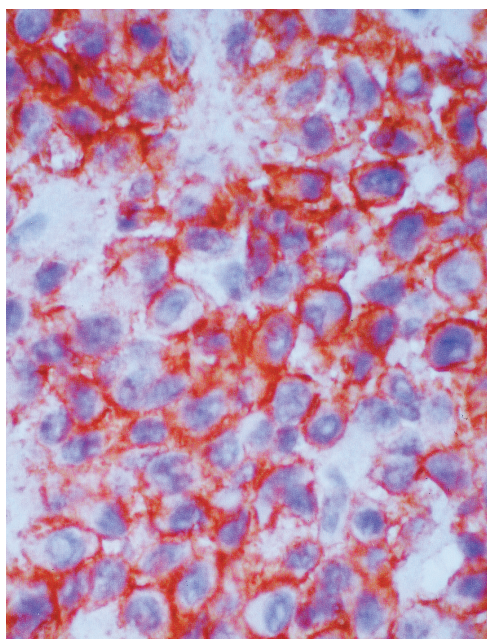


FIGURE 2: Immunohistochemistry for CD1a – 40X: positivity in Langerhans histiocytes

CHART 1: Chemotherapy scheme

INDUCTION PHASE	Oral Prednisone, 40mg/m ² day, 4-week courses Vinblastina 6mg/m ² , Intravenous bolus, days 1, 8, 15, 22, 29, 36 followed by... VVP16 150mg/m ² , intravenous infusion for 1 hour, days 1, 8, 15, 22, 29, 36
MAINTENANCE PHASE	6-mercaptopurine 50mg/m ² /dia, orally, from week 6 to 24 Prednisone 40mg/m ² , pulses orally, days 1-5 of weeks 9, 12, 15, 18, 21, 24 Vinblastine 6mg/m ² , intravenous bolus, day 1 of weeks 9, 12, 15, 18, 21, 24 VP16 150mg/m ² , intravenous in 1 hour infusion, day 1 of weeks 9, 12, 15, 18, 21, 24

The LCH diagnosis was confirmed and treatment began according to Chart 1. The first assessment was carried out after the induction phase, with a significant improvement of dystrophic alterations, disappearance of the dermatitis and improvement of the purulent otitis in the right ear, with an adequate visualization of the eardrum membrane. The maintenance phase continued for six months, with complete disease remission. The dystrophic lesions and pustules under the nails disappeared totally after six months therapy (Figure 3), as well as the dermatitis lesions. Two years after the end of systemic therapy, the patient was disease-free.

DISCUSSION

Histiocytosis includes a spectrum of diseases with many similarities. The development of nail dystrophy is unusual among children, even though its occurrence in adults has been reported by several authors.^{4,6} Bender and Holtzman were the first to publicize a case of nail involvement in LCH.⁴ After this paper, Kahn reported another case of LCH which presented nail dystrophy and good response to therapy with cytotoxic agents.⁷ Other authors reported treat-

ment success with antimetabolite agents in patients with nail involvement without the description of the pathology,⁸ even though there are some reports which do not show the same experience.⁹ All such reports associated the nail involvement with Letterer-Siwe Disease, a term no longer used for a disease that carried a poor prognosis, probably due to factors such as young age at the onset of the disease, malignant histological pattern and multisystemic involvement.¹⁰ Timpatanapong and cols. recorded nail involvement in three patients with Letterer-Siwe-type LCH and lesions similar to those of seborrheic dermatitis, suggesting an unfavorable prognosis even with the use of aggressive therapy. Other published experiences, however, did not agree with the author.^{3,5,7,11}

Holzbert and cols. reported the first LCH case in which a longitudinal biopsy of the nail showed that the dystrophy was due to the same atypical histiocytes that caused the cutaneous lesions.¹²

There is little evidence that the nail alterations constitute a prognostic factor, compared to the major organic dysfunctions which are considered useful outcome markers,¹⁰ but several authors reported a poor prognosis for patients who had the nail matrix compromised.^{3,9}

In previous reports, the clinical findings seen in the nails included longitudinal grooves, purpural striations, hyperkeratosis, pustules under the nails, dense deformities or cracks in the nail plates. The patient in question had fingernail involvement that illustrated all such changes. In accordance with other reports, the authors have been able to detect a correlation between the efficacy of chemotherapy and the disappearance of the nail lesions. The complete recovery of the nail after therapy probably occurred because the nail matrix was not affected. □

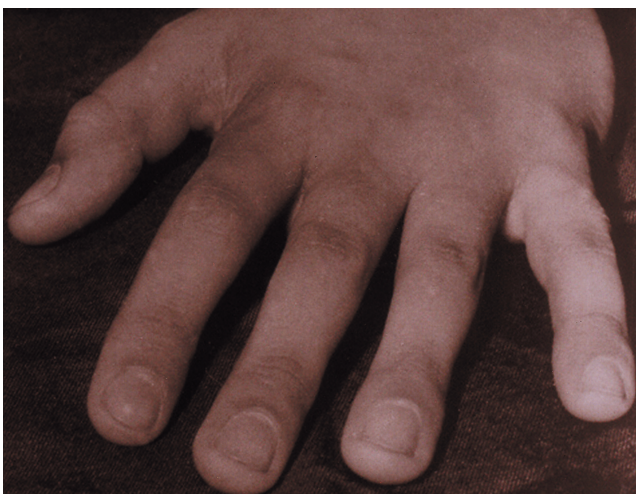

FIGURE 3: Normal nail plates after six-month treatment

REFERÊNCIAS

1. Histiocytosis syndromes in children. Writing Group of the Histiocyte Society. *Lancet*. 1987;1:208-9.
2. Chu T, Jaffe R. The normal Langerhans cell and the LCH cell. *Br J Cancer*. 1994;23(Suppl):S4-10.
3. Timpatanapong P, Hathirat P, Isarangkura P. Nail involvement in histiocytosis X. A 12-year retrospective study. *Arch Dermatol*. 1984;120:1052-6.
4. Bender B, Holtzman IN. Histiocytosis X (granulomatous reticuloendotheliosis): report of a case of chronic disseminated reticuloendotheliosis whose evolution may have some bearing on the classification. *Arch Dermatol*. 1958;78:692-702.
5. Alsina MM, Zamora E, Ferrando J, Mascaro J, Conget JI. Nail changes in histiocytosis X. *Arch Dermatol*. 1991;127:741.
6. Jain S, Sehgal VN, Bajaj P. Nail changes in Langerhans cell histiocytosis. *J Eur Acad Dermatol Venereol*. 2000;14:212-5.
7. Kahn G. Nail involvement in histiocytosis-X. *Arch Dermatol*. 1969;100:699-701.
8. Diestelmeier MR, Soden CE, Rodman OG. Histiocytosis X: a case with nail involvement. *Cutis*. 1982;30:483-6.
9. Harper JI, Staughton R. Letterer-Siwe disease with nail involvement. *Cutis*. 1983;31:493-8.
10. Lahey ME. Histiocytosis-X: na analysis of prognostic factors. *J Pediatr*. 1975;87:184-9.
11. Ellis JP. Histiocytosis X-unusual presentation with nail involvement. *J R Soc Med*. 1985;78(Suppl 11):S3-5.
12. Holzberg M, Wade TR, Buchanan ID, Spraker MK. Nail pathology in histiocytosis X. *J Am Acad Dermatol*. 1985;13:522-4.

CORRESPONDING AUTHOR:

*Wellington Luiz Mendes
Alameda Barão de Limeira, 1503.
Campos Elíseos São Paulo SP
Cep: 01202-002
Tel: 55 (11) 3828-1059
Fax: 55 (11) 3828-1059
Email: wellmendes@uol.com.br*

How to cite this paper: Mendes WL, Melotti CZ, Bezerra AM, Soares FA, de Camargo B. Histiocitose de células de Langerhans com envolvimento ungueal em criança – relato de caso. *An Bras Dermatol*. 2006;81(6):555-8.