

# Infantile acute hemorrhagic edema\*

## *Edema hemorrágico agudo da infância\**

Júlio César Gomes Silveira<sup>1</sup>  
Rodrigo Bragança<sup>3</sup>

Ada Lobato Quattrino<sup>2</sup>  
Mayra C. Rochael<sup>4</sup>

**Abstract:** Infantile acute hemorrhagic edema is a rare leukocytoclastic vasculitis that affects children under 2 years of age. The disease has a benign outcome usually with no complications or recurrence. We report the case of a 17-month-old girl with clinical and histopathological findings that are typical of infantile acute hemorrhagic edema.

**Keywords:** Child; Purpura; Purpura, Schoenlein-Henoch; Vasculitis

**Resumo:** O edema hemorrágico agudo da infância é uma vasculite leucocitoclástica rara que acomete crianças com menos de dois anos de idade. A doença tem curso benigno, geralmente sem complicações ou recidivas. Descreve-se um caso em criança de um ano e cinco meses de idade cujos achados clínicos e histopatológicos são típicos do edema agudo hemorrágico da infância.

**Palavras-chave:** Criança; Púrpura; Púrpura de Schoenlein-Henoch; Vasculite

### INTRODUCTION

Infantile acute hemorrhagic edema (IAHE) is a leukocytoclastic vasculitis first described by Snow, in 1913, and later by Finkelstein, in 1938.<sup>1,2</sup> It is a rare disease that affects predominantly children between aged 4-24 months.<sup>1</sup> Although its clinical presentation has a dramatic appearance and sudden onset, which sometimes can lead to meningococemia, sepsis and purpura fulminans, the course of the disease is benign.

### CASE REPORT

A 17-month-old female child was seen at the emergency department presenting inflammatory edema in the lower limbs and purpuric lesions on the limbs and pinna, with acute onset, less than 12 hours of evolution, and progressive worsening. One episode

of fever and diarrhea one week before the onset of the condition was reported and she was on treatment for iron deficiency anemia. The physical examination showed good general conditions and the child was afebrile. There were edematous, violet-colored, nummular lesions, in a target-like format, distributed on the lower (Figure 1) and upper limbs (Figure 2), and on the face. The remaining physical examination was unaltered. The complementary tests showed only mild leukocytosis. Routine tests for urine, serum hepatic enzyme levels, urea and creatinine were normal. The histopathological examination of the skin lesion showed leukocytoclastic vasculitis (Figure 3). Direct immunofluorescence was not performed. The management was watchful waiting and daily follow-up. After 10 days the lesions disappeared spontaneously, and

Received on February 18, 2005.

Approved by the Consultative Council and accepted for publication on June 13, 2006.

\* Work done at Hospital Universitário Antônio Pedro – Universidade Federal Fluminense - UFF - Niterói (RJ), Brazil.

Conflict of interests: None

<sup>1</sup> Post-graduate Student of Dermatology at the Universidade Federal Fluminense - UFF - Niterói (RJ), Brazil.

<sup>2</sup> Dermatologist; Adjunct Professor of Dermatology at the Universidade Federal Fluminense - UFF - Niterói (RJ), Brazil.

<sup>3</sup> Dermatologist; Post-graduate Student at the Universidade Federal Fluminense - UFF - Niterói (RJ), Brazil.

<sup>4</sup> Pathologist, Adjunct professor of Pathological Anatomy; PhD in Pathological Anatomy from the Universidade Federal Fluminense - UFF - Niterói (RJ), Brazil.

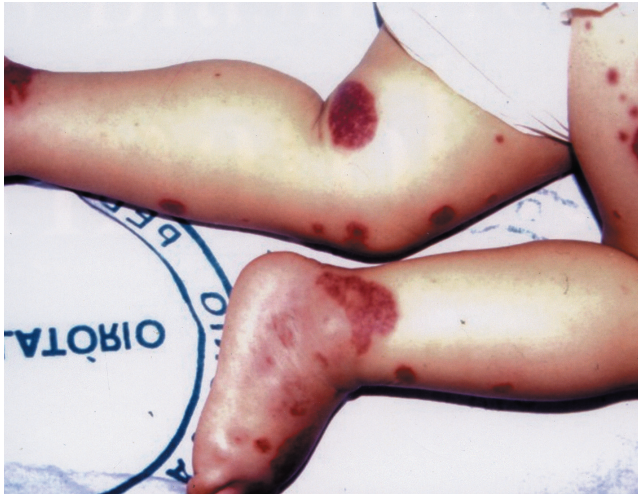


FIGURE 1: Nummular edematous and purpuric lesions on the lower limbs

there was no relapse within the one-year follow-up.

#### DISCUSSION

The IAHE was first described in 1913, by Snow, as an edematous purpura located on the limbs of an infant.<sup>1</sup> Later, it was called post-infectious cockade purpura by Seidlmayer and infantile acute hemorrhagic edema by Finkelstein.<sup>1,2</sup>

The disease affects children aged between four and 24 months,<sup>1</sup> and has also been reported in neonates.<sup>2</sup> It is believed to be a rare form of leukocytoclastic vasculitis, although it seems to be underdiagnosed or confused with an infantile form of Henoch-Schönlein purpura (HSP). In 75% of cases there is a history of recent infection, especially respiratory, or use of drugs or vaccines.<sup>1</sup> The occurrence of IAHE in patients with infections caused by cytomegalovirus and rotavirus was also described.<sup>3,4</sup>

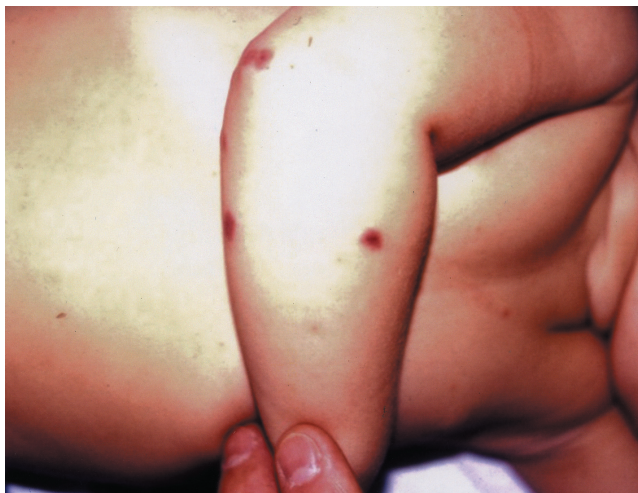

FIGURE 2: Nummular and purpuric lesions on the upper limbs

The IAHE presents as an acute condition of peripheral inflammatory edema and ecchymotic purpura on the limbs and face. The purpuric lesions are usually large, annular or target-shaped. The most important feature of the disease is the contrast between the acute progression of the skin condition and the child good general status.<sup>1</sup> Other occasional manifestations include reticular purpura, necrotic lesions mainly on the ears, and urticaria.<sup>1</sup> The occurrence of purpuric lesions on mucosae (conjunctiva and soft palate) was also described.<sup>5,6</sup> Visceral involvement is rare and the few cases where it was described presented mild and transitory renal alterations, as well as gastrointestinal impairment.<sup>1</sup>

Laboratory tests are not diagnostic. The complete blood count, erythrocyte sedimentation rate and coagulogram are usually normal.<sup>7</sup> In some cases there may be leukocytosis with eosinophilia.<sup>8</sup> The renal function and coagulation tests and stool guaiac test are normal.<sup>8</sup> The serum complement level is normal, and IgA, IgM and IgE levels may be normal or raised.<sup>5</sup> There is no record of isolated increase in IgA level.<sup>1</sup>

The histopathological examination is characterized by leukocytoclastic vasculitis, with fibrinoid necrosis of vessel walls, leukocytoclasia, erythrocyte leakage and interstitial edema.<sup>1,2,5</sup> The direct immunofluorescence findings are inconsistent, and deposits of fibrinogen and C3 in dermal vessels can exist or not.<sup>9</sup> Perivascular IgA deposits are not usually found in direct immunofluorescence, but there are reports that they may be positive in one third of the cases.<sup>10,11</sup> Therefore, the clinical characteristics, age and progression of the disease assist in making the differential diagnosis, and the absence of IgA deposits is not required for diagnosis.

The differential diagnosis of the IAHE includes

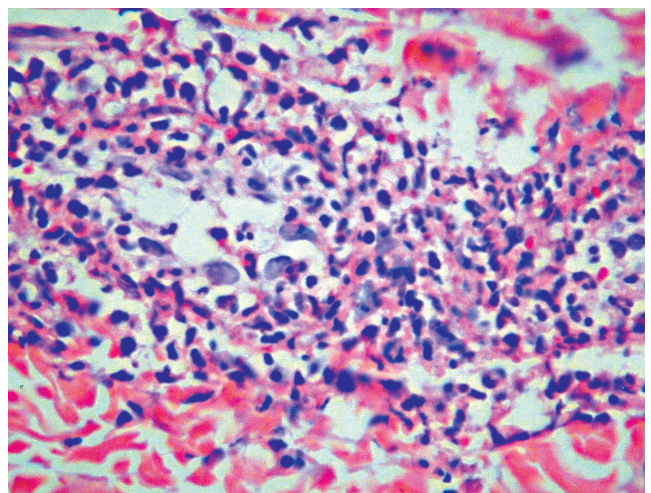


FIGURE 3: Leukocytoclastic vasculitis (HE 400X)

Sweet syndrome, polymorphous erythema, Kawasaki disease, meningococemia, septic vasculitis and traumatic purpura.<sup>5</sup>

The relation between the IAHE and Henoch-Schönlein purpura is still controversial. HSP usually affects children aged 2-8 years, and manifests as purpuric lesions that do not present the annular and target-like appearance and affect mainly legs, thighs and gluteal regions, sparing face and trunk. Additionally, there are frequent extracutaneous manifestations, such as arthralgia, abdominal pain and renal and gastrointestinal involvement. Direct immunofluorescence reveals perivascular IgA deposit.<sup>3</sup> In contrast, the IAHE usually affects children younger than two years of age, presenting annular purpuras and edema involving face, trunk and limbs. The absence of visceral involvement and the good prognosis are characteristic, and in most cases there is no perivascular IgA deposit.<sup>1,3</sup> Reports of atypical cases with characteristic findings of both

diseases have been considered overlapping of IAHE and HSP.<sup>1,10</sup>

In normal neonates, IgA levels are very low at birth and remain low during childhood, increasing progressively until adolescence.<sup>12</sup> For some authors, the absence of perivascular IgA in the IAHE could result from immaturity of the immune system in producing IgA. Thus, the IAHE would not be a distinct condition, but a HSP variant that occurs in younger children, and the differences between the two diseases would be the result of a developing immune system.<sup>10</sup>

There is no specific treatment for the IAHE.<sup>1,5</sup> The use of systemic corticoids and anti-histamines does not change the course of the disease.<sup>1,5</sup>

The complete and spontaneous resolution occurs within one to three weeks.<sup>5</sup> The disease has a benign course, and there are no relapses.<sup>5</sup> There is only one report of the IAHE that evolved to death due to a complicated ileo-ileal intussusception.<sup>8,11</sup> □

## REFERENCES

1. Legrain V, Lejean S, Taieb A, Guillard JM, Battin J, Maleville J. Infantile acute hemorrhagic edema of the skin. Study of ten cases. *J Am Acad Dermatol.* 1991;24:17-22.
2. Cunningham BB, Caro WA, Eramo LE. Neonatal acute hemorrhagic edema of childhood. *Pediatr Dermatol.* 1996;13:39-44.
3. Kuroda K, Yabunami H, Hisanaga Y. Acute hemorrhagic oedema of infancy associated with cytomegalovirus infection. *Br J Dermatol.* 2002;147:1254-7.
4. Lernia VD, Lombardi M, Lo Scocco G. Infantile acute hemorrhagic edema and rotavirus infection. *Pediatr Dermatol.* 2004;21:548-50.
5. Poyrazoglu HM, Per H, Gunduz Z, Dusunsel R, Arslan D, NarIn N, et al. Acute hemorrhagic edema of infancy. *Pediatr Int.* 2003;45:697-700.
6. Dubin BA, Bronson DM, Eng AM. Acute hemorrhagic edema of childhood: an unusual variant of leukocytoclastic vasculitis. *J Am Acad Dermatol.* 1990;23:347-50.
7. Crowe MA, Jonas PP. Acute hemorrhagic edema of infancy. *Cutis.* 1998;62:65-6.
8. Larregue M, Lorette G, Pringent F, Canuel C. Oedème aigu hémorragique du norrisson avec complication léthale digestive. *Ann Dermatol Venereol.* 1980;197:901-5.
9. Offidani, A, Cellini A, Bossi G. Acute haemorrhagic oedema of the skin in infancy. *Eur J Dermatol.* 2001;11:63-4.
10. Shah D, Goraya J, Poddar B, Parmar V. Acute infantile hemorrhagic edema and Henoch-Schönlein purpura overlap in a child. *Pediatr Dermatol.* 2002;19:92-3.
11. Baselga E, Drolet B, Esterly NB. Purpura in infants and children. *J Am Acad Dermatol.* 1997;37:673-705.
12. Wilson CB, Lewis DB, Penix LA. The physiologic immunodeficiency of immaturity. In: Steim ER, editor. *Immunologic disorders in infants and children.* Philadelphia: WB Saunders; 1996. p.253-95.

---

### MAILING ADDRESS:

*Ada Lobato Quattrino*  
*Praia de Icaraí, 371 – Apto 701*  
*24230-006 - Niterói - RJ - Brazil*