

Hidrocystoma: surgical management of cystic lesions of the eyelid

Hidrocistoma: conduta cirúrgica na lesão palpebral cística

Abelardo de Souza Couto Júnior¹

Ícaro Guilherme Donadi Ferreira Calafiori³

Wilker Benedeti Mendes⁵

Gabrielle Macieira Batista²

Vinícius Cristófori Radael⁴

Abstract: This report describes the case of a hidrocystoma of the eyelid and the surgical technique used in the therapeutical management of benign cystic lesions of the eyelids. Hidrocystomas are relatively common benign lesions of the eyelids, principally the lower eyelid. They are more common in females over thirty years of age. Diagnosis is clinical and when there is a single lesion, surgery is the treatment of choice. The surgical technique used should be described in greater detail, since it offers good esthetic results and a low risk of recurrence.

Keywords: Eyelid neoplasms; Hidrocystoma; Hidrocystoma/diagnostic; Hidrocystoma/etiology; Hidrocystoma/surgery; Sweat glands

Resumo: Relato de caso de hidrocistoma palpebral e apresentação de técnica cirúrgica na conduta terapêutica dos tumores císticos benignos da pálpebra. Os hidrocistomas são tumores benignos relativamente frequentes nas pálpebras, principalmente, na pálpebra inferior, com maior prevalência no sexo feminino e a partir da quarta década de vida. O diagnóstico é clínico e, em casos de lesão única, a conduta cirúrgica é o tratamento de escolha. Deve-se descrever melhor a técnica cirúrgica utilizada, pois traz bons resultados estéticos e menor risco de recidiva.

Palavras-chave: Glândulas sudoríparas; Hidrocistoma/cirurgia; Hidrocistoma/diagnóstico; Hidrocistoma/etiologia; Neoplasias palpebrais

INTRODUCTION

Hidrocystomas are a cystic form of sweat gland adenoma resulting from proliferation of the apocrine or eccrine secretory glands.^{1,2} They consist of single or multiple lesions of varying sizes, generally situated on the head, predominantly on the face: the forehead, cheeks and eyelids (glands of Moll), the outer canthus of the lower eyelid being the most common site.³

Their pathogenesis appears to result from an obstruction of the sweat gland ducts immediately above the glandular coil within the deep dermal layer following an inflammatory process or trauma.⁴

Hidrocystomas are benign lesions of the eyelid that are differentiated in two histological types: apocrine and eccrine.^{5,6}

The apocrine hidrocystoma or cyst of Moll

affects the eyelid border and generally appears following an obstruction of the apocrine secretory duct of the gland of Moll (apocrine and eccrine sweat glands).² They consist of small, painless, round, translucent, fluid-filled vesicles.^{1,5,7}

The eccrine hidrocystoma or cyst of the eccrine sweat glands originates from the eccrine sweat gland, also known as the gland of Moll, and is a rare disorder. It generally presents as multiple cutaneous vesicles on the lower eyelid.⁵

The most common site for cysts of Moll is close to the eyelashes, the route of lacrimal drainage, while the most common site for eccrine hidrocystomas is on the skin of the eyelid.⁸

According to the results of a study conducted at

Received on 24.04.2009.

Approved by the Advisory Board and accepted for publication on 01.07.2009.

¹ Study conducted at the Valença School of Medicine, Rio de Janeiro, Brazil.

Conflict of interest: None / *Conflito de interesse: Nenhum*

Financial funding: None / *Suporte financeiro: Nenhum*

¹ PhD, Head of the Department of Ophthalmology, Valença School of Medicine, Rio de Janeiro. Coordinator of the Medical Residency Program in Ophthalmology of the Benjamin Constant Institute, Ministry of Education, Brazil. Professor in the Postgraduate Course in Ophthalmology of the Pontifical Catholic University of Rio de Janeiro. Brazilian Society of Ophthalmology, Rio de Janeiro, Brazil.

² Undergraduate medical student, Valença School of Medicine, Rio de Janeiro, Brazil.

³ Undergraduate medical student, Valença School of Medicine, Rio de Janeiro, Brazil.

⁴ Currently enrolled in the postgraduate course in Ophthalmology at the Hospital dos Servidores of the state of Rio de Janeiro, Brazil.

⁵ Currently participating in the Residency Program in General Surgery at the Valença School of Medicine, Rio de Janeiro, Brazil.

the Botucatu School of Medicine in Brazil, hydrocystomas predominantly affect females from the fourth decade of life onwards, usually in the form of a single lesion, a finding that is in agreement with other reports in the literature.^{6,8,9} The most usual site is on the lower eyelids.¹⁰

The time between the first appearance of the lesion and reaching clinical diagnosis varies from one to five years; however, it should be emphasized that this figure is imprecise since in many cases onset of the lesion's growth was not observed by the physician, given that the lesion is usually asymptomatic.¹⁰ Consequently, the majority of patients seek treatment for esthetic reasons.⁶

The initial diagnosis is clinical, followed by histopathological confirmation.^{6,8}

Histologically, apocrine hydrocystomas present with various large cystic spaces and papillary projections in the dermis, covered by two layers of secretory cells. The innermost cells are columnar-shaped with eosinophilic cytoplasm with typical apical projections and decapitation secretion, periodic acid-Schiff (PAS)-positive and diastase-resistant granules.¹¹

Eccrine hydrocystomas are retention cysts histologically characterized by a single, partially collapsed cystic cavity in the dermis, with no papillary projections, surrounded by one or two layers of small cuboid epithelial cells. Sometimes the content of the cysts has a brownish coloring due to the lipofuscin secreted by the neighboring cell, giving it a clinical appearance of blue nevus or melanoma.¹¹

Differential diagnoses include: contagious mollusk, nodular or cystic basal cell carcinoma, hidradenoma, nevocytic nevus, blue nevus, disseminated syringoma, hordeolum, chalazion and epidermal cyst.¹²

The objective of presenting this case report is to describe the surgical management of cases of cystic tumors of the eyelid with the respective surgical technique in each case.

CASE REPORT

A 34-year-old, white female patient, SHO, a married housewife from Valença, Rio de Janeiro, Brazil, presented at the clinic complaining of a lesion on her eye. The patient reported that it had begun as a small pustulous, painless lesion in the outer canthus of the lower eyelid of her right eye ten years previously. Five years ago, she injured the lesion and from then onwards it began to grow more rapidly and became slightly painful. She then went to the ophthalmology outpatient department at the Teaching Hospital of the Valença School of Medicine in Rio de Janeiro with a complaint that the lesion was hampering vision in her right eye. She reported no other symptoms. She had a past history of systemic arterial hypertension and no

history of diabetes mellitus or of any other comorbidity. Her father died at 68 years of age of acute myocardial infarction. Her mother has systemic arterial hypertension and diabetes mellitus. The patient smokes sixteen packs of cigarettes per year and drinks alcohol socially. Ophthalmological examination revealed normal visual acuity in both eyes and no abnormalities in extrinsic ocular motility. Pupillary reflexes were preserved. Biomicroscopy revealed the presence of a translucent tumor in the outer canthus of the lower eyelid of the right eye (Figure 1). Diagnostic hypothesis was hydrocystoma. Management consisted of surgical removal and histopathological evaluation. Histology revealed an apocrine hydrocystoma. Surgical procedure/technique: Anesthesia was achieved by perilesional infiltration of 2% Xylocaine with adrenalin at a solution of 1:200,000 after which an incision was made in the skin above the cystic lesion, taking care not to penetrate too deeply with the scalpel in order not to perforate the lesion, thereby allowing it to be completely dissected and removed intact. Next, the edges of the skin were opened and the lesion was completely dissected up to its base, always by stretching (divulsion) with scissors rather than by cutting (Figure 2). Finally, the lesion was removed intact without perforating the cystic capsule. Next, the wound was cauterized, the excess skin was excised and the wound was sutured using 6.0 nylon thread and separated stitches (Figure 3).

In the surgical procedure, a single, round, translucent cystic lesion measuring approximately 1.2 cm at its greatest diameter was removed intact without rupturing the capsule (Figure 4).

Evaluation of the histological sections of the lesion revealed the structure of the cystic wall to be lined with a cubic epithelium or with predominantly simple pavement epithelium. There were congested

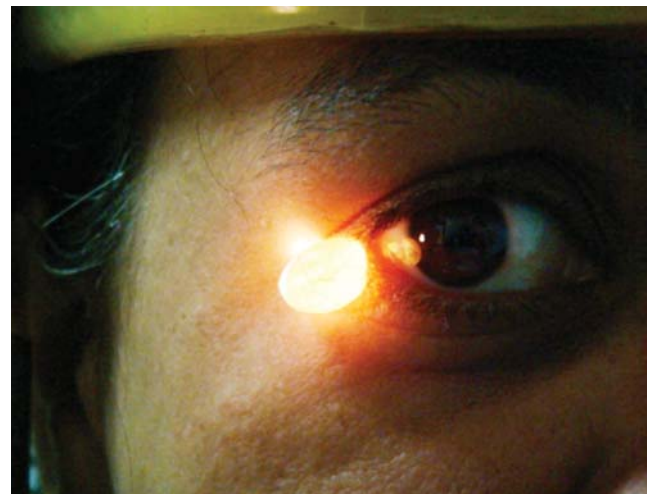


FIGURE 1: Translucent cystic lesion of the eyelid

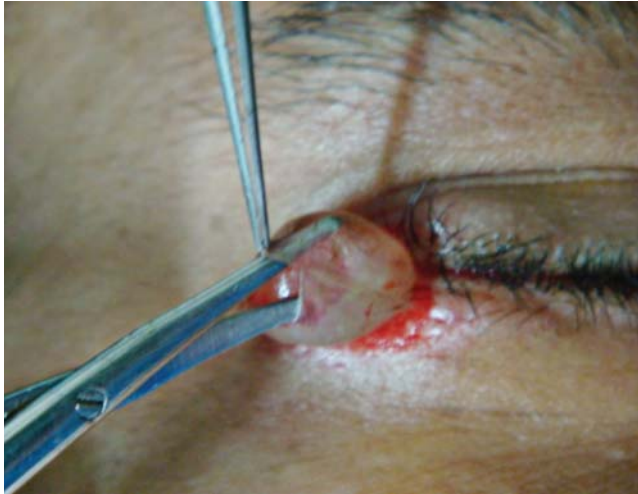

FIGURE 2: Technique of excision of the eyelid cyst by division

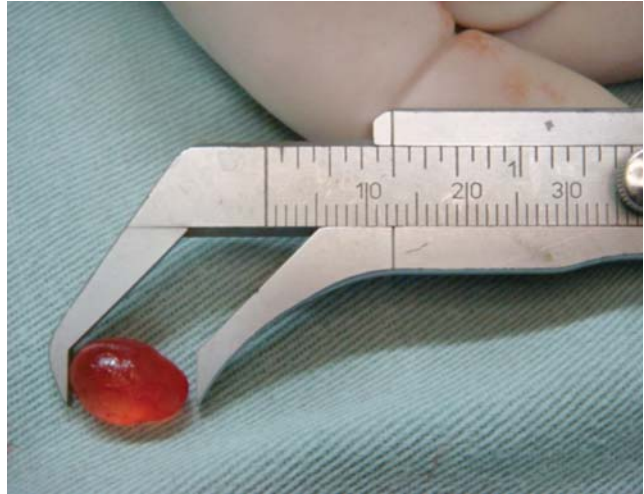


FIGURE 4: Eyelid cyst with capsule preserved

vessels in the wall and an occasional slight infiltrate of mononuclear cells. No signs of malignancy were found. Histopathology was suggestive of a diagnosis of apocrine hydrocystoma (Figure 5).

The patient in this case report was evaluated seven days after excision of the lesion at which time the wound was found to have healed completely and the stitches were then removed. The patient was followed up for eight months and there were no signs of recurrence.

DISCUSSION

Hydrocystomas of the eyelid are relatively common lesions and are easily treated. The current case describes a female patient with a single, translucent cystic lesion in the outer canthus of the lower eyelid of her right eye. Clinical features, progression and diagnosis are in agreement with other cases reported in the literature.^{6,8,9}

Surgical excision is the treatment of choice in the case of single lesions.¹³ To the best of our knowl-

edge, the surgical technique for removal of these lesions has not been described in any reports published in the literature.

Clinical and anatomopathological diagnoses were in agreement.

The macroscopic description at surgery and the anatomopathological findings are compatible with the definitions of hydrocystoma published in the literature.^{3,5,12}

In this study, the surgical technique was chosen with the objective of removing the entire lesion intact, without rupturing the wall of the cyst. To do so, surgical incision was made into the skin above the cyst, taking care not to penetrate too deeply so as not to perforate the lesion, while allowing it to be completely dissected. If the cystic lesion is perforated, it is important to remove the entire capsule, which most likely means removing the layers of secretory cells previously described in the histopathological evaluation. This technique will probably avoid recurrence of the cyst. □

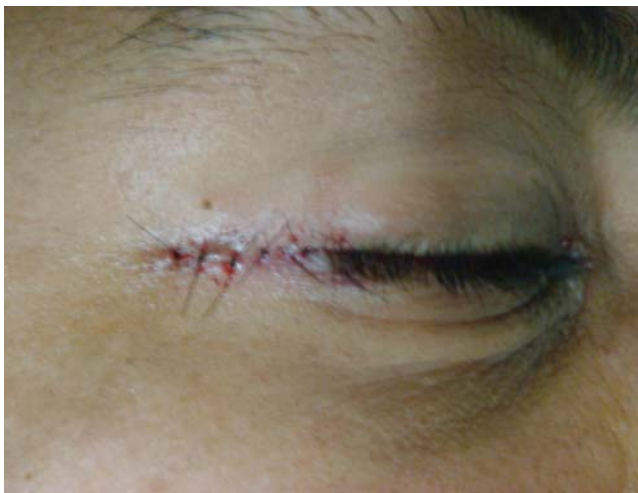

FIGURE 3: FINAL APPEARANCE FOLLOWING REMOVAL OF THE SINGLE CYSTIC EYELID LESION

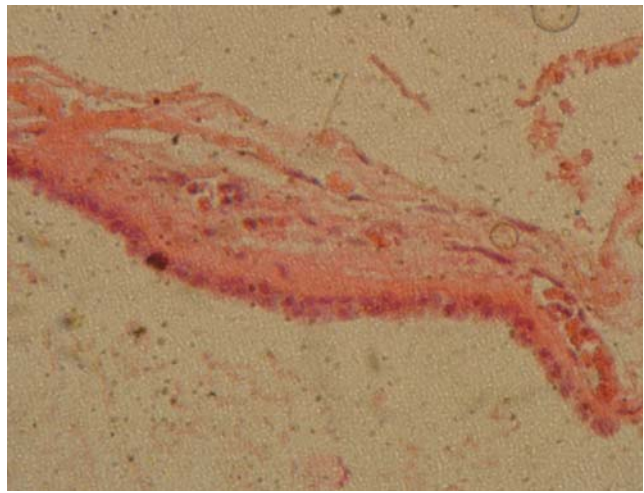


FIGURE 5: Apocrine hydrocystoma: cyst wall covered by apocrine-type epithelial cells (HE; magnification 100x)

REFERENCES

1. Rook S. Textbook of Dermatology. 4th ed. London: Blackwell ; 1986. p. 2410.
2. Abbas AK, Kumar V, Fausto N. Robbins e Cotran, Patologia - Bases patológicas das doenças. 7 ed. Rio de Janeiro: Elsevier; 2005. p. 1490.
3. Dot C, Dordain ML, Boucher E, Metge F, Millet P, Maille M, et al. Hidrocistomas eccrines multiples des paupières dans le cadre du syndrome de Schöpf. J Fr Ophtalmol. 2000;23:809.
4. Burnier JR, Belfort JR, Rigueiro MP, Montezzo LC, Chiferi JR. Tumores da pálpebra: neoplasias benignas e lesões pseudoneoplásicas. Arch Chil Oftalmol. 1985;42:129-43.
5. Kanski JJ. Clinical ophthalmology - a systematic approach. 3rd ed. Oxford: Butterworth-Hanemann International; 1997. p. 1-26.
6. Schellini SA, Pinto APC, Marques MEA, Castilho CN, Achilles AB, Padovani CR. Hidrocistoma écrino e apócrino na pálpebra - Casuística na Faculdade de Medicina de Botucatu - São Paulo. An Bras Dermatol. 2001;76:283-288.
7. Spencer WH. Ophthalmic pathology - an atlas and textbook. 3rd ed. Philadelphia: W.B. Saunders, 1986. p. 2254-2256.
8. Schellini SA, Cardilo JA, Costa JP, Paro PT, Marques MEA, Silva MRBM. Lesões benignas e pseudoneoplásicas na Faculdade de Medicina de Botucatu. Rev Bras Oftalmol. 1990;49:324-31.
9. Sacks E, Jakobiec FA, Mcmillan R, Fraufelder F, Iwamota T. Multiple bilateral apocriné cystoadenomas of the lower eyelids. Ophthalmology. 1978;94:65-71.
10. Duke-Elder S. System of ophthalmology - the ocular adnexa. London: Henry Kimpton, 1974.
11. Greer CH. Ocular pathology. 3rd ed. London: Blackwell, 1979. p. 61-78.
12. Sarabi K, Khachemoune A. Hidrocistomas-a brief review. MedGenMed 2006;8: 57.
13. Lambert WC, Wiener BD, Schawartz RA, Quillen CG, Giampapa VC. The Giant Apocrine Hidrocystoma. J Surg Oncol. 1984; 27:146-151.

MAILING ADDRESS / ENDEREÇO PARA CORRESPONDÊNCIA:
Abelardo Couto Junior
Av. Nossa Senhora de Copacabana, 1120, Gr 901
22060 000 Rio de Janeiro - RJ, Brazil
E-mail: soluc@ig.com.br /
gabriellemacieira@yahoo.com.br

How to cite this article/*Como citar este artigo*: Couto Jr AS, Batista GM, Calafiori IGDF, Radael VC, Mendes WB. Hydrocystoma: Surgical management of cystic lesions of the eyelid. An Bras Dermatol. 2010;85(3):368-71.