



Ixodiasis disclosed by epiluminescence microscopy without skin contact

Ixodíase revelada pela microscopia de epiluminescência sem contato com a pele*

Paulo Ricardo Criado ¹

Roberta Fachini Jardim Criado ²

Abstract: We describe the case of a 48-year-old healthy man who sought for medical help in our clinic with multiple pruriginous erythematous papules after a 2-day trip to “Serra da Mantiqueira”. (Mantiqueira Mountain). A meticulous physical exam with a portable epiluminescence microscopy showed several ticks on a larval form on the skin of the patient.

Keywords: Dermoscopy; Ixodes; Tick infestations; Ticks

Resumo: Nós descrevemos um homem de 48 anos que procurou nossa clínica com múltiplas pápulas eritematosas e pruriginosas dois dias após uma viagem à Serra da Mantiqueira. O exame físico meticuloso com o dermatoscópio de epiluminescência demonstrou múltiplos carrapatos na fase de larva na pele.

Palavras-chave: Carrapatos; Dermoscopia; Infestações por carrapato; Ixodes

White man, aged 48, coming from São Paulo sought our private clinic complaining of intense itching all over his body which had been lasting for two days. The eruption, a pruriginous erythematous-papulous rash had started during a trip to the region known as “Circuito das Águas” (Mantiqueira mountain).

The clinical examination of the erythematous-papulous lesions (Pictures 1A and 1B) using a DermLite DL 100 dermatoscope revealed inumerous ticks. (Pictures 1C and 1E).

The tick called *A. cajennense*, in the south east

region of Brazil, has three parasitic stages distributed throughout the year ^{2,3} The larvae, known as “micuim”, are predominant from April to July; the nymphs, called “vermelhinho”, are predominant from July to October and the adults called “rodoleiro” or “carrapato estrela” (star-tick) grow in the warm and rainy period from October to March.

When the nymphs live piled up, its parasitism is intense as from its creeping leaves they pass over to man (you have only to touch them) resulting in erythematous papules with central “inoculum” and intensely pruriginous ³. □

Received on 22.02.2010.

Approved by the Advisory Board and accepted for publication on 22.02.2010.

* The present study was carried out at “Alergoskin Alergia e Dermatologia” - São paulo (SP), Brazil.

Conflict of interest: None / *Conflito de interesse:* Nenhum

Financial funding: None / *Suporte financeiro:* Nenhum

¹ Doctorate degree (Dermatology), Faculty of Medicine, University of São Paulo (FMUSP). Doctor in the Division of Dermatology at the University Hospital of the Faculty of Medicine of the University of São Paulo (FMUSP) - São Paulo (SP), Brazil.

² Master degree of Medicine from the Institute of Medical Care to the Civil Servants of the state of São Paulo (Instituto de Assistência Médica ao Servidor Público Estadual de São Paulo) - Allergist, professor of Dermatology at the Faculty of Medicine of the ABC region, São Paulo (SP) - Brazil.

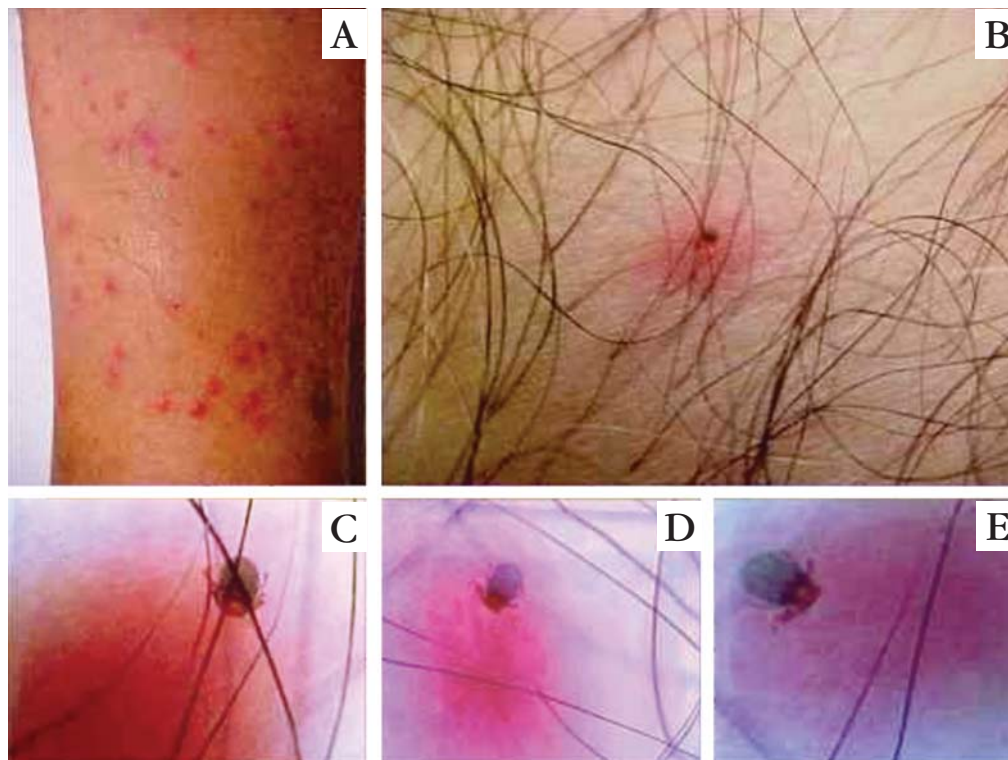


FIGURE 1: A. Multiple erythematous papules varying from 2 to 4 mm in diameter, isolated or grouped, on the leg.; B. detailed dermatological examination shows an erythematous papule topped by a dark brown point; C, D e E. dermatoscopy with epiluminescence microscopy without skin contact reveals the presence of tick in the larva stage (micuim), with its sucking apparatus immersed in the skin and paws adhered to the patient's hair.

REFERENCES

1. de Lemos ER, Machado RD, Pires FD, Machado SL, da Costa LM, Coura JR. Rickettsiae-infected ticks in an endemic area in spotted fever in the State of Minas Gerais, Brazil. Mem Inst Oswaldo Cruz. 1997;92:477-81.
2. Labruna MB, Kasai N, Ferreira F, Faccini JL, Gennari SM. Seasonal dynamics of ticks (Acari: Ixodidae) on horses in the state of São Paulo, Brazil. Vet Parasitol. 2002;105:65-77.
3. Vasconcelos W. Dermatozoíases em um imenso país tropical. An Bras Dermatol. 1979;54:87-103.

MAILING ADDRESS / ENDEREÇO PARA CORRESPONDÊNCIA:

Paulo Ricardo Criado
Hospital das Clínicas da Faculdade de Medicina da USP

Cons.: Alergoskin Alergia e Dermatologia SS Ltda.

Rua Carneiro Leão, 33 - Vila Scarpelli

09150 430 Santo André - SP

Tel.: 11 4426 8803

E-mail: prcriado@uol.com.br

How to cite this article/Como citar este artigo: Criado PR, Criado RFJ. Ixodiasis disclosed by epiluminescence microscopy without skin contact. An Bras Dermatol. 2010;85(3):388-9.