

Case for diagnosis

Caso para diagnóstico

Roberto Souto da Silva ¹
 Aline Lopes Bressan ³
 Maria de Fátima G. Scotelaro Alves ⁵

Carolina Villela da Rocha Miranda ²
 Elisa Fontenelle ⁴

HISTORY OF THE DISEASE

Female patient, aged 5, born with Down Syndrome (DS) was cared due to papulous lesions situated on the arms and thighs remaining for 3 weeks. Treatments such as curettage and zinc sulfate syrup had been previously suggested.

When examined the patient presented asymptomatic whitish papules, orbicular, hard, distributed

symmetrically on the arms and thighs. (Pictures 1 and 2). The histopathologic exam showed orbicular areas of basophilic material in the superior dermis. (Pictures 3 and 4). Dosages of calcium and serial phosphorus and the evaluation of the renal function did not present any alterations.

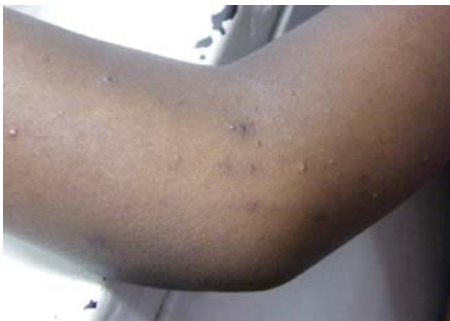

FIGURE 1: Whitish, orbicular, hard papules distributed symmetrically on the arms

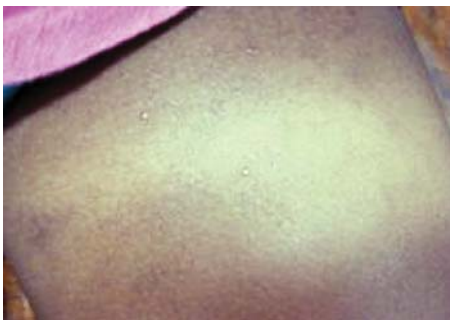

FIGURE 2: Papulous asymptomatic lesions, "milia-like", located on the thigh

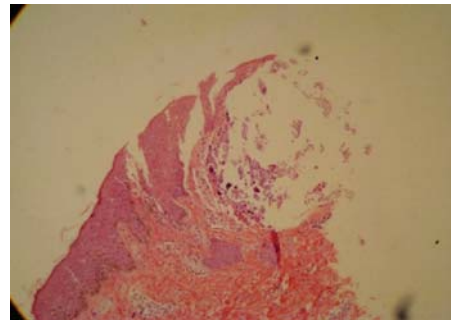


FIGURE 3: Acanthotic epidermis and dermis with basophilic nodular-like material - staining by HE (4x)

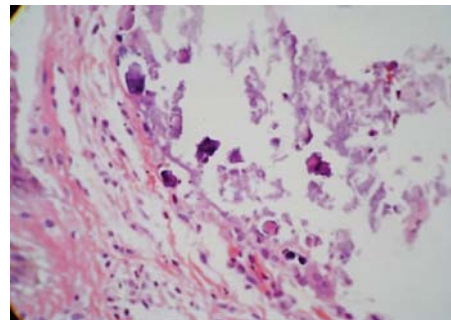


FIGURE 4: Detail of the basophilic material on the dermis - staining by HE (40x)

Approved by the Editorial Board and accepted for publication on 28.08.2009.

* Study carried out at Pedro Ernesto University Hospital - Rio de Janeiro (RJ), Brazil.

Conflict of interest: None / Conflito de interesse: Nenhum

Financial funding: None / Suporte financeiro: Nenhum

¹ Intern of Dermatology at Pedro Ernesto University Hospital - Rio de Janeiro (RJ), Brazil.

² Master student of Dermatology at Pedro Ernesto University Hospital - Rio de Janeiro (RJ), Brazil.

³ Master student of Dermatology at Pedro Ernesto University Hospital - Rio de Janeiro (RJ), Brazil.

⁴ Effective member of the SBD (Brazilian Society of Dermatology); substitute professor at Pedro Ernesto University Hospital, dermatologist at Jesus Municipal Hospital; head of the ambulatory dermatologic pediatrics of Prof. Azulay Institute of Dermatology - Santa Casa de Misericórdia do Rio de Janeiro - Rio de Janeiro (RJ), Brazil.

⁵ Doctorate degree (Dermatology); assistant professor of Dermatology and responsible for the sector of Dermopathology at Pedro Ernesto University Hospital - Rio de Janeiro (RJ), Brazil.

COMMENT

Cutaneous calcinosis is a rare dermatosis defined by the deposit of calcium chloride insoluble in the cutaneous tissue. According to its pathogenesis it can be divided into: metastatic, dystrophic, iatrogenic and idiopathic.^{1,2} The last one generally occurs in childhood or adolescence and can be classified as solitary or multiple, sporadic or associated with Down Syndrome.^{1,3}

Among the many presentations of the idiopathic form, the presence of lesions clinically similar to a milium, has strong association with the Down Syndrome.^{3,4} This rare presentation, first described in 1978, has not had more than 20 described cases in the medical literature and among them two thirds occurred in patients born with trisomy 21.⁵

Idiopathic calcinosis, different from the other forms, does not present pathogenesis or defined casual factor, it has no relation with the increase of calcium and serial phosphorus, trauma or exogenous infusion of calcium.

Clinically it presents itself as hard papules, sometimes with erythema around them or with central crust that corresponds to the transepidermic elimination of calcium. It commonly occurs on the dorsum of the hands, feet and face, but it can also be found on the wrists, elbows, knees and limbs. An important characteristic of this presentation is the spontaneous involution, in adolescence, in the majority of the cases. Syringomas can coexist with Down

Syndrome (DS). However, to some authors, this association would be fortuitous, considering the high prevalence of such alteration in patients.

In histopathology there are orbicular areas of basophilic material in the superior dermis. Through Von Kossa staining it is possible to confirm the deposit of calcium, sometimes eliminated transepidermally.

The diagnosis is based on clinical suspicion, on the histopathologic exam and on the exclusion of the alterations of calcium and serial phosphorus (including with PHT evaluation and calcitriol), previous traumas, exogenous sources of calcium or on associated diseases with calcinosis (lupus erythematosus, dermatomyositis, scleroderma, for example).^{1,7} Radiological imaging techniques such as computerized tomography and radiography can help to make the diagnosis and to evaluate the presence of visceral calcification

Differential diagnosis is made with milium, osteomas, warts, xanthomas, contagious molluscum, gout, perforans annular granuloma and epidermic cyst.⁴

As for idiopathic calcinosis, the expected conduct is the ideal one once the majority of them involute throughout adolescence and adulthood.^{1,5} The difficulty in defining the limits of the lesion in the area and the possibility that a surgical trauma generates local recurrence turns the excisional procedure a rare choice for approaching the problem. □

Abstract: Idiopathic calcinosis is a rare disease characterized by abnormal deposit of calcium salts on the dermis. It has several clinical presentations. In patients suffering from Down Syndrome, there is a rare association with idiopathic calcinosis lesions similar to milium

Keywords: Calcinosis; Down Syndrome; Syringoma

Resumo: A calcinose idiopática é uma doença rara, caracterizada pelo depósito de sais de cálcio na derme. Possui diversas apresentações clínicas. Em pacientes com Síndrome de Down, ocorre uma rara associação com lesões de calcinose idiopática semelhantes a milium.

Palavras-chaves: Calcinose; Síndrome de Down; Siringoma

REFERENCES

1. Farley JA. Calcifying and Ossifying Disorders of the Skin. In: Bologna JL, Jorizzo JL, Rapini RP. Dermatology. Madri: Mosby, Elsevier. 2008;50:653-60.
2. Touart DM, Sau P. Cutaneous deposition diseases, part II. J Am Acad Dermatol. 1998;39:527-44.
3. Kotsuji T, Imakado S, Iwasaki N, Fujisawa H, Otsuka F. Milia-like idiopathic calcinosis cutis in a patient with translocation Down syndrome. J Am Acad Dermatol. 2001;45:152-3.
4. Kim DH, Kang H, Cho SH, Park YM. Solitary milialike idiopathic calcinosis cutis unassociated with Down's syndrome: two case reports. Acta Derm Venereol. 2000;80:151-2.
5. Bécuwe C, Roth B, Villedieu MH, Chouvet B, Kanitakis J, Claudy A. Milia-like idiopathic calcinosis cutis. Pediatr Dermatol. 2004;21:483-5.
6. Schepis C, Torre V, Siragusa M, Albiero F, Cicciarello R, Gagliardi ME, et al. Eruptive syringomas with calcium deposits in a young woman with Down's Syndrome. Dermatology. 2001;203:345-7.
7. Sornas SD, Padilha MHVQ, Machado TAR, Swenson AM, Kasbergen AC. Calcinose cutânea - relato de um caso. An Bras Dermatol. 2002;77:459-63.

MAILING ADDRESS / ENDEREÇO PARA CORRESPONDÊNCIA:

Roberto Souto da Silva
Praia João Caetano 81/602, Ingá
24210 405 Rio de Janeiro RJ
Phone: 21 2618 3021
E-mail: rs_souto@yahoo.com.br

How to cite this article/Como citar este artigo: Souto RS, Miranda CVR, Bressan AL, Fontenelle E, Scotelaro MFG. Caso para diagnóstico. Idiopathic calcinosis. An Bras Dermatol. 2010;85(3):393-5.