

# Subcutaneous phaeohyphomycosis on the scrotum caused by *Exophiala jeanselmei* - Case report

Feo-hifomicose subcutânea por *Exophiala jeanselmei* localizada na bolsa escrotal - Relato de caso

André Luiz Rossetto<sup>1</sup>  
Renan André Pérsio<sup>3</sup>  
Rosana Cé Bella Cruz<sup>5</sup>

Gerson Dellatorre<sup>2</sup>  
José Ceciliano de Menezes Romeiro<sup>4</sup>

**Abstract:** Subcutaneous phaeohyphomycosis is a disease caused by dematiaceous fungi that develops mainly in immunocompromised patients. Lesions are generally located on the lower limbs. The present report describes a case of phaeohyphomycosis in an immunocompetent patient in whom a subcutaneous abscess was located in an unusual site, on the left hemiscrotum. The abscess was treated successfully with oral fluconazole associated with surgical excision.

Keywords: Dermatômicoses; *Exophiala*; Fluconazole; Mycoses; Scrotum

**Resumo:** A feo-hifomicose subcutânea é uma doença causada por fungos demáceos que acomete principalmente indivíduos imunocomprometidos e geralmente cursa com lesões localizadas nos membros inferiores. Os autores relatam um caso de feo-hifomicose subcutânea em um paciente imunocompetente, com localização atípica - na hemibolsa escrotal esquerda -, tratado com sucesso com fluconazol sistêmico associado à excisão cirúrgica.

Palavras-chave: Dermatômicoses; Escroto; *Exophiala*; Fluconazol; Micoses

## INTRODUCTION

Phaeohyphomycosis is a term used to describe opportunistic skin and systemic infections caused by various species of dematiaceous fungi, particularly those of the *Wangiella*, *Alternaria* and *Exophiala* genera.<sup>1-3</sup>

The disease is rare, cosmopolitan and generally affects rural populations in tropical regions of Central and South America, with a higher incidence in immunocompromised patients.<sup>3,4</sup>

The authors report a case of subcutaneous phaeohyphomycosis in an immunocompetent patient in whom the infection was located at an unusual site, on the left hemiscrotum. The patient was successfully treated with systemic fluconazole associated with surgical excision of the lesion.

## CASE REPORT

A 45-year old, married, male patient from Balneário Camboriú in the Brazilian state of Santa Catarina, employed as a driver, noticed erythematous, squamous, pruriginous macules in his left inguinal region extending to his left hemiscrotum. On his own initiative, the patient used several creams and the lesions disappeared. He had a habit of working in his vegetable patch at weekends, where he was in direct contact with soil. Two months later, he noticed the presence of a single, pruriginous lesion resembling an abscess, located on his left hemiscrotum, which was at times painful and which increased in volume, draining spontaneously with a purulent discharge.

The patient sought urological care, and surgical drainage of the lesion was performed. Fragments were sent for histopathology, revealing a chronic, nonspecific

Recebido em 14.07.2009.

Aprovado pelo Conselho Consultivo e aceito para publicação em 31.07.2009.

\* Trabalho realizado no ambulatório de dermatologia da Universidade do Vale do Itajaí (Univali) - Itajaí (SC), Brasil.

Conflito de interesse: Nenhum / *Conflict of interest*: None

Suporte financeiro: Nenhum / *Financial funding*: None

<sup>1</sup> Médico dermatologista pela Sociedade Brasileira de Dermatologia (SBD); professor de dermatologia - Universidade do Vale do Itajaí (Univali) - Itajaí (SC), Brasil.

<sup>2</sup> Estudante do curso de medicina da Universidade do Vale do Itajaí (Univali) - Itajaí (SC), Brasil.

<sup>3</sup> Estudante do curso de medicina da Universidade do Vale do Itajaí (Univali) - Itajaí (SC), Brasil.

<sup>4</sup> Médico urologista pela Universidade Federal do Rio Grande do Sul (UFRGS); urologista do Centro Médico Vida - Balneário Camboriú (SC), Brasil.

<sup>5</sup> Mestre Farmacêutica Bioquímica em Ciências dos Alimentos pela Universidade Federal de Santa Catarina (UFSC); Membro do Núcleo de Investigação Químico-Farmacêutica (Niqfar) da Universidade do Vale do Itajaí (Univali) - Itajaí (SC), Brasil.

ic, multifocal inflammation with granulated tissue and extensive fibrosis. He returned to the urology clinic following a recurrence of the lesion, which was then submitted to surgical removal and further histopathological evaluation, revealing results similar to those found in the previous exam. Three weeks later, there was a further recurrence of the lesion and the patient was then referred for dermatological evaluation.

Dermatological examination of the lesion revealed a single, flat, palpable, subcutaneous abscess of 4 cm in diameter, firmly affixed to the skin, with areas of atrophic scarring and the presence of a fistula with a discharge of blood and serous exudate. It was located on the patient's left hemiscrotum, and there were no palpable lymph nodes (Figures 1 and 2).

Laboratory tests (full blood count, glucose and liver and kidney function tests) were all normal. Serology (quantitative VDRL, FTA-Abs and anti-HIV 1 and 2) was nonreactive. Chest x-ray was normal. Diagnostic confirmation of phaeohyphomycosis was made by mycological examination in which micro-morphology of the culture identified the dematiaceous fungus *Exophiala jeanselmei*.

Treatment was implemented with fluconazole, 450 mg orally once a week for 12 weeks, resulting in partial regression of the lesion. Immediately prior to surgery, the dose of fluconazole was increased to 150 mg daily for one week and surgical excision of the lesion was performed by a team of urologists.

Histopathology revealed chronic superficial perivascular inflammation, the presence of areas of fibrosis and absence of tuberculoid granulomas. Special staining (PAS-Digestion) was used to investigate for fungi, which was negative.

The patient progressed well with no complications or recurrences over a 5-year follow-up period.

## DISCUSSION

Data on the incidence of phaeohyphomycosis are sparse. In a study conducted by Rees *et al.* (1998) in San Francisco, USA, the incidence of the disease was reported to be 1:1,000,000 annually.<sup>5</sup> In a review of the Brazilian literature conducted by the authors of the present paper, no publication was found up to the present date on any cases of the disease registered in the state of Santa Catarina.

The disease generally affects elderly and immunosuppressed patients such as individuals with Acquired Immunodeficiency Syndrome (AIDS) or those in prolonged use of immunosuppressive drugs, chemotherapy drugs or systemic corticosteroids.<sup>2-4, 6-9</sup> Immunosuppression, however, is not an obligatory condition for the occurrence of phaeohyphomycosis. In the case reported here, the patient was a healthy adult, who was not in use of immunosuppressive drugs, and tested negative for diabetes mellitus and HIV. These findings are in agreement with those of Murayama *et al.* (2003), who reviewed 54 cases of phaeohyphomycosis due to *E. jeanselmei* and failed to identify any underlying disease in 31 cases (57.4%).<sup>10</sup>

The *Exophiala jeanselmei* species is a etiological agent typically found in the cystic form of subcutaneous phaeohyphomycosis, the infection often resulting from direct inoculation following trauma, a cut or wound contaminated by soil, foliage, plants or decomposing wood.<sup>1,3,4</sup>

During his work in the vegetable patch, the patient had a habit of scratching his inguinal region and scrotum without first washing his hands or using protective gloves. In doing so, he may have broken the skin, thus facilitating inoculation of the fungus.

Lesions are generally confined to the upper and lower limbs, lesions on the buttocks, neck and

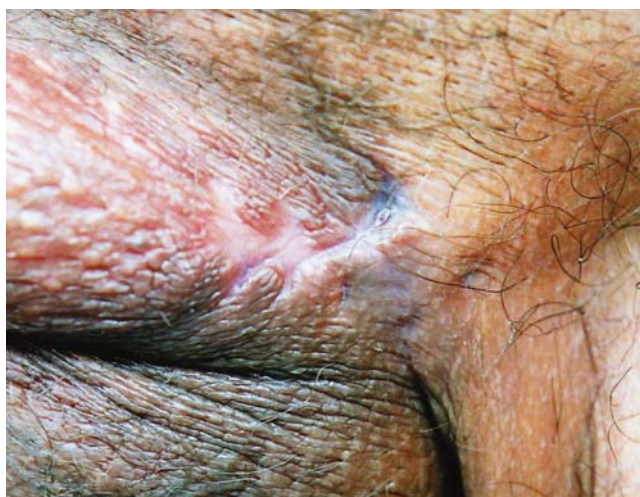

FIGURE 1: Atrophic scarring located on the left hemiscrotum

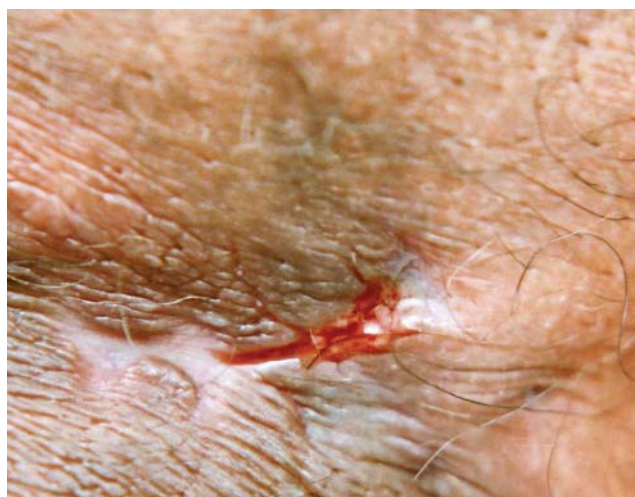

FIGURE 2: Detail of the blood and serous exudate discharge from the fistula

face being rare and on the scrotum extremely rare.<sup>4,6,11</sup> In the literature review performed by the authors of the present report, two cases were found in which the lesions were located on the scrotum, presenting as pigmented papules and recurrent hydrocele.<sup>6,11</sup>

Histopathology may aid diagnosis of the disease by identifying inflammatory alterations and dematiaceous fungal elements.<sup>2,7,12</sup> In the present case report, no structural fungal elements were found at histopathology even when special staining (PAS-Digestion) was used. According to Cunha Filho *et al.* (2005), the diagnosis of phaeohyphomycosis is based on mycological evaluation, since the clinical appearance of the condition may vary and histopathology may be nonspecific.<sup>2</sup>

The material for mycological examination was collected by swabbing the inside of the lesion through the fistula and storing the sample in 0.85% saline solution. Direct examination showed dematiaceous hyphae with a predominance of yeast elements (Figure 3). Culture was performed in 2% Sabouraud glucose agar, incubated at a temperature of 20-30°C for 30 days. Macro-morphology showed a colony with slow growth, mucoid, globular and yeast-like in appearance and black in color (Figure 4). After 10-14 days, the colony began to develop short hyphae with aerial mycelium, with a velvety texture, superficial brownish-black pigments, grayish-olive on the back. To identify micromorphology, a slide culture method was used (microculture) in potato agar, incubated at 20-30°C for 20 days. Micromorphology, performed using lactophenol cotton blue stain, identified conidia, which formed into conidiophores with a stick-like appearance, tapered at the tips to truncate apices of elliptic conidia, findings compatible with *Exophiala*

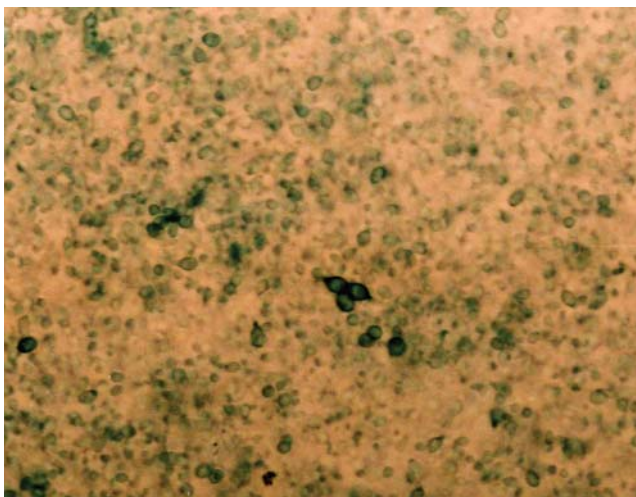


FIGURE 3: Direct mycological examination. Presence of brownish yeast elements



FIGURA 4: Cultura em meio Sabouraud 2%. Inicialmente demonstrou colônias de leveduras mucoides, globosas e de coloração preta

*jeanselmei* (Figure 5).

With respect to the treatment of subcutaneous phaeohyphomycosis, some authors have considered itraconazole to be the first choice drug.<sup>1,3,13</sup> Terbinafine alone has also been shown to be useful in the treatment of refractory subcutaneous infection, which may suggest future standardization of its use in combination with other antifungal agents.<sup>8,13</sup>

The lesions may also be treated surgically.<sup>1</sup> Some authors propose Mohs micrographic surgery as an effective therapeutic option, this constituting an alternative to the prolonged, expensive pharmacological treatments that require laboratory follow-up. An additional benefit is the minimal tissue loss with surgical removal of the lesions.<sup>12</sup>

Complete surgical resection of localized lesions results in cure with no recurrence in the major-

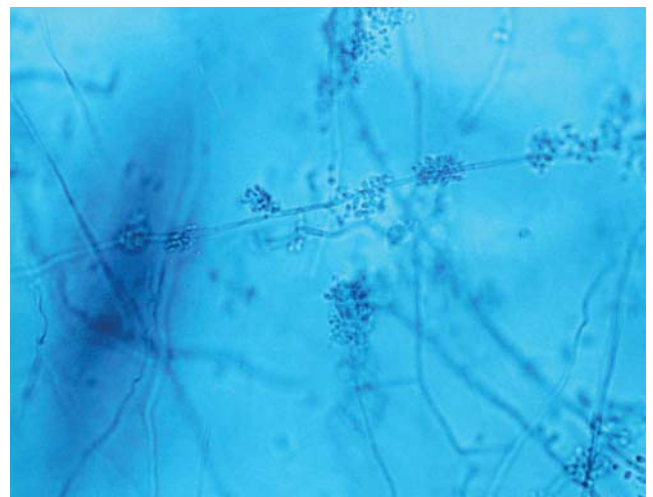


FIGURE 5: Culture in 2% Sabouraud glucose agar. Initially showed colonies of mucoid, globular, black yeast

ity of cases.<sup>1,3</sup> Terbinafine, itraconazole, amphotericin B, fluconazole and ketoconazole have also been used in association with surgical treatment.<sup>3,8,11,13,14</sup>

Although the study conducted by Silveira and Nucci (2001) showed high minimum inhibitory concentration (MIC) values for dematiaceous fungi in general with fluconazole<sup>15</sup>, in the present case report the use of fluconazole preceding surgery led to a reduction in the size of the lesion and principally in the inflammatory process, improving local conditions during surgery and facilitating surgical removal of the entire lesion.

The authors conclude that the therapeutic management used in this case resulted in successful resolution of the infection, the patient progressing favorably with no recurrence during the 5-year follow-up period.

Bearing in mind that one of the organs most frequently affected by phaeohyphomycosis is the skin, the present reports confirms that dermatology plays a crucial role in diagnosis and in providing therapeutic guidance for the other medical specialties, principally in the case of lesions located at atypical sites. □

## REFERENCES

1. Ferreira LM, Pereira RN, Diniz LM, Souza Filho JB. Caso para diagnóstico. *An Bras Dermatol.* 2006;81:291-3.
2. Cunha Filho RR, Schwartz J, Rehn M, Vettotato G, Resende MA. Feo-hifomicose causada por *Veronaea bothryosa*: relato de dois casos. *An Bras Dermatol.* 2005;80:53-56.
3. Silveira F, Nucci M. Emergence of black moulds in fungal disease: epidemiology and therapy. *Curr Opin Infect Dis.* 2001;14:679-84.
4. Martins JEC, Melo NT, Heins-Vaccari EM. Atlas de micologia médica. São Paulo: Manole; 2005. p. 85-93.
5. Rees JR, Pinner RW, Hajjeh RA, Brandt ME, Reingold AL. The epidemiological features of invasive mycotic infections in the San Francisco Bay area, 1992-1993: results of population-based laboratory active surveillance. *Clin Infect Dis.* 1998;27:1138-47.
6. Duvic M, Lowe L, Rios A, MacDonald E, Vance P. Superficial phaeohyphomycosis of the scrotum in a patient with acquired immunodeficiency syndrome. *Arch Dermatol.* 1987;123:1597-9.
7. Fonseca APM, Fonseca WSM, Silva JG, Bona SH, Araújo RC, Silva JF. Feohifomicose subcutânea: relato de três casos. *An Bras Dermatol.* 1990;65:303-7.
8. Rallis E, Frangoulis E. Successful treatment of subcutaneous phaeohyphomycosis owing to *Exophiala jeanselmei* with oral terbinafine. *Int J Dermatol.* 2006;45:1369-70.
9. Silva MRR, Fernandes OFL, Costa CR, Chaul A, Morgado LF, Fleury-Júnior LF, et al. Subcutaneous phaeohyphomycosis by *Exophiala jeanselmei* in a cardiac transplant recipient. *Rev Inst Med Trop Sao Paulo.* 2005;47:55-7.
10. Murayama N, Takimoto R, Kawai M, Hiruma M, Takamori K, Nishimura K. A case of subcutaneous phaeohyphomycotic cyst due to *Exophiala jeanselmei* complicated with systemic lupus erythematosus. *Mycoses.* 2003;46:145-8.
11. Flynn BJ, Bourbeau PP, Cera PJ, Scicchitano LM, Jordan RL, Yap WT. Phaeohyphomycosis of the Epididymis caused by *Exophiala jeanselmei*. *J Urol.* 1999;162:492-3.
12. Bogle MA, Rabkin MS, Joseph AK. Mohs Micrographic Surgery for the Eradication of Phaeohyphomycosis of the Hand. *Dermatol Surg.* 2004;30:231-3.
13. Al-Abdely HM. Management of rare fungal infections. *Curr Opin Infect Dis.* 2004;17:527-32.
14. Severo LC, Geyer G, Souza AL, Ballbinotti M. Feohifomicose subcutânea: Relato dos três primeiros casos do Rio Grande do Sul, Brasil. *An Bras Dermatol.* 1987;62:37-40.
15. Nucci M, Akiti T, Barreiros G, Silveira F, Revankar SG, Sutton DA, et al. Nosocomial fungemia due to *Exophiala jeanselmei* var. *jeanselmei* and a *Rhinocladiella* species: newly described causes of bloodstream infection. *J Clin Microbiol.* 2001;39:514-8.

---

MAILING ADDRESS / ENDEREÇO PARA CORRESPONDÊNCIA:

André Luiz Rossetto  
 Av. Alvin Bauer, 655, sala 203  
 Centro Médico Vida  
 88330-643 Balneário Camboriú, SC, Brazil.  
 Phone/fax: +55 47 3367 3407  
 E-mail: rossettovida@terra.com.br

How to cite this article/Como citar este artigo: Rossetto AL, Dellatorre G, Pérsio RA, Romero JCM, Cruz RCB. Subcutaneous phaeohyphomycosis on the scrotum caused by *Exophiala jeanselmei*: A case report. *An Bras Dermatol.* 2010;85(4):517-20.