

# High voltage electrical stimulation as an alternative treatment for chronic ulcers of the lower limbs

Estimulação elétrica de alta voltagem como alternativa para o tratamento de úlceras crônicas de membros inferiores

Eliane de Fátima Henrique da Silva<sup>1</sup>  
Elaine Caldeira de Oliveira Guirro<sup>3</sup>

Carla Campos Martins<sup>2</sup>  
Rinaldo Roberto de Jesus Guirro<sup>4</sup>

**Abstract:** High voltage electrical stimulation has been recommended as a means of accelerating the wound healing process. The effects of high voltage electrical stimulation were evaluated in the treatment of three volunteers with chronic ulcers of the lower limbs. After fifteen weeks of treatment, a reduction was found in the area of all the ulcers, suggesting that high voltage electric stimulation is an effective therapeutic option for chronic ulcers.

**Keywords:** Wound healing; Electrical stimulation; Physiotherapeutic modalities

**Resumo:** A estimulação elétrica de alta voltagem tem sido indicada para acelerar processos de cicatrização. Os efeitos da estimulação elétrica de alta voltagem, no tratamento de três voluntários com úlceras crônicas de membros inferiores, foram avaliados. Após quinze semanas de tratamento, pôde ser observada a redução da área de todas as úlceras, a qual sugere que a EEAV é um método eficaz no tratamento de úlceras crônicas. **Palavras-chave:** Cicatrização de feridas; Estimulação elétrica; Modalidades de fisioterapia

Chronic ulcers of the lower limbs are considered a public health issue, since they are persistent and often recurrent, thus generating high costs with treatment.<sup>1</sup> They are defined as wounds situated below the knee that fail to heal within six weeks.<sup>2,3</sup>

Electrical stimulation is believed to be capable of reinitiating or accelerating the healing process of wounds by transcribing the electrical current that occurs when the skin is broken.<sup>4,5</sup> High voltage electrical stimulation (HVES) has shown significant results in healing chronic ulcers based on its intrinsic mechanisms. Bearing in mind the difficulty involved in healing chronic ulcers, the objective of the present study was to describe the effects of HVES on the treatment of chronic ulcers of the lower limbs.

All the participants in this study were volunteers who were being followed up by their physicians and were instructed to continue to do so.

Three patients with chronic ulcers of the lower limbs were selected for the study. Mean age was  $54.3 \pm 4.0$  years and the mean duration of the ulcers was  $15.3 \pm 7.5$  years.

Volunteer #1 was male, 58 years of age, a salesman and a non-smoker. He had had a venous ulcer on his right medial malleolus for 15 years. He showed no signs of arterial insufficiency concomitantly to venous insufficiency (ankle-arm blood pressure index - AAI = 1.07) or any other associated diseases; however, he had reduced mobility in his talocrural joint with respect to dorsiflexion and plantar flexion movements in the affected limb. Esthesiometry detected the presence of deep, painful sensitivity around the wound.

Volunteer #2 was a 55-year old woman, a smoker, who had had an ulcer of mixed etiology for eight years located laterally on the instep of her right foot and concomitant arterial deficiency (AAI = 0.65).

Received on 28.08.2009.

Approved by the Advisory Board and accepted for publication on 31.07.09.

\* Study conducted at the Methodist University of Piracicaba (UNIMEP), Piracicaba, SP, Brazil.

Conflict of interest: None / *Conflito de interesse: Nenhum*

Financial funding: None / *Suporte financeiro: Nenhum*

<sup>1</sup> Master's degree in Physiotherapy awarded by the Methodist University of Piracicaba (UNIMEP), Piracicaba, SP, Brazil.

<sup>2</sup> Master's degree in Physiotherapy awarded by the Methodist University of Piracicaba (UNIMEP), Piracicaba, SP, Brazil.

<sup>3</sup> Professor of the Stricto Sensu Postgraduate Program of the Methodist University of Piracicaba (UNIMEP), Piracicaba, SP, Brazil.

<sup>4</sup> Professor of the Physiotherapy Course of the University of São Paulo (USP), Ribeirão Preto, SP, Brazil.

Esthesiometry indicated a loss of protective sensation with sensitivity to deep pressure and preserved pain sensation around the ulcer. Mobility of the talocrural joint was hampered in the affected limb and the patient was unable to perform plantar flexion or dorsiflexion movements.

Participant #3 was a 49-year old hypertensive female, a non-smoker. She had had an ulcer of mixed etiology located laterally on her left ankle for 23 years and concomitant arterial deficiency (AAI = 0.84). Esthesiometry showed altered sensitivity around the ulcer, with perception of sensation only at strong pressure, and reduced mobility in the talocrural joint with respect to dorsiflexion and plantar flexion movements.

Personal data were collected and a physical examination was performed. Ankle-arm blood pressure index (AAI) for detecting arterial changes was measured using a continuous-wave, hand-held Doppler device with an 8 MHz probe (Nicolet Vascular Versalab SE®).

Pain level was evaluated using a visual analogue scale (VAS), consisting of a line that ranged from “no pain” on the extreme right to “the worst possible pain” on the extreme left.

The therapeutic intervention proposed consisted of two 30-minute sessions of HVES a week for 15 weeks using a Neurodyn High Volt® (IBRAMED) with the following parameters: cathodal stimulation, minimum tension of 100 V (Figure 1A).

Standardized photography was used to record the wounds prior to treatment and after the thirty intervention sessions (Figure 1B). The area of the ulcer was measured by evaluating the photographic records, using a computer program specifically developed for this purpose.

The study was approved by the institution’s Internal Review Board under protocol #22/07.

Evaluation of the visual analogue scale (VAS) showed that volunteer #1 had no pain prior to treatment, while participants #2 and #3 had pain that diminished by 55% and 43%, respectively, after 15 weeks of treatment (Graph 1).

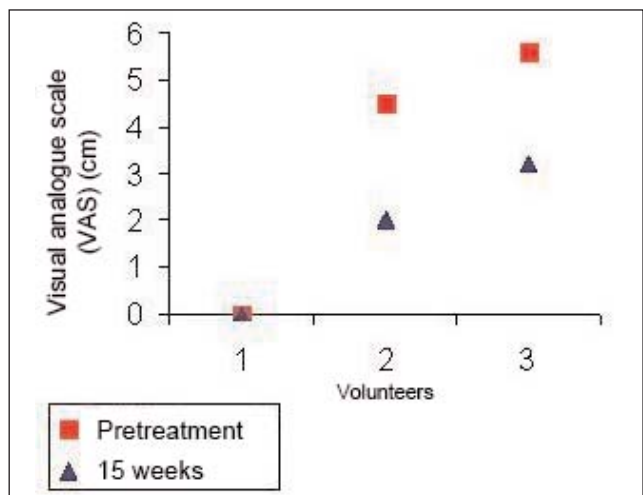
The initial area of the ulcer was 20.1 cm<sup>2</sup> in the case of patient #1, 25.26 cm<sup>2</sup> in the case of patient #2 and 10.4 cm<sup>2</sup> in the case of patient #3. After 15 weeks of treatment, these areas decreased to 16.3 cm<sup>2</sup>, 17.8 cm<sup>2</sup> and 1.6 cm<sup>2</sup>, respectively, representing a mean reduction of 36%.

The presence of a chronic ulcer affects productivity at work, limits routine and leisure activities, causes pain and loss of functional mobility and diminishes quality of life.<sup>7</sup>

A multidisciplinary team must be part of the approach used to care for patients with chronic ulcers in order to provide adequate management and coun-

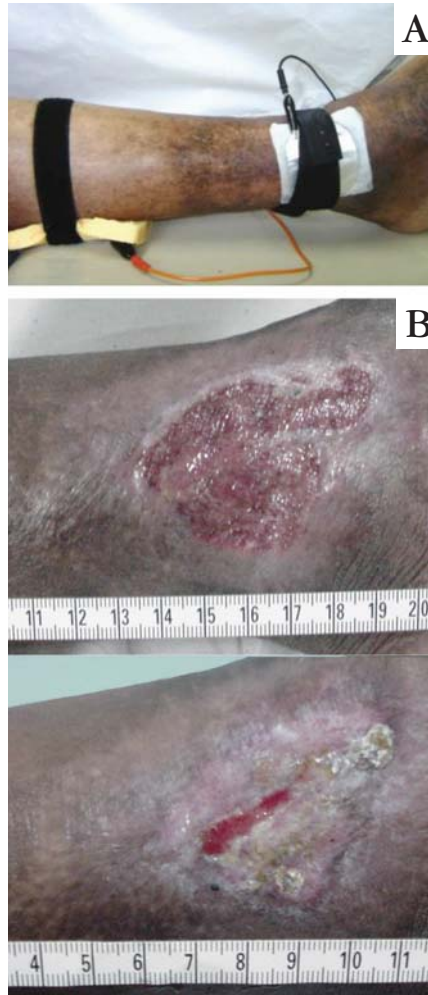

FIGURE 1: A. Photograph illustrating the procedure. B. Photograph illustrating the ulcer prior to and following treatment



GRAPH 1: Results with respect to pain evaluated using a visual analogue scale (VAS) in patients #1, 2 and 3 prior to and after 15 weeks of treatment.

seling to improve prognosis.

Some authors<sup>8-10</sup> have demonstrated the effect of HVES in healing chronic ulcers of the lower limbs of different etiologies, reporting a reduction of almost 50% in the surface area of the lesion. The present

study documents a reduction in the total area of the ulcers after fifteen weeks of treatment.

In view of these results, it is reasonable to conclude that HVES was effective in treating chronic ulcers of the lower limbs in the sample evaluated. □

#### REFERENCES

1. Frade MAC, Cursi IB, Andrade FF, Soares SC, Ribeiro WS, Santos SV, et al. Úlcera de perna: um estudo de casos em Juiz de Fora-MG (Brasil) e região. *An Bras Dermatol.* 2005;80:41-6.
2. Bergqvist D, Lindholm C, Nelzen O. Chronic leg ulcers: the impact of venous disease. *J Vasc Surg.* 1999;752-5.
3. Morrell CJ, Moffatt CJ. Cost effectiveness of community leg ulcer clinics: randomised controlled trial. *BMJ.* 1998;316:1487-91.
4. Barker AT. Measurement of direct currents in biological fluids. *Med Biol Eng Comput.* 1981;19:507-8.
5. Fitzgerald GK, Newsome D. Treatment of a large infected thoracic spine wound using high voltage pulsed monophasic current. *Phys Ther.* 1993;73:355-60.
6. Davini R, Polli M, Nunes CV, Guirro ECG, Guirro RRJ. Software for laser therapy area measurements. In: Congress of the world association for laser therapy. Guarujá. Official program annals, v. 1. p. 31; 2004.
7. França LHG, Tavares V. Insuficiência venosa crônica uma atualização. *J Vasc Bras.* 2003;2:318-28.
8. Weitz JI, Byrne J, Clagett PG, Farkouh ME, Porter JM, Sackett DL, et al. Diagnosis and treatment of chronic arterial insufficiency of the lower extremities: a clinical review. *Circulation.* 1996;94:3026-49.
9. Houghton PE, Kincaid CB, Lovell M, Campbell KE, Keast DH, Woodbury MG, et al. Effect of electrical stimulation on chronic leg ulcer size and appearance. *Phys Ther.* 2003;83:17-28.
10. Davini R, Nunes CV, Guirro ECO, Guirro RRJ. Estimulação elétrica de alta voltagem: uma opção de tratamento. *Rev Bras Fisioter.* 2005;9:249-55.

---

#### MAILING ADDRESS / ENDEREÇO PARA CORRESPONDÊNCIA:

*Elaine Caldeira de Oliveira Guirro*  
*Rodovia do Açúcar, km 156, Taquaral*  
*13400 911, Piracicaba, São Paulo, Brazil.*  
*Tel./Fax: +55 19 3124 1558*  
*e-mail: ecguirro@unimep.br*

How to cite this article/Como citar este artigo: Silva EFH, Martins CC, Guirro ECO, Guirro RRJ. High voltage electrical stimulation as an alternative treatment for chronic ulcers of the lower limbs. *An Bras Dermatol.* 2010;85(4):567-9.