

Multiple injuries of osteoma skin in the face: therapeutical least invasive in patients with acne sequela - Case report *

Lesões múltiplas de osteoma cutis na face: terapêutica minimamente invasiva em pacientes com sequela de acne - Relato de casos

Ian Goedert Leite Duarte ¹

Abstract: Osteoma cutis is a bone formation in the dermis can to be primary or secondary forms. Only, multiples, many forms, occurring on either sex, they are a rare cutaneous disease. The pathogenesis and classification remains unclear. Our objective was the diagnostic and small invasive surgery treatment of the osteoma cutis multiple of the face, in patients as a sequel of acne. To remove the osteoma we used needle BD 0,70x25 22G1, without anesthetic topic or inject able site. The small wounds were exposed with scarring balsam. We got an excellent esthetic result after 15 days.

Keywords: Cicatrix; Ossification; Osteoma, heterotopic; Skin neoplasm

Resumo: Osteoma cutis é a formação óssea no interior da pele, podendo ser primária ou secundária. Única ou múltipla, de tamanhos variados e acometendo ambos os sexos, é uma lesão cutânea rara, de etiopatogenia e classificação ainda discutidas. Nosso objetivo foi relatar o diagnóstico e a terapêutica minimamente invasiva de lesões múltiplas de osteoma cutis na face em pacientes com sequelas de acne. Fizemos a retirada dos osteomas com agulhas BD 0,70 x 25 22G1, sem anestésicos tópicos ou injetáveis no local. As pequenas incisões foram deixadas expostas, com pomada cicatrizante. Obteve-se um excelente resultado estético em 15 dias.

Palavras-chave: Cicatriz; Neoplasias cutâneas; Ossificação heterotópica; Osteoma

INTRODUCTION

The term *osteoma* refers to the anomalous presence of ossification in the interior of the dermis or epidermis. It is considered a rare and benign lesion, with limited noninvasive growth. It presents itself as unique, small, transepidermal or multiple (nodules, plaques or miliary). They are more similar, concerning histology, to the mesenchymal bones as they do not present precursor cartilage.^{1,2,3,4,5}

They can be primary, when there is no precedent cutaneous lesion. Mesenchymal cells secrete a matrix that calcifies itself into a normal bone but in a wrong place. Osteoblasts wrongly placed since the embryological period or else, other cells such as fibroblasts and fat cells start to behave as osteoblasts. It

is found in diseases such as Albright's hereditary osteodystrophy. The secondary type comes as a sequela of previous lesions such as scleroderma, traumas, scars, specific or non specific inflammatory processes, excoriations, Malherbe's calcifying epithelioma, sebaceous hyperplasias, pillar cyst, melanocytic nevus, basal cell carcinoma, AIDS, acne sequela and others.⁶ There is no distinct sexual prevalence between the primary and the secondary forms but there is a 2:1 relation woman-man in the primary form.¹

They might occur at any age.^{7,8,9} The areas most commonly affected are the face, scalp, digits and subungual regions.^{8,9} There is predominance of surgical treatments.^{5,8}

Received on 06.08.2009.

Approved by the Advisory Board and accepted for publication on 27.11.09.

* Work carried out in the Center of Research and Post Graduation in Aesthetic Medicine – Minas Gerais(MG), Brazil.

Conflict of interest: None / *Conflito de interesse: Nenhum*

Financial funding: None / *Suporte financeiro: Nenhum*

¹ Member of the Brazilian Society of Plastic Surgery. Master Degree in Surgery from the Federal University of Minas Gerais (UFMG) – Minas Gerais (MG), Brazil.

CASE REPORTS

Six adult patients were evaluated. A man and five women chosen, at random, according the sequence of appointments, within a period of two months.

It was a pre-requisite the wish to treat acne sequels, independent from their previous treatment, excluding the use of lasers, peelings and fulfilling procedures.

After the asepsis, the skin was smoothly stretched and palpated until the small nodules were felt hardened, with pigmentation similar to that of the skin (Picture 1A). Without any kind of topic or injetable anaesthetic, a small incision was made with the bezel turned to an upside position, of a BD 0,70x25 22G1 needle, until reaching a hardened resistance (Picture 1B), that when forced, it would make a projection under the skin (Picture 2A).

A small detachment was made around the whole lesion, letting it free from the adjacent plans. With a light upward pressure, the osteoma was removed trying to be the least invasive as possible. (Picture 2B).

With drop bleeding, none of the patients felt any discomfort with the removal of the lesions, that were a minimum of two and a maximum of eight in the same session (Picture 3A). It was put and kept an exposed dressing with healing ointment (Picture 3B).

The removed lesions were placed in formol and sent to anatomo-pathologic exams.

DISCUSSION

Osteoma has other different names: osteoma cutis, osteomatosis or cutaneous osteosis, miliary osteoma, disseminated congenital osteoma and cutaneous ossification. They are benign tumours, of mature bone tissue,⁴ that are located in the dermis

and hypodermis and the majority of them is clinically asymptomatic.^{4,10}

In macroscopy they appear as irregular, hardened small nodules in the sujacent dermis, well circumscribed⁷ and generally they are the same colour of the skin. Patients treated with tetracycline or minocycline can develop bluish^{8,12} pigmented nodules.^{3,10,11}

They are found in patients from both sexes, different age groups and different races.^{7,9} Occurrences within some families suggest genetic factors.⁴

Pathogenicity is still not conclusive. The most accepted theory¹³ refers to local metaplasia of mesenchymal cells such as fibroblasts producing bone tissue,⁵ by the probability of alteration in the oxigen tension, ph, enzymatic activity, high activity of alkaline phosphatase, local concentrations of calcium and phosphorus,^{2,6,14} presence of collagens type I¹⁰ and III and TGF,¹⁵ Another theory mentions an embryologic disorder with the primitive mesenchymal cells differentiated into osteoblasts wrongly migrating to other places.^{1,5}

Various authors^{2,15} affirmed that the first case of osteoma cutis was described by WILKINS in 1858. Its classification into primary and secondary ones which was given in 1941 by HOPKINS² is still controversial.⁷ The primary one (neoplastic) occur in the first years of life,⁴ without previous lesion, with phenotypic and metabolic characteristics: Albright's hereditary osteodystrophy, multiple miliary osteoma on the face, isolated osteoma, disseminated osteoma and congenital osteoma in plaque. They represent from 15 to 20% of the cases. The secondary or metaplastic one occur as consequence of previous lesions, inflammatory diseases of the dermis, dermatomyositis, morphea, progressive systemic sclerose, CREST syndrome, basal cell

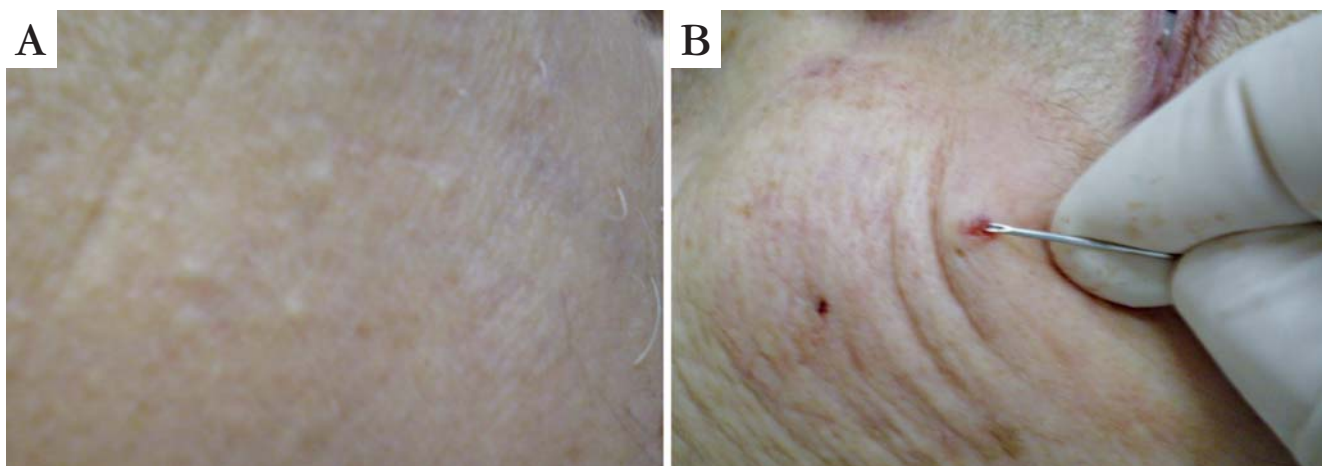


FIGURE 1: A. Smooth stretching of the skin with normal pigmentation; B. perforation of the skin to touch the lesion

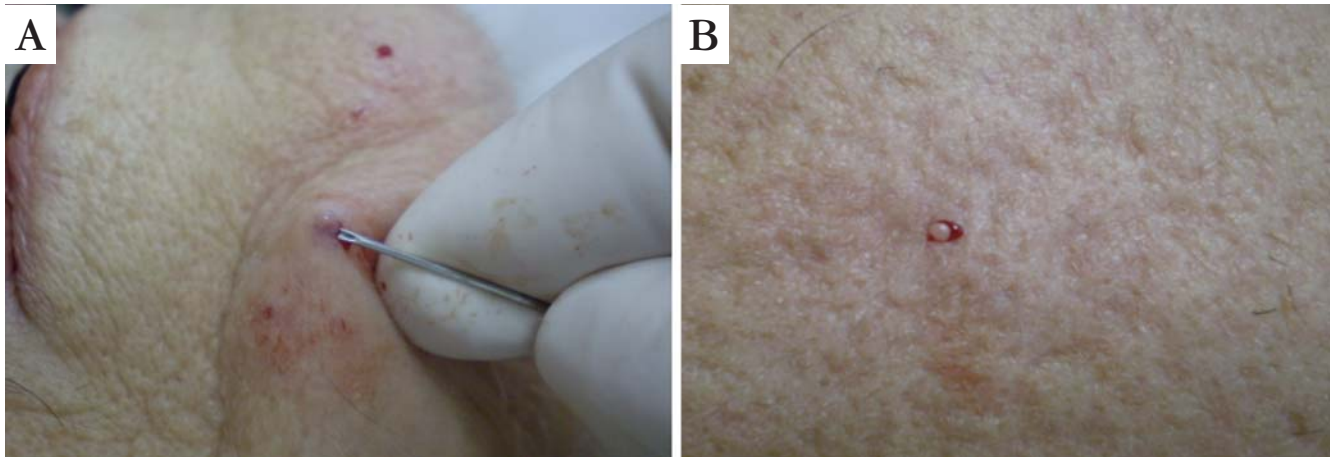


FIGURE 2: A. small incision with projection of osteoma; B. osteoma removal

carcinoma and Malherbe's calcified epithelioma, traumas, scars and application of intralesional corticoids for long periods of time in keloids. They represent from 80 to 85% of the cases^{1,3,4,6,8,9,13,14} Not all osteomas can be clearly categorized.⁸ The osteoma cutis miliary, can be classified in both groups: as it is not related to hypercalcemia or calcinosis, it could be classified as primary, but with precedent inflammatory processes it would be classified as secondary⁴

The option, in this present work that is to diagnose osteoma cutis only in patients with acne sequela was due to the fact that various authors noted a correlation between the severity of acne and the presence of osteomas.^{4,12} It was suggested the exacerbation of osteomas after the use of isotretinoin¹² in severe acne, but we questioned this statement considering that this type of acne will result in larger and greater numbers of scars. Therefore, isotretinoin would be a precipitant and not an etiological factor.

Agreeing with other authors, blood pressure,^{6,12}

radiology of face and laboratorial exams were considered normal in our patients.⁹ We believe that ultrasound and magnetic resonance could help with the diagnosis of the disease but they present a high cost.

The histopathological diagnosis is made by the deposition of calcium carbonate,⁵ by the presence of nodules with sizes varying from 2 to 5mm,^{1,3,4} clearly defined, irregular, from trabecular bone tissue where it is observed Harvers conduits with blood vessels and presence of osteoblasts, osteoclasts and osteocytes,^{3,7,8} with lamellar endings,³ central spaces with fatty bone marrow¹ eliminating any form of calcinosis (amorphous depot of sodium phosphates and calcium carbonates on the skin, as a result of endocrine and metabolic diseases) The treatment of the base disease is carried out concomitantly with the excision and suture,^{3,5,6,8} punch excision,^{5,6} excision and curettage,^{1,3} dermoabrasion,^{3,8} tretinoin 0,05% or topic acid azelaic,³ erbium: YAG laser as ablative for the epidermis,^{3,5,9,10} CO2 laser,^{1,10} TCA 100% over the lesions¹¹

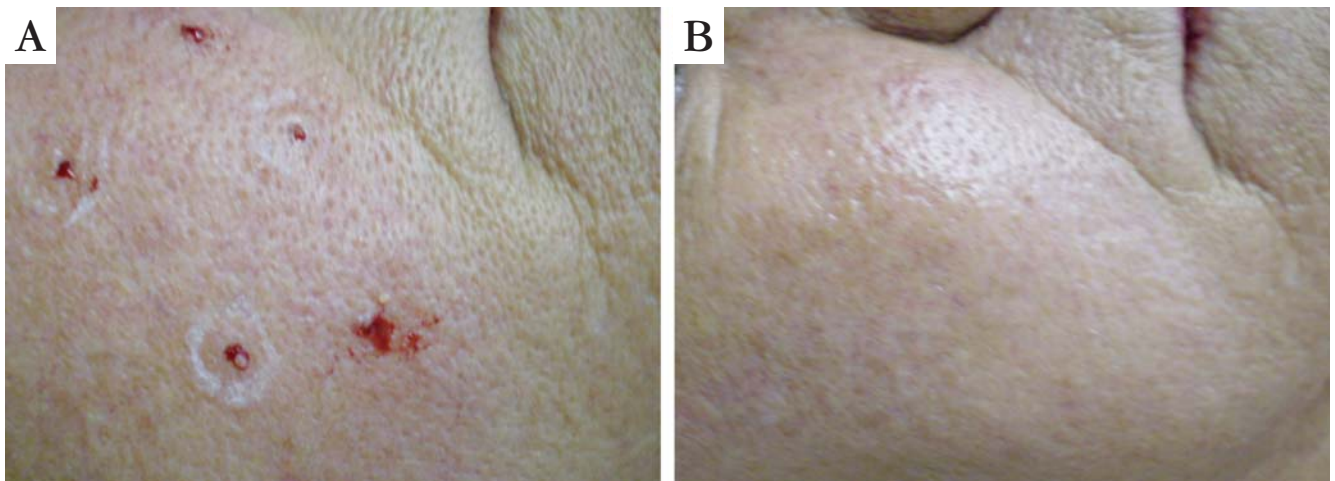


FIGURE 3: A. removal and exposition of osteomata cutis; B. skin of the face 15 days after the removal of the lesions

promoting the transepidermic elimination of the osteoma.^{3,9}

We questioned whether these lesions are rare because they are investigated when the patient presents specific complaint about the presence of nodules, never being investigated as a routine included in protocols for the treatment of the skin, mainly those skins which present predisposing factors such as acne sequelae.

The therapeutics used in our present work with BD 0,70x25 22G1 needle, absence of topic or

injetable analgesics, was not observed in any other work. It presented low cost, technical simplicity, rapid healing, proved to be efficient to minimize dermal damages, apart from not developing post-inflammatory hyperpigmentation.

The micro incisions were well tolerated by all patients and none of them presented hematoma or ecchymosis.

The final esthetics evaluation, on the 15th day of the remotion of the lesions was considered by patients and doctors excellent. □

REFERENCES

1. Vergamini GC, Parada MB, Hassun KM, Michalany N, Talarico S. Tratamento para os osteomas cutâneos da face por excisão com agulha. Apresentação de três casos. *Med Cutan Iber Lat Am*. 2007;35:229-32.
2. Habermann Neto T, Nogueira Neto JCP, Prada AA, Cintra ML, Lima RB, Rached RB. Osteoma cutâneo. *An Bras Dermatol*. 1995;70:39-41.
3. Altman JF, Nehal KS, Busam KJ, Halpern AC. Treatment of primary osteoma cutis with incision, curettage, and primary closure. *J Am Acad Dermatol*. 2001;44:96-9.
4. Kaminsky A, Gurfinkiel A, Diaz M. Osteomas miliares múltiples de la piel. *Dermatol argent*. 2002;8:142-5.
5. Bergonse FN, Nico MM, Kavamura MI, Sotto MN. Miliary osteoma of the face: a report of 4 cases and review of the literature. *Cutis*. 2002;69:383-386.
6. Fazeli P, Harvell J, Jacobs MB. Osteoma cutis (cutaneous ossification). *West J Med*. 1999;17:243-245.
7. Ispub.com. [homepage]. Wang JF, Sarma DP. Acquired perforating osteoma cutis. *The Internet Journal of Dermatology*; ISSN: 1531-3018; 2007; vol.5; nº1. [Acesso: 14 Ago.2008]. Disponível em: <http://www.ispub.com/ostia/index>.
8. Douri T, Shawaf AZ. Plate-like cutaneous osteoma on the scalps. *Dermatol Online J*. 2006;12. [Acesso 14 Ago. 2008]. Disponível em: www.dermatology.cdlib.org/.
9. Emedicine.com [homepage]. Kevaghn PF. Osteoma cutis. [Acesso 19 Out. 2006]. Disponível em: <http://www.emedicine.com/derm/topic>
10. Thielen AM, Stucki L, Braun RP, Masouyé I, Germanier L, Harms M, et al. Multiple cutaneous osteomas of the face associated with chronic inflammatory acne. *J Eur Acad Dermatol Venereol*. 2006;20:321-6.
11. Burford C. Pigmented osteoma cutis secondary to long-term tetracyclines. *Australas J Dermatol*. 2007;48:134-6.
12. Brodtkin RH, Abbey AA. Osteoma cutis: a case of probable exacerbation following treatment of severe acne with isotretinoin. *Dermatologica*. 1985;170:210-2.
13. Ahn SK, Won JH, Choi EH, Kim SC, Lee SH. Perforating plate-like osteoma cutis in a man with solitary morphea profunda. *Br J Dermatol*. 1996;134:949-52.
14. Grandhe N, Dogra S, Saikia U, Handa S. Acquired perforating primary osteoma cutis. *Derm Venerol*. 2004;84:489-490.
15. Boschert MT, Puckett CL. Osteoma cutis of the hand. *Plast Reconstr Surg*. 2000;105:1017-8.

MAILING ADDRESS / ENDEREÇO PARA CORRESPONDÊNCIA:
 Ian Goedert Leite Duarte
 Avenida Andradas, 2.287, conj. 1.005 - Santa Efigênia
 30120-010 Belo Horizonte - MG - Brazil
 Phone: 31 3241-6976, 31 8482-0784
 E-mail: iangduarte@terra.com.br

How to cite this article/Como citar este artigo: Duarte IGL. Multiple osteoma cutis on the face: minimally invasive therapeutics in patients with acne sequel - case reports . *An Bras Dermatol*. 2010;85(5):695-8.