



# Immunological mapping in hereditary epidermolysis bullosa\*

## Imunomapeamento nas epidermólises bolhosas hereditárias

Zilda Najjar Prado de Oliveira<sup>1</sup>  
Lígia M. I. Fukumori<sup>3</sup>

Alexandre M. Périgo<sup>2</sup>  
Valéria Aoki<sup>4</sup>

**Abstract:** Immunological mapping, an immunofluorescence technique, is currently the method most used to diagnose and differentiate the principal types of hereditary epidermolysis bullosa, since this technique is capable of determining the level of cleavage of this mechanobullous disease

**Keywords:** Collagen; Epidermolysis bullosa; Laminin; Fluorescence Microscopy

**Resumo:** O imunomapeamento, uma técnica de imunofluorescência, é o método atual mais utilizado para o diagnóstico laboratorial e a diferenciação dos principais tipos de epidermólise bolhosa hereditária, uma vez que determina o plano de clivagem na junção dermo-epidérmica das doenças mecano-bolhosas.

**Palavras-chave:** Colágeno; Epidermólise bolhosa; Laminina; Microscopia de fluorescência

### INTRODUCTION

Hereditary epidermolysis bullosa (EB) refers to a group of mechanobullous diseases characterized by the appearance of blisters or vesicles following the slightest trauma to the skin. They may affect only the skin or also the mucosae.<sup>1</sup> They have been classified into four major groups (simplex, junctional, dystrophic and the mixed form, which is extremely rare) and by at least 20 different clinical phenotypes in accordance with the level of cleavage and clinical and molecular characteristics (Table I).<sup>2,3</sup>

The principal forms of hereditary EB are a consequence of mutations in the codifying genes of the structural components of the keratinocytes and the dermal-epidermal junction: in epidermolysis bullosa simplex (EBS): keratins 5 and 14, plectin,  $\alpha 6\beta 4$  integrin, plakophilin-1 and desmoplakin; in junctional epidermolysis bullosa (JEB): laminin-332 (previously referred to as laminin 5), type XVII collagen (or bullous pemphigoid antigen 2 [BPAG2]) and  $\alpha 6\beta 4$  integrin; in dystrophic epidermolysis bullosa (DEB): type VII collagen. The mutations provoke alterations in these proteins that are responsible for the defects in adhesion between the structures that constitute the skin, leading to the formation of blisters.

Classification of the different forms of heredi-

tary EB improved following introduction of the transmission electron microscope, as first reported by Pearsons in 1962.<sup>4</sup> Later, monoclonal antibodies were used to improve the classification of phenotypes.<sup>5-8</sup> In 1991, Bonifas<sup>9</sup> was the first to demonstrate molecular alterations in a form of EB (EB simplex). Later, the molecular basis of the other subtypes of EB was established.

### DIAGNOSIS OF EPIDERMOLYSIS BULLOSA

Diagnosis of EB is based on clinical and laboratory findings; however, it is always important to take family history and the consanguinity of the parents into consideration. Apart from genetic differentiation, which is not available in the majority of cities in Brazil, the subtypes of EB can only be differentiated by immunohistochemical and ultrastructural evaluation. Subclassification is important in determining the risk of mucosal involvement, the development of neoplasias and premature death, and in providing genetic counseling.<sup>10-14</sup>

The most commonly requested laboratory test is anatomopathology, which is performed on biopsied material that includes the entire blister. Although this test is inconclusive for a diagnosis of epidermolysis

Approved by the Editorial Board and accepted for publication on 18.06.2010.

\* Study conducted at the Department of Dermatology, Laboratory of Skin Immunopathology, School of Medicine, University of São Paulo, São Paulo, Brazil.

Conflict of interest: None / *Conflito de interesse: Nenhum*

Financial funding / *Suporte financeiro:* Study sponsored by the National Council for Scientific and Technological Development (CNPq), grant # 303493/2008-9

<sup>1</sup> PhD, Professor, Department of Dermatology, School of Medicine, University of São Paulo, São Paulo, Brazil.

<sup>2</sup> Biologist, Department of Dermatology, Laboratory of Skin Immunopathology, School of Medicine, University of São Paulo, São Paulo, Brazil.

<sup>3</sup> Biologist, Department of Dermatology, Laboratory of Skin Immunopathology, School of Medicine, University of São Paulo, São Paulo, Brazil.

<sup>4</sup> PhD, Professor, Department of Dermatology, School of Medicine, University of São Paulo, São Paulo, Brazil.

**CHART 1:** Most recent classification of the group of hereditary epidermolysis bullosa

<b>EB simplex (EBS):</b>
Localized
Dowling-Meara
Muscular dystrophy
Autosomal recessive
Superficialis
Plakophilin-1 deficiency
Pyloric atresia
<b>Junctional epidermolysis bullosa (JEB):</b>
Herlitz
Non-Herlitz
Pyloric atresia
<b>Dominant dystrophic epidermolysis bullosa (DDEB):</b>
Generalized
Bullous dermolysis of the newborn
<b>Recessive dystrophic epidermolysis bullosa (RDEB):</b>
Severe generalized
Generalized other
Bullous dermolysis of the newborn.

bullosa, it is useful to differentiate it from other bullous dermatoses. Anatomopathology is able to differentiate EB simplex from the other forms of EB, since this is the only form in which the level of cleavage is intraepidermal. JEB and DEB cannot be differentiated by anatomopathology.

To determine the different planes of cleavage that characterize the various subtypes of EB, immunological mapping or transmission electron microscopy (TEM) must be performed. TEM also permits analysis of ultrastructural alterations in the keratinocytes and in the dermal-epidermal junction that are characteristic of subtypes of EB. TEM is considered the gold standard in laboratory methods for differentiation between the various forms of EB. However, it is expensive and time-consuming to perform and to interpret, does not permit cleavage to be visualized as a whole and is only available in specialized centers.

The diagnostic precision of immunological mapping is similar to that of electronic microscopy with the advantage that it is simpler and faster both to perform and to interpret.<sup>15</sup> Since it is associated with the use of monoclonal antibodies, it may be used to provide subsidies to differentiate the major subtypes of EB and the different altered structural proteins.<sup>3</sup> In addition to permitting visualization of the cleavage as a whole, immunological mapping differentiates the dominant from the recessive forms of DEB. It also has the advantage of permitting the biopsy sample to be stored in transport medium (Michel's transport medium) for transportation to the laboratory at

which evaluation will be performed, which could be in any location in the country or indeed around the world.<sup>16</sup> The material preserved in this medium should ideally be processed within seven days, although its antigenicity is preserved for several weeks.<sup>3</sup> This technique may also be useful in genetic counseling, particularly if performed in early pregnancy when a fetal skin biopsy permits the patient's prognosis to be established.<sup>15</sup>

Immunological mapping could be considered an indirect immunofluorescence technique, since it is first necessary to promote the formation of the immunocomplex by adding a primary antibody to the tissue under investigation. Next, a secondary antibody marked with fluorochrome is used to reveal this immunocomplex. Fluorochromes are dyes that emit light at a specific wavelength when stimulated by ultraviolet radiation. The most commonly used fluorochrome is fluorescein, which is lime-green in color.

A profound understanding of the dermal-epidermal constitution of the proteic structures present in the basement membrane zone (BMZ) and in the basal keratinocytes is crucial to ensure an accurate interpretation of immunological mapping. The BMZ is composed of a group of structures that combine and form anchoring complexes. In the upper portions of the BMZ, the intermediary filaments of the cytoskeleton in the basal cells are inserted into the plasma membrane of the basal cells, the hemidesmosomes. The anchoring filaments connect the hemidesmosomes to the lamina densa (LD) and anchoring fibrils, traversing the lamina lucida space. In the lower part of the BMZ, type VII collagen is present in the anchoring fibrils that stretch from the lamina densa towards the papillary dermis and join the interstitial collagen fibrils. Therefore, the BMZ connects the cytoskeleton of the basal cells with the network of interstitial collagen fibrils, thus providing support for the skin.<sup>16,17</sup> (Figure 1).

In the immunological mapping of epidermolysis bullosa simplex, understanding of keratins 5 and 14 of the keratinocytes (K5 and K14) is important. These combine to form the intermediary filaments and are altered in the majority of cases in which cleavage is intraepidermal, in the basal layer. In the other forms of epidermolysis bullosa, the following factors are relevant: laminin, when cleavage is in the lamina lucida (JEB), collagen IV for the sub-lamina densa (DEB), and collagen VII, a component of the anchoring fibrils, which is situated in the sub-lamina densa.<sup>16,17</sup> With previous knowledge of the components of the BMZ, the majority of the different types of hereditary epidermolysis bullosa can be identified using immunological mapping by analyzing the location of the fluorescent deposit.

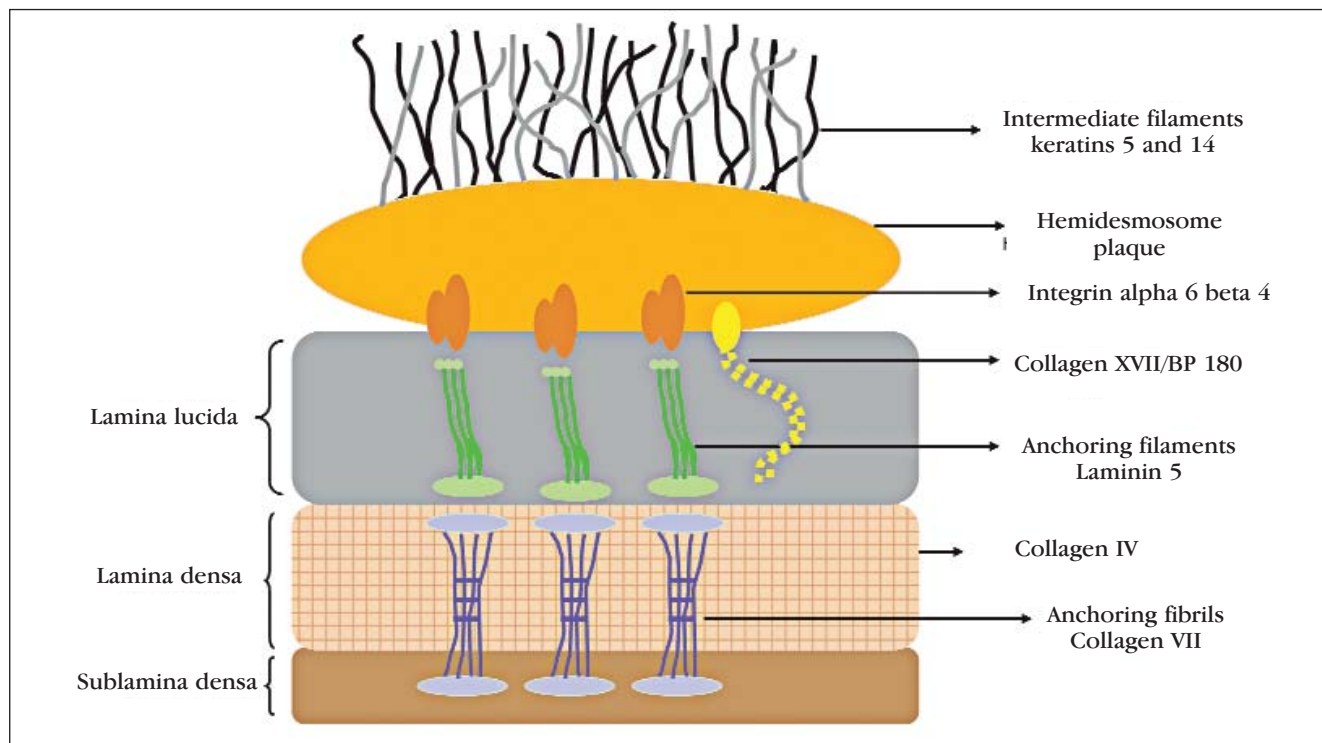


FIGURE 1: Figure showing the dermal-epidermal junction and the principal structural proteins involved in congenital epidermolysis bullosa

### IMMUNOLOGICAL MAPPING TECHNIQUE

The material to be processed should be obtained by performing a skin biopsy containing a recent whole blister or vesicle whose size should not be greater than the diameter of the punch biopsy instrument to ensure that the blister does not burst, which would prevent examination of the material. A wedge biopsy can also be performed to remove a skin sample containing the blister or vesicle, although this procedure demands greater skill from the dermatologist, since the skin may detach either at the time of incision or during suturing. If the patient's blisters are very large, a new lesion may be provoked by rotating a small spherical eraser (such as those found at the end of a pencil) over an area of skin on which there are no lesions until the epidermis separates from the dermis.

The fragment of skin obtained should be placed in Michel's transport medium or frozen while fresh in freezing medium. This procedure allows the antigenicity of the tissue to be reasonably well preserved, which is not possible with more aggressive methods such as fixing the sample in formalin or embedding it in paraffin. From the frozen tissue, 4- $\mu$ m-thick sections are cut and placed on silanized glass slides, which are then exposed to a panel of monoclonal antibodies bound to fluorescein that will bind them to structural proteins whose location in the BMZ is known. Since the location of these structures

is previously known, it is possible to show the level of cleavage more accurately by correlating the site at which the blister was formed with the distribution of fluorescence. The presence or absence of fluorescence with a particular antibody in the part of the epidermis and/or dermis at which cleavage occurs, gives a precise indication of the level at which that patient's lesion is situated.<sup>3</sup>

Different monoclonal antibodies are used around the world to mark the basement membrane zone. According to Fine,<sup>3</sup> the antibodies against the bullous pemphigoid antigen, laminin-1, type IV collagen and keratin 14 are important in determining the level of intraepidermal cleavage, whether it is in the lamina lucida or in the sub-lamina densa. The author also reports that to determine other types of alteration (recessive EBS, recessive JEB and DEB or DEB with muscular dystrophy), the mono and polyclonal antibodies against laminin 332 (previously known as laminin 5), type VII collagen, type XVII collagen, plectin and  $\alpha 6\beta 4$  integrin are necessary. There are clinical variants of EB in which fluorescence is absent with a certain monoclonal antibody, such as laminin 332 in Herlitz JEB and type VII collagen in RDEB. In these cases diagnosis can be made with certainty.

In the Immunopathology Laboratory of the Teaching Hospital of the School of Medicine, University of São Paulo, the following were used to mark the basement membrane zone:<sup>18</sup> hemidesmo-

somes – serum from a patient with bullous pemphigoid; lamina lucida – anti-laminin 5 monoclonal antibody; lamina densa – anti-collagen type IV monoclonal antibody; sub-lamina densa – anti-collagen type VII monoclonal antibody (anchoring fibrils). The monoclonal antibodies are acquired commercially and produced in specific mice lineages.<sup>3</sup>

An example of the protocol used in this laboratory is described as follows: tissue sections obtained from the patient's skin biopsy are exposed to the antibodies for 30 minutes in a steam chamber at room temperature. They are then washed in Tris buffer (pH 7.0) for 20 minutes. Binding of the primary antibodies to their corresponding antigens is revealed with the use of human anti-IgG conjugated to fluorescein to mark the bullous pemphigoid antigen (BPAG) and polyclonal murine anti-IgG is used to mark the other monoclonal antibodies. After 30 minutes, the sections are washed again as described above and the slides are prepared with buffered glycerine (pH 9.0) and covered with a glass coverslip to be read in a fluorescence microscope (epiluminescence or confocal microscopy).<sup>19</sup>

The principal types of hereditary EB can be identified by immunological mapping by analyzing the presence or absence of fluorescent deposit at a certain site. The following findings of the different EB subtypes are thus obtained:

**EPIDERMOLYSIS BULLOSA SIMPLEX (EBS)**

Cleavage occurs in the basal layer and deposits of fluorescence are found on the floor of the blister (dermal side) with all the antigenic markers, since the markers used (BPAG, laminin, types IV and VII collagen) are situated below the cleavage observed in the patient (Figure 2).

**JUNCTIONAL EPIDERMOLYSIS BULLOSA (JEB)**

Alterations occur in the proteins that comprise the anchoring filaments, which connect to the hemidesmosomes and to the anchoring fibrils. The level of cleavage occurs in the lamina lucida. With BPAG, a deposit of fluorescence is seen on the roof of the blister (epidermal side), while, with the other markers, fluorescence is found on the floor of the blister (dermal side) (Figure 3). In some cases, there may be deposits of fluorescence on the roof and on the floor of the blister with the anti-laminin antibody.

**DYSTROPHIC EPIDERMOLYSIS BULLOSA (DEB)**

Mutations are present in the genes that codify type VII collagen, the principal component of the anchoring fibrils that bind the BMZ to the dermis. The level of cleavage occurs in the sub-lamina densa. In dominant dystrophic epidermolysis bullosa (DDEB), fluorescence deposit occurs on the roof of the blister (epidermal side) with all the markers (Figure 4). In some cases, fluorescence may be found on the roof and the floor of the blister with the anti-collagen VII antibody.

In recessive dystrophic epidermolysis bullosa (RDEB), fluorescence is greatly reduced or absent with the anti-collagen antibody (Figure 5). The reduction or absence of fluorescence with the anti-collagen VII antibody allows definitive diagnosis to be made of this very severe type of EB.

**CONCLUSION**

Compared to electronic microscopy, immunological mapping has the advantage of being a fast technique that is simple both to perform and to interpret, identifies specific proteins and permits visualization

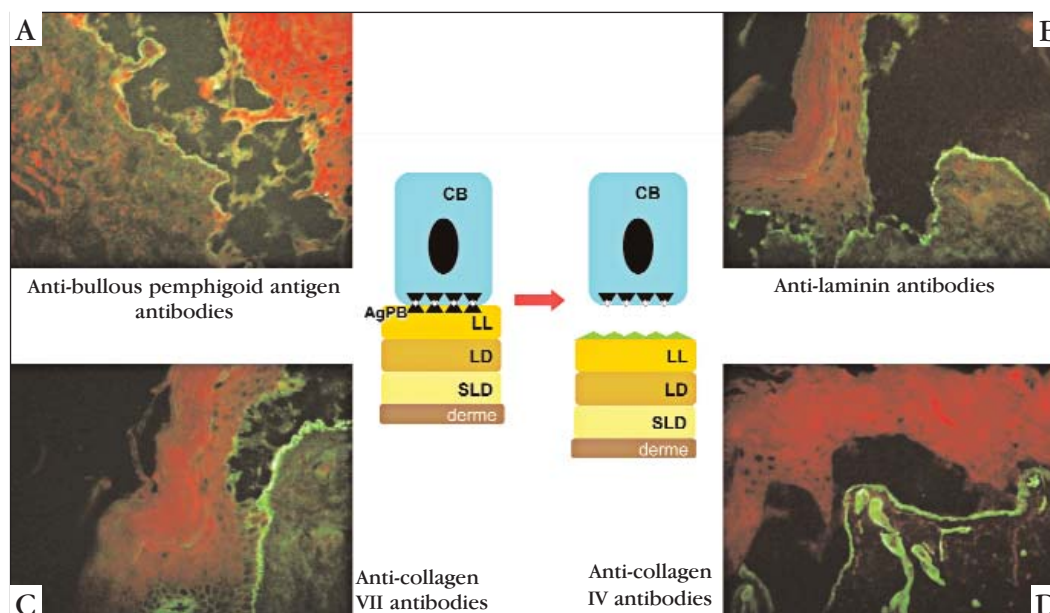


FIGURE 2: Figure showing the site of cleavage in epidermolysis bullosa simplex (EBS). A, B, C and D show the site of fluorescence deposit with the four principal marker antibodies (BC = basal cell; BPAG = bullous pemphigoid antigen; LL = lamina lucida; LD = lamina densa; SLD = sub-lamina densa). All the antibodies mark the floor of the blister, showing intraepidermal cleavage

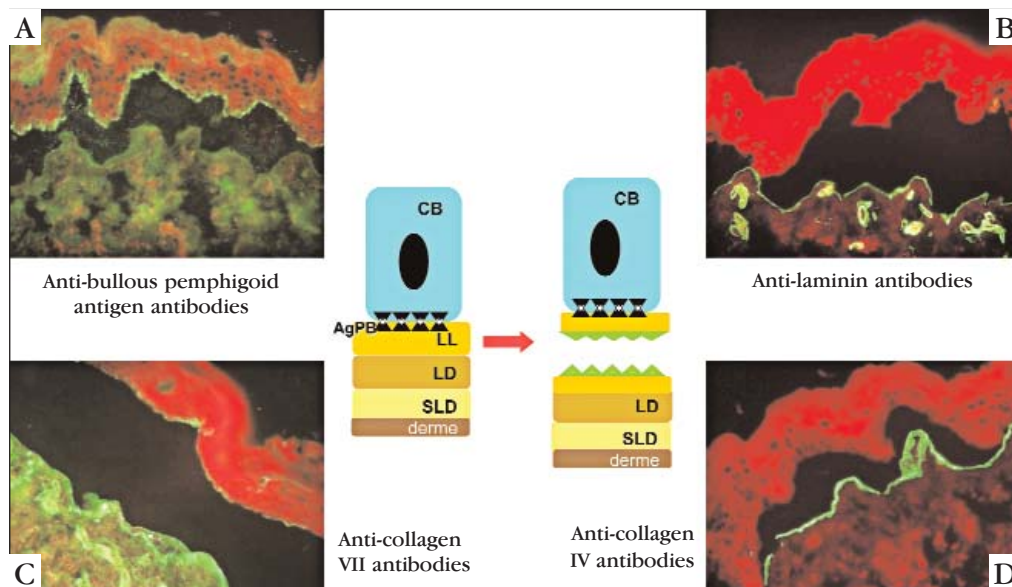


FIGURE 3: Figure showing the site of cleavage in junctional epidermolysis bullosa (JEB). A, B, C and D show the site of fluorescence deposit with the four principal marker antibodies (BC = basal cell; BPAG = bullous pemphigoid antigen; LL = lamina lucida; LD = lamina densa; SLD = sublamina densa). The anti BP antibody on the roof of the blister and the others on its floor indicate cleavage in the lamina lucida

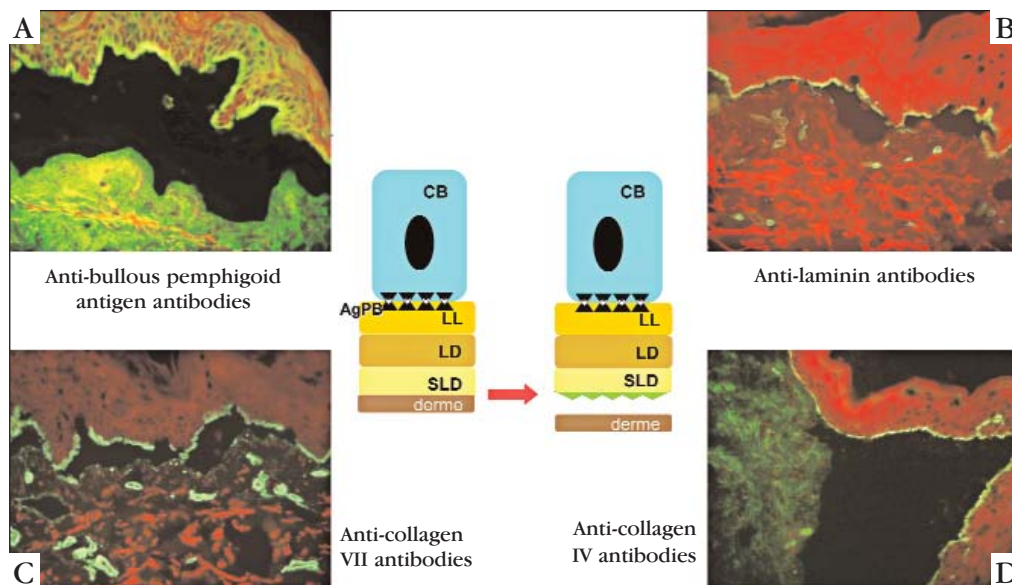


FIGURE 4: Figure showing the site of cleavage in dominant dystrophic epidermolysis bullosa (DDEB). A, B, C and D show the site of fluorescence deposit with the four principal marker antibodies (BC = basal cell; BPAG = bullous pemphigoid antigen; LL = lamina lucida; LD = lamina densa; SLD = sublamina densa). All the antibodies mark the roof of the blister, indicating cleavage in the sublamina densa

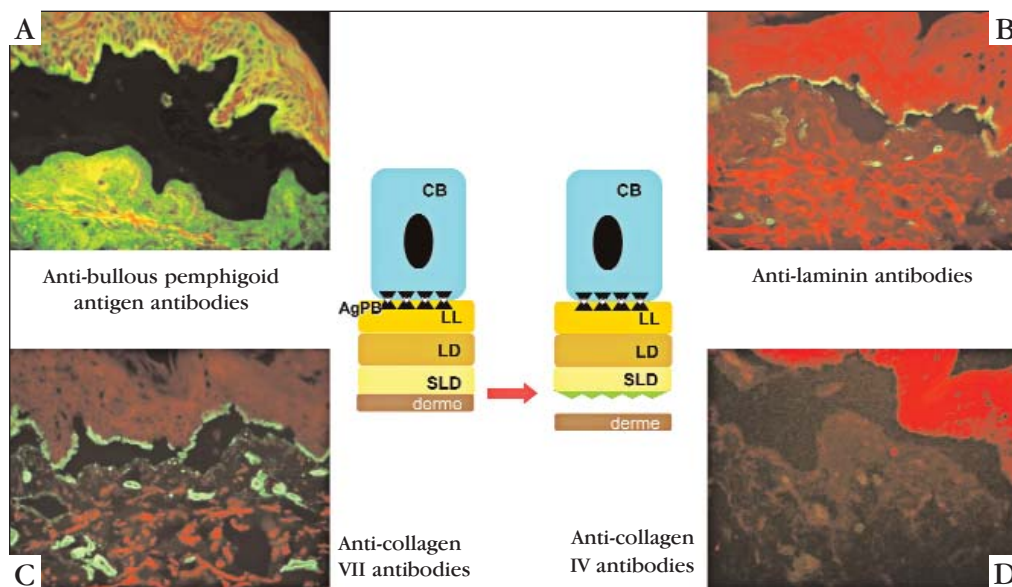


FIGURE 5: Figure showing the site of cleavage in recessive dystrophic epidermolysis bullosa (RDEB). A, B, C and D show the site of fluorescence deposit with the four principal marker antibodies (BC = basal cell; BPAG = bullous pemphigoid antigen; LL = lamina lucida; LD = lamina densa; SLD = sublamina densa). Three antibodies mark the roof of the blister, indicating cleavage in the sublamina densa and negativity of the anti-collagen VII antibody

of the cleavage as a whole. Determining the level of cleavage allows EB to be classified into its subgroups (EBS, JEB and DEB) and sometimes variants such as DDEB and RDEB. The technique allows the dominant and recessive forms of DEB to be detected with less work and expense than electronic microscopy.<sup>20</sup> Another advantage of immunological mapping is the possibility of being able to transport the specimen immersed in Michel's transport medium, where it can

remain for up to one week prior to laboratory investigation. Immunological mapping is currently the method most commonly used for laboratory diagnosis and differentiation of the principal types of epidermolysis bullosa. Determination of the subtypes of EB is relevant for genetic counseling and to establish the prognosis of the disease. Furthermore, in some countries, it enables an intrauterine diagnosis of EB to be reached based on a skin biopsy from the fetus. □

## REFERENCES

- Gedde-Dahl Jr T. Epidermolysis Bullosa. A clinical, genetic and epidemiologic study. Baltimore: Johns Hopkins University Press; 1971. p.1-180.
- Fine JD, Eady RA, Bauer EA, Briggaman RA, Bruckner-Tuderman L, Christiano A, et al. Revised classification system for inherited epidermolysis bullosa: Report of the Second International Consensus Meeting on diagnosis and classification of epidermolysis bullosa. *J Am Acad Dermatol.* 2000;42:1051-66.
- Fine JD, Eady RA, Bauer EA, Bauer JW, Bruckner-Tuderman L, Heagerty A, et al. The classification of inherited epidermolysis bullosa (EB): report of the Third International Consensus Meeting on Diagnosis and Classification of EB. *J Am Acad Dermatol.* 2008;58:931-50.
- Pearson RW. Studies on the pathogenesis of epidermolysis bullosa. *J Invest Dermatol.* 1962;39:551-75.
- Goldsmith LA, Briggaman RA. Monoclonal antibodies to anchoring fibrils for the diagnosis of epidermolysis bullosa. *J Invest Dermatol.* 1983;81:464-6.
- Fine JD, Breathnach SM, Hintner H, Katz SI. KF-1 monoclonal antibody defines a specific basement membrane antigen defect in dystrophic forms of epidermolysis bullosa. *J Invest Dermatol.* 1984;82:35-8.
- Heagerty AH, Kennedy AR, Leigh IM, Purkis P, Eady RA. Identification of an epidermal basement membrane defect in recessive forms of dystrophic epidermolysis bullosa by LH 7:2 monoclonal antibody: use in diagnosis. *Br J Dermatol.* 1986;115:125-31.
- Heagerty AH, Kennedy AR, Eady RA, Hsi BL, Verrando P, Yeh CJ, et al. GB3 monoclonal antibody for diagnosis of junctional epidermolysis bullosa. *Lancet.* 1986;1:860.
- Bonifas JM, Rothman AL, Epstein E. Linkage of epidermolysis bullosa simplex to probes in the region of keratin gene clusters on chromosomes 12q and 17q. *J Invest Dermatol.* 1991;39:503A.
- Fine JD, Johnson LB, Weiner M, Stein A, Cash S, Deleoz J, et al. Eye involvement in inherited epidermolysis bullosa (EB): experience of the National EB Registry. *Am J Ophthalmol.* 2004;138:254-62.
- Fine JD, Johnson LB, Weiner M, Stein A, Cash S, Deleoz J, et al. Pseudosyndactyly and musculoskeletal contractures in inherited epidermolysis bullosa: experience of the National Epidermolysis Bullosa Registry, 1986-2002. *J Hand Surg.* 2005;30:4-22.
- Fine JD, Johnson LB, Weiner M, Suchindran C. Tracheolaryngeal complications of inherited epidermolysis bullosa. *Laryngoscope.* 2007;117:1652-60.
- Fine JD, Johnson LB, Weiner M, Suchindran C. Cause-specific risks of childhood death in inherited epidermolysis bullosa. *J Pediatr.* 2008;152:276-80.
- Fine JD, Johnson LB, Weiner M, Suchindran C. Gastrointestinal complications of inherited epidermolysis bullosa: cumulative experience of the National Epidermolysis Bullosa Registry. *J Pediatr Gastroenterol Nutr.* 2008;46:147-58.
- Hintner H, Fritsch PO, Foidart JM, Stingi G, Schuler G, Katz SI. Expression of basement membrane zone antigens at the dermo-epibolic junction in organ cultures of human skin. *J Invest Dermatol.* 1980;74:200-4.
- Mutasim D, Pelc N, Supapannachart N. Established methods in the investigation of bullous diseases. *Dermatol Clinics.* 1993;11:399-418.
- Burgeson RE, Christiano AM. The dermal-epidermal junction. *Curr Opin Cell Biol.* 1997;9:651-8.
- Alves ACF, Cymbalista NC, Oliveira ZNP, Machado MCRM, Sotto MN, Prianti MG, et al. Imunomapeamento no diagnóstico das epidermólises bolhosas hereditárias distróficas. *An Bras Dermatol.* 2001;76:551-60.
- Marinkovich MP. Update on inherited bullous dermatoses. *Dermatol Clin.* 1999;17:473-85.
- Oliveira ZNP. Imunomapeamento nas Epidermólises bolhosas. 3 ed. In: Rivitti EA, Sampaio SAP. *Dermatologia.* São Paulo: Artes Médicas; 1998.

MAILING ADDRESS / ENDEREÇO PARA CORRESPONDÊNCIA:

Valéria Aoki

Av. Dr. Enéas de Carvalho Aguiar, 255.

Laboratório de Imunopatologia Cutânea

3º andar ICHC, sala 3016.

05403 000 - São Paulo - SP, Brazil.

Phone./fax: 11 3069-8036.

E-mail: valaoki@hotmail.com

How to cite this article/Como citar este artigo: Oliveira ZNP, Perigo AM, Fukumori LMI, Aoki V. Immunological mapping in hereditary epidermolysis bullosa. *An Bras Dermatol.* 2010;85(6):856-61.