

Solitary subungual neurofibroma: a previously unreported finding in a male patient^{*}

Neurofibroma subungueal solitário: relato de um caso inédito no sexo masculino

Dionne de Almeida Stolarczuk¹
Fernanda da Marca Filgueiras¹
Solange Cardoso Maciel Costa Silva³

Ana Luiza Furtado da Silva¹
Maria de Fátima Guimarães Scotelaro Alves²

Abstract: A neurofibroma is a hamartomatous proliferation of neuromesenchymal origin. It may be found in combination with neurofibromatosis or in the form of a solitary tumor. Clinical presentation as a solitary subungual tumor is very rare. Neurofibroma is more common in females and surgery is the treatment of choice. The present paper reports the case of a male patient with a subungual tumor on his toe. Biopsy and immunohistochemistry findings were compatible with a neurofibroma. To date, fewer than ten cases of subungual neurofibromas unassociated with von Recklinghausen's disease have been documented, this being the first case to be reported in Brazil and the only report worldwide to have described this condition in a male patient.

Keywords: Neoplasms, nerve tissue; Neurofibroma; Rare diseases; Solitary fibrous tumors

Resumo: Neurofibroma é uma proliferação hamartomatosa de origem neuromesenchimal. Pode ser encontrado associado à neurofibromatose ou como tumor solitário, sendo sua apresentação subungueal solitária bastante rara. É mais frequente em pacientes do sexo feminino e a cirurgia é o tratamento de escolha. Relata-se um caso de um paciente masculino, com lesão tumoral subungueal no pododáctilo, cuja biópsia e imuno-histoquímica foram compatíveis com neurofibroma. Até a presente data, menos de dez casos sobre neurofibromas subungueais sem associação com doença de Von Recklinghausen foram documentados, sendo este o primeiro caso relatado no Brasil e o único no sexo masculino no mundo.

Palavras-chave: Doenças raras; Neoplasias de tecido nervoso; Neurofibroma; Tumores fibrosos solitários

INTRODUCTION

Subungual tumors are responsible for various abnormalities of the nail bed and in general are underdiagnosed as a result of their nonspecific characteristics. Neurofibromas have also been described at this site. They may occur in association with neurofibromatosis or as solitary tumors, their pathogenesis under these conditions being unclear. In both cases, this site is rare. Growth is usually slow, with little local symptomatology and the conditions occur typically in middle-aged women.

Other tumors such as fibrokeratoma, Koenen's tumor, glomus tumor, epidermoid cyst and squamous

cell carcinoma may clinically mimic neurofibroma and should be included in the differential diagnosis. Surgery of the nail aids diagnosis and treatment; however, imaging exams such as radiography and ultrasonography may also help visualize the size of the lesions and determine whether there is compression of bone structures.

Few cases of solitary subungual neurofibromas unassociated with von Recklinghausen's disease have been described in the literature, making this presentation extremely rare.

Received on 13.12.2009.

Approved by the Advisory Board and accepted for publication on 20.06.10.

^{*} Study conducted at the Pedro Ernesto Teaching Hospital, State University of Rio de Janeiro (UERJ), Rio de Janeiro, RJ, Brazil.

Conflict of interest: None / *Suporte financeiro: Nenhum*

Financial funding: None / *Conlito de interesse: Nenhum*

¹ Postgraduate Specialization in Dermatology at the Pedro Ernesto Teaching Hospital, State University of Rio de Janeiro (UERJ). Currently undergoing postgraduate specialization training at the Pedro Ernesto Teaching Hospital, State University of Rio de Janeiro (UERJ), Rio de Janeiro, RJ, Brazil.

² PhD. Adjunct Professor of Dermatology, Pedro Ernesto Teaching Hospital, State University of Rio de Janeiro (UERJ), Rio de Janeiro, RJ, Brazil.

³ PhD. Coordinator of the Dermatology Course, Pedro Ernesto Teaching Hospital, State University of Rio de Janeiro (UERJ), Rio de Janeiro, RJ, Brazil.

CASE REPORT

A 51-year old, white male patient from Ceará with no comorbidities complained of the appearance of a rounded lesion on the nail of the fourth toe of his right foot, which had appeared approximately eight months previously. There had been no prior abnormalities and he denied any trauma or pain at the site. Examination of the toe showed a tumorous lesion with a smooth, rounded, regular, normochromic surface, measuring 1.6 x 1.8 cm, on the subungual region of the fourth toe of his right foot (Figure 1). No other abnormalities were found at physical examination, and mycological and laboratory tests also showed no abnormalities. Radiography found no bone abnormalities and ultrasonography revealed the image of a hypoechoic nodule measuring 15 x 14 mm, with no flow at Doppler. Biopsy was performed under local anesthesia and included partial excision of the lesion, which had a polypoid appearance, was unencapsulated and had a whitish appearance in its interior, occupying the digital pulp (Figure 2). Histopathology showed narrow fusiform cells with undulated nuclei in pale stromal collagen (Figure 3). Immunohistochemistry was positive for S100 and CD34 and negative for HHF-35, desmin and actin 1 to 4. A diagnosis of solitary neurofibroma was confirmed and the patient was then submitted to a further surgical procedure that consisted of an incision into the digital pulp of the toe and removal of the tumor from this area and from under the nail bed. When the nail plate was removed for exploration, the tumor was found to extend as far as the lateral nail fold. Complete excision was then performed. Up to the present moment, six months after surgery, there has been no recurrence of the disease.

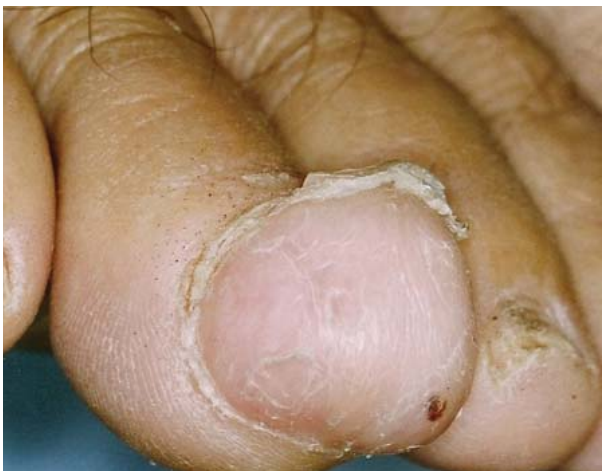

FIGURE 1: Rounded, regular, normochromatic tumorous lesion in the subungual region of the fourth toe of the patient's right foot

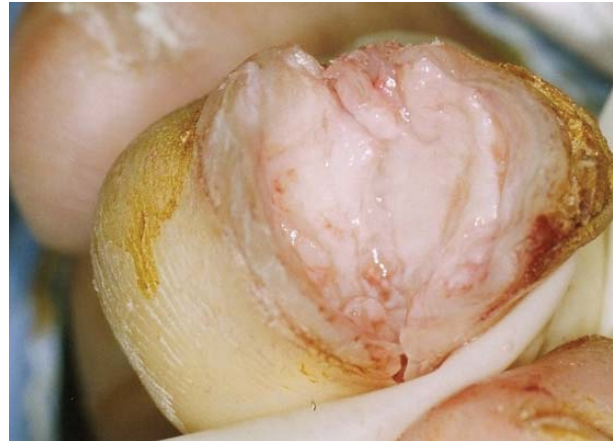

FIGURE 2: Unencapsulated, whitish, polypoid lesion occupying the digital pulp

DISCUSSION

First described by Von Recklinghausen,¹ neurofibromas may present as multiple or solitary tumors and may be associated or not with neurofibromatosis. They consist of hamartomatous proliferations of neuro-mesenchymal components, including Schwann cells, fibroblasts, perineural cells and mastocytes.² The proportion of cells varies in each case. Immunohistochemistry of the tumor markers may show positivity for S100 protein, Melan-A, tyrosinase and CD34, among others.³

They present as circumscribed, normochromic and unencapsulated nodules, ranging from 0.2 to 2 cm in size. In 90% of cases of neurofibroma, the tumor is solitary;² however, its presentation in the

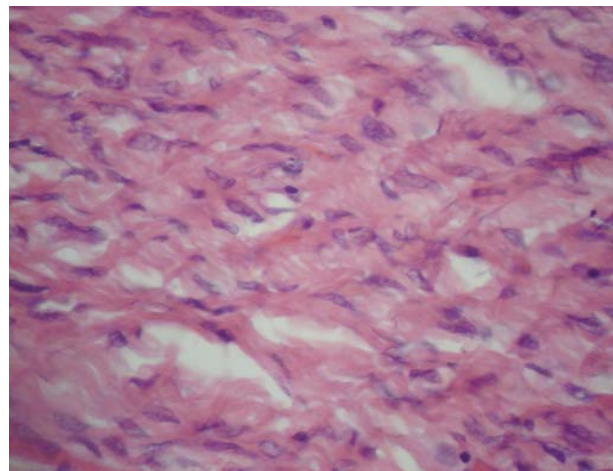


FIGURE 3: Fusiform and narrow cells with undulated nuclei in pale collagen stroma

subungual region is extremely rare and few cases have been described. Usually painless, they may cause pain if they are compressing adjacent structures.⁴ When situated in the proximal region, they may produce a longitudinal depression mimicking Koenen's tumor or chronic paronychia,⁵ whereas in the subungual region they may lead to onychodystrophy or an increase in local volume.^{6,4} Either fingers or toes may be affected.

In 1986, Shelley published one of the first reports of a subungual neurofibroma affecting the second finger of a middle-aged female patient. Nevertheless, no information was provided on whether there was associated neurofibromatosis.⁷

Later, further articles were published describing similar cases; however, with no evidence of neurofibromatosis. The symptoms described ranged from onychodystrophy,⁴ subungual hyperkeratosis,^{6,8} an increase in the size of the affected digit and even an increase in the curvature of the nail.⁸ In the patient in the present case, the lesion was confined exclusively to the subungual region, with no specific alterations to the nail plate.

Histopathology is of the utmost importance in the diagnosis of neurofibroma, with findings consisting of a fine fibrillary network of fusiform cells in vascular, fibrotic or edematous stroma.² At histopathology, differential diagnosis should first be made with schwannoma, since the cell types are similar in both pathologies and nuclei arranged in palisade-like structures may be present in both conditions. Nevertheless, in neurofibromas, the formation of Verocay bodies is very rare and the proportion of axons in relation to Schwann cells is less than 1:1.² In addition, immunohistochemistry may also be helpful in differentiating the two tumors, since reactivity for the S100 protein (positive in Schwann cells) is greater in schwannomas, whereas in neurofibromas it is less uniform and less intense. This occurs because, unlike schwannomas, which are formed exclusively of Schwann cells, neurofibromas consist of disorganized and dispersed Schwann cells associated with other cells.⁹ Superficial acral fibromyxoma, a benign form of neoplasia that occasionally occurs in the subungual region, should also be included in the differential diagnosis.¹⁰ It presents as an unencapsulated lesion consisting of fusiform cells in a myxoid stroma;¹¹ nevertheless, immunohistochemistry is negative for the S100 protein, with positivity only for CD34.^{10,11}

Electronic microscopy, described in a case published by Niizuma in 1991, showed Schwann cells, fibroblasts, parenchyma cells and collagen fibrils.¹² In addition, the majority of the parenchyma cells showed positivity for the S100 protein as in the present case, confirming the presence of Schwann cells. Another immunohistochemical marker present in this case, CD34, confirms the neural and fibrous nature of the lesions, as well as the presence of vascularization, since it is a marker of endoneurial fibroblasts¹⁰ and endothelial cells.⁹

A further case report was published in 2004 referring to a 50-year old female patient with a lesion on her third toe and no clinical symptomatology whatsoever. The author raised the possibility of similar cases being underdiagnosed.¹³

According to a review article published by Roldan-Marin in 2006, these tumors are more common in middle-aged women and there is usually no recurrence following excision of the lesion.¹⁴ None of the articles cited in this review paper mentioned trauma preceding the condition and all were reported in female patients. This fact may be a result of the greater concern of women with body esthetics, since the tumor presents asymptotically, with changes to the nail being the only sign in the great majority of cases. Furthermore, because of the different forms of clinical presentation, many cases may be wrongly diagnosed as onychomycosis or trauma, leading to underdiagnosis of these tumorous lesions. Hormones do not appear to have any effect on the onset or growth of these lesions, either in their localized form or even when associated with neurofibromatosis.

Radiography of the affected site is important in order to evaluate bone involvement; however, only two cases revealed phalangeal compression and there was no bone invasion.^{12,4} Likewise, radiography in the present case showed no signs of bone involvement. Removal of the affected nail plate is essential to enable visualization and evaluation of the tumor, with curative resection of the lesion.

Up to the present date, fewer than 10 cases of subungual neurofibromas unassociated with Von Recklinghausen's disease have been reported and, following a detailed review of the available literature, to the best of our knowledge this is the first report of a solitary subungual neurofibroma in Brazil and the only report worldwide of this condition in a male patient. □

REFERENCES

1. Gadelha AR, Akel PBM, Sena RS, Souza MLG, Silva MHCR, Bacry JNA. Neurofibromatose segmentar: relato de caso. *An Bras Dermatol*. 1999;74:169-71.
2. Argenyi ZB. Neurofibroma. In: Bologna JL, Lorzio J, Rapini RP, editors. *Dermatology*. 2nd ed. London: Mosby; 2008.
3. Fetsch JF, Michal M, Miettinen M. Pigmented (Melanotic) neurofibroma. A clinicopathologic and immunohistochemical analysis of 19 lesions from 17 patients. *Am J Surg Pathol*. 2000;24:331-43.
4. Dangoisse C, Andre J, De Dobbeleer G, Van Geertruyden J. Solitary subungual neurofibroma. *Br J Dermatol*. 2000;143:1116-7.
5. Baran R, Dawber RPR, editors. *Diseases of the Nails and Their Management*. 2nd ed. London: Blackwell Science; 1994. p.460.
6. Bhushan M, Telfer NR, Chalmers RJ. Subungual neurofibroma: an unusual cause of nail dystrophy. *Br J Dermatol*. 1999;140:777-8.
7. Shelley ED, Shelley WB. Exploratory nail plate removal as a diagnosis aid in painful subungual tumors: glomus tumor, neurofibroma and squamous cell carcinoma. *Cutis*. 1986;38:310-2.
8. Baran R, Haneke E. Subungual myxoid neurofibroma on the thumb. *Arch Derm Venereol*. 2001;81:210-1.
9. Fcm.unicamp. [internet]. Textos ilustrados de neuropatologia e neuroimagem; c2007. [Acesso: 12 Fev. 2010]. Disponível em: <http://www.fcm.unicamp.br/deptos/anatomia/textosneuro.html>
10. Tardio JC. CD34-reactive tumors of the skin. An updated review of an ever-growing list of lesions. *J Cutan Pathol*. 2009;36:89-102.
11. André J, Theunis A, Richert B, de Saint-Aubain N. Superficial acral fibromyxoma: Clinical and pathological features. *Am J Dermatopathol*. 2004;26:472-4.
12. Niizuma K, Iijima KN. Solitary neurofibroma: a case of subungual neurofibroma on the right third finger. *Arch Dermatol Res*. 1991;283:13-5.
13. Sugiura K, Sugiura M, Hayakawa R, Kato Y, Sakamoto N, Osada A, et al. Solitary neurofibroma: an uncommon location. *Int J Dermatol*. 2004;43:451-3.
14. Roldan-Marin R, Dominguez-Cherit J, Vega-Memije ME, Toussaint-Caire S, Hojyo-Tomoka MT, Dominguez-Soto L. Solitary subungual neurofibroma: an uncommon finding and a review of the literature. *J drugs Dermatol*. 2006;5:672-4.

MAILING ADDRESS / ENDEREÇO PARA CORRESPONDÊNCIA:

Dionne Stolarczuk

Av. General Felicíssimo Cardoso, 835/2007 - Bloco 2
Barra da Tijuca

22631-360 Rio de Janeiro (RJ) – Brasil

E-mail: docsto@hotmail.com

How to cite this article/*Como citar este artigo*: Stolarczuk DA, Silva ALF, Filgueiras FM, Alves MFGS, Silva SCMC. Solitary subungual neurofibroma: a previously unreported finding in a male patient. *An Bras Dermatol*. 2011;86(3):569-72.