

Case for diagnosis Caso para diagnóstico

Mariana Carvalho Costa ¹
Amanda Hertz ¹
David Rubem Azulay ³

Eduardo Bornhausen Demarch ¹
Francisco Burnier Carlos Pereira ²

HISTORY OF THE DISEASE

A 38-year old female patient presented with multiple, normochromic or slightly yellowish papules measuring 2-5 mm in diameter, with a keratotic, glossy surface, clustered symmetrically on the dorsal-ventral axis of her hands and feet (Figures 1 and 2). There were also some papules on the backs of her hands and feet that were intensified on the bony protuberances. The lesions were asymptomatic, had appeared in childhood and had been stable ever since. The patient had had no previous treatment. Her mother and maternal grandmother had the same clinical condition at the same anatomical sites, also beginning before they reached ten years of age. Histopathology of skin revealed hyperkeratosis and acanthosis. Orcein staining revealed a reduction in elastic fibers, which were irregular and fragmented (Figure 3).

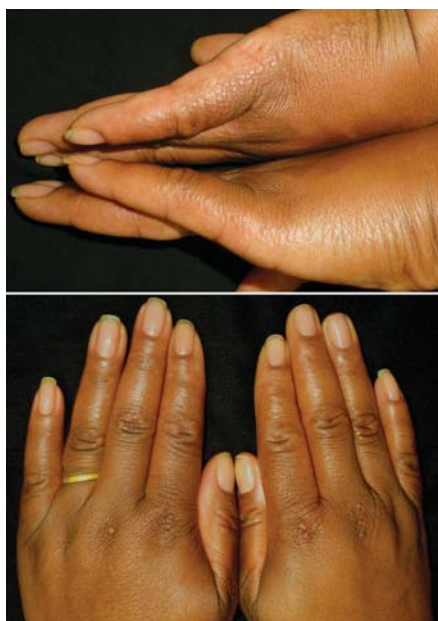

FIGURE 1: Multiple yellowish papules with a glossy surface, measuring 2-4 mm in diameter, located symmetrically on the lateral margin and the dorsal surface of both hands

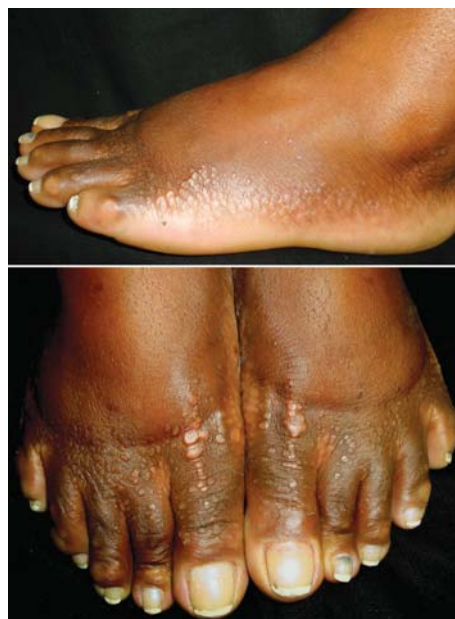

FIGURE 2: The same lesion pattern is presented on the lateral margin and dorsal surface of the foot

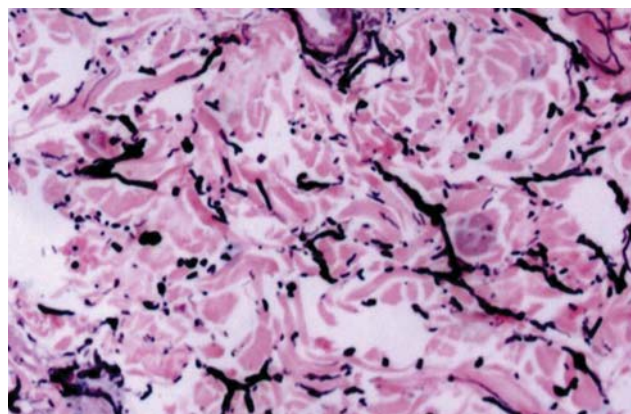


FIGURE 3: Orcein staining showing fragmented elastic fibers in the reticular dermis (elastorrhexis)

Received on 05.12.2010

Approved by the Advisory Board and accepted for publication on 09.02.2011.

* This study was conducted at the Prof. Rubem David Azulay Institute of Dermatology, Santa Casa de Misericórdia do Rio de Janeiro, Rio de Janeiro, RJ, Brazil.

Conflict of interest: None / *Conflito de interesse: Nenhum*

Financial funding: None / *Suporte financeiro: Nenhum*

¹ MD. Postgraduate student, Prof. Rubem David Azulay Institute of Dermatology, Santa Casa de Misericórdia do Rio de Janeiro, Rio de Janeiro, RJ, Brazil.

² PhD in Dermatology awarded by the Federal University of Rio de Janeiro. Preceptor, Outpatient Dermatologic Surgery, Prof. Rubem David Azulay Institute of Dermatology, Santa Casa de Misericórdia do Rio de Janeiro, Rio de Janeiro, RJ, Brazil.

³ Master's degree in Dermatology awarded by the Federal University of Rio de Janeiro. Head, Dermatology Unit, Prof. Rubem David Azulay Institute of Dermatology, Santa Casa de Misericórdia do Rio de Janeiro, Rio de Janeiro, RJ, Brazil.

DISCUSSION

Acrokeratoelastoidosis is a type of marginal keratoderma that principally affects the lateral portion of the palmoplantar regions and was first described by Oswaldo Costa, a dermatologist from the Brazilian state of Minas Gerais, at the beginning of the 1950s.^{1,2} It is a rare autosomal-dominant genodermatosis, probably related to chromosome 2, although it may also occur sporadically.³ According to the literature, there is no predominance of gender or race. Its pathogenesis remains to be clarified; however, a history of chronic trauma has been indicated as a possible causal factor. It is speculated that the keratotic papules seen clinically may be the result of an exaggerated production of filaggrin that accumulates as a dense band over the granular layer prior to being incorporated into the protein matrix of mature epidermal keratin.³

Clinically, the condition is characterized by multiple, yellowish papules that are sometimes glossy and keratotic, measuring 2-4 mm in diameter, sometimes umbilicated, located symmetrically on the lateral margin of the hands and feet, symmetry being the most characteristic clinical indication of this disorder.^{4,5} The edge of the fingers or toes, the wrists and the anteroposterior surfaces of the legs may also be affected. There is skin thickening over the metacarpophalangeal, metatarsophalangeal and proximal interphalangeal joints. Although there is no general consensus, some investigators have reported an increase in the number of papules over time. Rapid progression during pregnancy has also been reported.⁶ Furthermore, there may be an association with hyperhidrosis.⁴

The most common findings at histopathology are hyperkeratosis, mild acanthosis and alterations in the elastic fibers of the dermis, which are fewer and fragmented (elastorrhexis).^{7,8}

In relation to the differential diagnosis, focal acral hyperkeratosis has a fairly similar clinical appearance; however, at histopathology, elastorrhexis is not seen and the alterations are restricted to the epidermis (hyperkeratosis and acanthosis).⁹ Another condition with a similar clinical appearance is keratoelastoidosis marginalis (Ramos and Silva's marginal keratoderma), which is generally associated with intense sun exposure and marked actinic damage. In addition, other conditions that should be taken into consideration in the differential diagnosis include acrokeratosis verruciformis of Hopf, degenerative collagenous plaques and punctate palmoplantar keratoderma.³

Because of the asymptomatic nature of the lesions and since they are not associated with morbidity, no treatment is required. However, if treatment is requested for esthetical reasons, topical and systemic options are available, although response is unsatisfactory in the majority of cases. There have been reports of topical treatment with corticosteroids, tretinoin, salicylic acid, liquid nitrogen and coal tar. Of the systemic options, the use of corticosteroids, dapsone, antibiotics and methotrexate has been reported. Acitretin appears to be the most effective, although there is generally a recurrence after discontinuation of treatment. Surgical techniques include cryosurgery and surgery with laser erbium: yttrium-aluminum-garnet (Er:YAG); however, as in the above-mentioned treatment options, little improvement is achieved.⁷⁻¹⁰ □

Abstract: Acrokeratoelastoidosis is a type of palmoplantar keratoderma first described by Oswaldo Gonçalves Costa, a Brazilian Dermatologist from the state of Minas Gerais. It is a rare autosomal-dominant genodermatosis; however it may occur sporadically. The disease is not congenital; rather, its onset occurs in childhood or adolescence. Clinically, the condition is characterized by multiple yellowish papules, sometimes glossy and keratotic, measuring approximately 2-4 mm in diameter, sometimes umbilicated, and located symmetrically on the sides of the hands and feet, symmetry being the most typical sign. The most common histopathological findings are hyperkeratosis, mild acanthosis and elastorrhexis, as revealed by orcein staining.

Keywords: Elastic tissue; Foot dermatoses; Hand dermatoses; Keratoderma, palmoplantar

Resumo: A acroceratoelastoidose é um tipo de ceratodermia palmoplantar, originalmente descrita pelo dermatologista mineiro Oswaldo Gonçalves Costa. É uma rara genodermatose autossômica dominante, embora possa ocorrer de forma esporádica. A doença não é congênita, com as primeiras manifestações na infância e adolescência. O quadro clínico é caracterizado por múltiplas pápulas amareladas, por vezes translúcidas e ceratóticas, medindo aproximadamente 2-4 mm de diâmetro, ocasionalmente umbilicadas, localizadas na margem lateral das mãos e pés, simetricamente, o que é sua expressão clínica mais típica. Os achados histopatológicos mais comuns são: hiperqueratose, acantose discreta e elastorrexe, que é observada pela coloração com orceína.

Palavras-chave: Ceratodermia palmar e plantar; Dermatoses da mão; Dermatoses do pé; Tecido elástico

REFERENCES

- Costa OG. Acrokeratoelastoidosis: a hitherto undescribed skin disease. *Dermatologica*. 1953;170:164-8.
- Costa OG. Acrokeratoelastoidosis. *AMA Arch Derm Syphilol*. 1954;70:228-231.
- Bogle MA, Hwang LY, Tschen JA. Acrokeratoelastoidosis. *J Am Acad Dermatol*. 2002;47:448-51.
- Azulay RD, Azulay DR, Azulay-Abulafia L. *Dermatologia*. 5 ed. Rio de Janeiro: Guanabara Koogan; 2008. p. 678- 713. Cap. 39 Genodermatoses de disemбриoplasias cutâneas.
- Dowd PM, Harman RRM, Black MM. Focal acral hyperkeratosis. *Br J Dermatol*. 1983;109:97-103.
- Tsai S, Kageyama N, Warthan M, Cockerell JSA. Acrokeratoelastoidosis. *Int J Dermatol*. 2005;44:406-7.
- Meziane M, Senouci K, Ouidane Y, Chraïbi R, Marcil T, Mansouri F, Hassam B. Acrokeratoelastoidosis. *Dermatol Online J*. 2008;14:11.
- Johnson BI, Yan A. Congenital diseases (genodermatoses). In: Elder DE, Elenitsas R. *Lever's histopathology of the skin*. 10 ed. Filadélfia, EUA: Lippincott; 2009.
- Zanini M. Hiperqueratose focal acral: relato de caso e discussão sobre as ceratodermias marginais. *An Bras Dermatol*. 2006; 81(5 Supl 3):293-6.
- Erbil AH, Sezer E, Koç E, Tunca M, Tastan HB, Demiriz M. Acrokeratoelastoidosis treated with the erbium:YAG laser. *Clin Exp Dermatol*. 2008;33:30-1.

MAILING ADDRESS / ENDEREÇO PARA CORRESPONDÊNCIA:

Mariana Carvalho Costa

Santa Casa da Misericórdia do Rio de Janeiro

Rua Santa Luzia, 206 - Centro

CEP: 20020-022 Rio de Janeiro, RJ, Brazil.

e-mail: maricosta133@gmail.com

How to cite this article/Como citar este artigo: Costa MC, Bornhausen-Demarch E, Hertz A, Pereira FBC, Azulay DR. What is the diagnosis? - Acrokeratoelastoidosis: a case report. *An Bras Dermatol*. 2011;86(6):1222-32.