

# An unusual presentation of macular amyloidosis \*

## Amiloidose macular de localização atípica

Bárbara Lima Araújo Melo<sup>1</sup>  
Clara de Assis Martins Goes<sup>3</sup>  
Nara Frota André<sup>4</sup>

Igor Santos Costa<sup>2</sup>  
Celina Aguiar Frota Tigre<sup>3</sup>

**Abstract:** Macular amyloidosis is a form of cutaneous amyloidosis characterized by dusky-brown lesions usually located on the upper back between the shoulder blades. This report describes the case of a 45-year-old female presenting with hyperpigmented macules and lace-like, non-pruritic erythema in the sacral and cervical region as well as on both arms and legs. Histology revealed amyloid deposits in the papillary dermis which exhibited apple-green birefringence after Congo red staining. There were no systemic findings. This is a case of macular amyloidosis with an unusual presentation. The literature on the subject is also reviewed.

**Keywords:** Amyloidosis; Congo Red; Hyperpigmentation

**Resumo:** A amiloidose macular é uma forma cutânea primária de amiloidose, caracterizada tipicamente por máculas acastanhadas, acometendo predominantemente a região interescapular. O presente caso é o de uma mulher de 45 anos, há um ano com manchas hiperocrômicas, rendilhadas e não pruriginosas, em membros superiores, região cervical, sacral e membros inferiores. No estudo histopatológico da biópsia de pele, foi evidenciada substância amiloide amorfa no topo das papilas dérmicas, que se tornou mais evidente após a coloração pelo vermelho Congo. Não havia alterações sistêmicas associadas. Além da localização atípica e extensa da amiloidose cutânea macular, o presente caso procura acrescentar dados para esclarecimento do tema.

**Palavras-chave:** Amiloidose; Hiperpigmentação; Vermelho Congo

### INTRODUCTION

Macular amyloidosis (MA) was first described in 1952 by Palitz and Peck.<sup>1</sup> Although its pathogenesis is unknown, many risk factors have been described, including ultraviolet B light, Epstein Barr virus, race, genetic predisposition and atopy. The use of nylon towels or brushes on the skin has also been described as a risk factor for the development of MA.

Onset is typically during puberty, and the condition has an equal distribution between the sexes<sup>2</sup>. It

may also be associated with progressive systemic sclerosis, systemic lupus erythematosus, pachyonychia and other systemic diseases.<sup>2</sup>

Lesions are characterized by lace-like, reddish-brown stains usually located on the upper back and, more infrequently, on the arms, chest and legs.<sup>3</sup>

Typical histological findings are an amorphous amyloid deposit in the papillary dermis between the interpapillary pegs, where foci of pigmentary inconti-

Received on 18.11.2010.

Approved by the Advisory Board and accepted for publication on 21.12.2010.

\* Study carried out at the Dona Libânia Dermatology Center, Fortaleza, CE, Brazil.

Conflict of interest: None / *Conflito de interesse: Nenhum*

Financial funding: None / *Suporte financeiro: Nenhum*

<sup>1</sup> Assistant Dermatologist, Dona Libânia Dermatology Center, Fortaleza, CE, Brazil.

<sup>2</sup> Pathologist and Dermatology Residency Preceptor, Dona Libânia Dermatology Center, Fortaleza, CE, Brazil.

<sup>3</sup> Resident Dermatologist, Dona Libânia Dermatology Center, Fortaleza, CE, Brazil.

<sup>4</sup> Medical Student, State University of Ceará (UECE), Fortaleza, CE, Brazil.

©2011 by Anais Brasileiros de Dermatologia

nence can frequently be found. When stained with Congo red and viewed under polarized light, the amyloid substance exhibits clear birefringence. Direct immunofluorescence can reveal IgG, IgM and C3 in the amyloid deposits.<sup>4</sup>

### CASE REPORT

A 45-year-old, dark-skinned housewife was followed up after presenting with a one-year complaint of dark, non-itching lesions on her arms, neck, lower back and legs. Dermatological examination revealed irregular, reddish-brown, lace-like macules on the outer face of the arms, back of the neck, sacral region and legs. The patient did not present with any systemic complaints, and there were no abnormal findings on physical examination other than those already described.

Histopathological examination of the cutaneous lesion revealed significant quantities of an amyloid deposit in the papillary dermis, which could be more clearly observed after Congo red staining, as well as foci of pigmentary incontinence. Laboratory findings were as follows: Hb: 13.8; WBC count: 4380 (52%/ 1%/ 36%); platelet count 201,000; creatinine 0.6; alkaline phosphatase 200; urea nitrogen 20; glucose levels 105; aspartate transaminase 29; alanine transaminase 43; total protein 7.2; albumin/globulin ratio 1.43; and protein electrophoresis: albumin 4.25, a-1 globulin 0.22, a-2 globulin 0.56, b-1 globulin 0.40, b-2 globulin 0.40 and g-globulin 1.37.

After systemic involvement had been excluded, topical photoprotection was started and the patient was followed up.

### DISCUSSION

Amyloidoses can be systemic or localized. The forms of greatest dermatological interest are localized primary cutaneous amyloidoses, which include macular amyloidosis, lichen amyloidosis and nodular amyloidosis.<sup>5</sup>

MA is a primary cutaneous form and is characterized by hyperpigmented macules on the upper back, particularly between the shoulder blades.<sup>3</sup> The case described here is both unusual and extensive and presents symmetrically on the arms and legs, as well as in the sacral region and back of the neck (Figures 1, 2, 3 and 4). Histopathological findings of an amyloid deposit in the dermal papillae close to the basal layer of the epidermis confirmed the diagnosis (Figure 5). There was also mild pigmentary incontinence, resulting in the hyperpigmentation observed clinically.<sup>6</sup>

Primary cutaneous amyloidosis (PCA) has an incidence that varies significantly with ethnic origin and is more common in South America and Asia than in North America and Europe. This suggests that

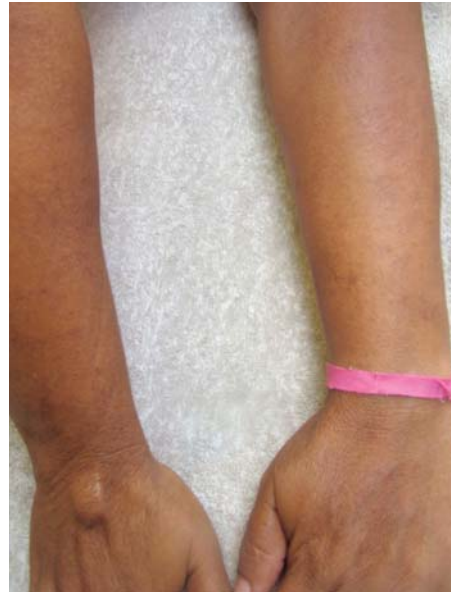

FIGURE 1: Reddish-brown, lace-like macules on the arms

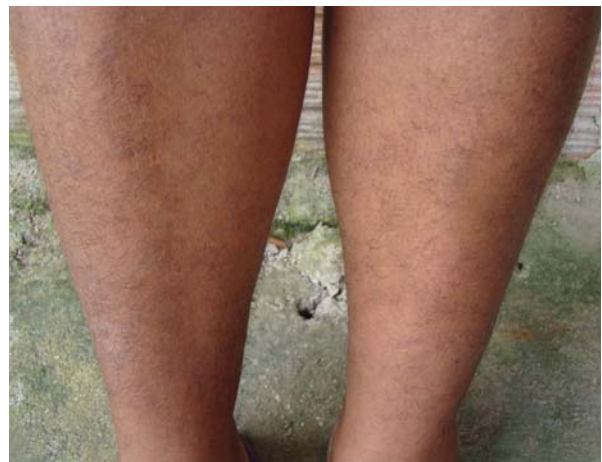

FIGURE 2: Reddish-brown, lace-like macules on the legs

genetic, environmental and even cultural factors may be implicated in PCA.<sup>7</sup> This type of amyloidosis is more frequent in females, particularly those in the 21- to 50-year age range, suggesting that hormonal factors may be involved in the etiopathogenesis of the disease.<sup>2</sup> The patient described here is South American and lies in this age range.

There is a strong association between localized cutaneous amyloidosis and *notalgia paresthetica*.<sup>8</sup> Most cases of MA in the area between the shoulder blades are attributed to this syndrome.<sup>9</sup> This patient, however, denied itching of the lesions and had macules in unusual locations, as previously described. Furthermore, itching, which is common in PCAs, may not be present in the macular form, as in this case.

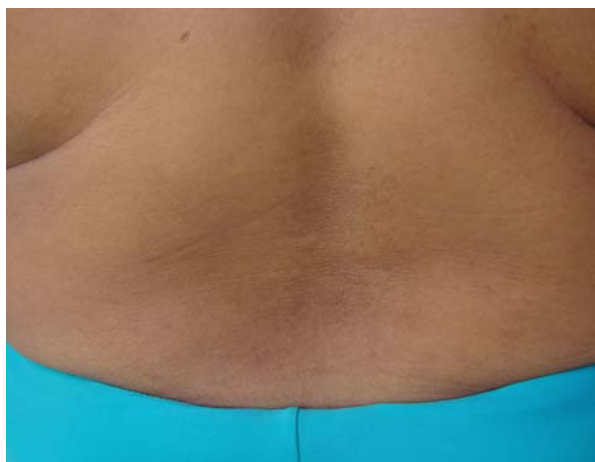

FIGURE 3: Reddish-brown, lace-like macules in the sacral region

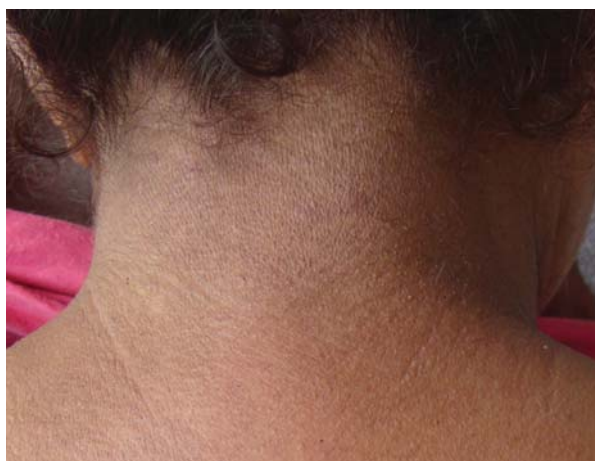

FIGURE 4: Reddish-brown, lace-like macules on the back of the neck

Occasionally, MA and lichen amyloidosis may coexist in the same patient, a condition known as biphasic amyloidosis. There are also reports of rare hypochromic and poikilodermatous forms<sup>4</sup>.

In cases of extensive or nodular cutaneous lesions it is important to carry out a systemic assessment. In the patient studied here this failed to reveal any abnormal results. This type of assessment is important as this condition has been associated with amyloidosis and multiple myeloma<sup>10</sup>.

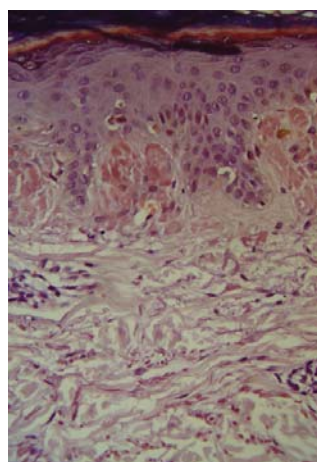


FIGURE 5: Deposits of globular eosinophilic (amyloid) material in the papillary dermis can be observed between the epidermal pegs (HE; x100)

Treatment of cutaneous amyloidoses usually yields disappointing results. Most cases can be treated with strong topical corticosteroids, normally for a short period. Calcipotriol or phototherapy are of limited use.<sup>11, 12</sup> Pigmentation has been reported to improve with topical use of dimethyl sulfoxide; however, when treatment was suspended the initial clinical picture reappeared, indicating that this is not an effective treatment for PCA.<sup>13</sup>

Encouraging results were reported with the use of Q-switched Nd:YAG laser (1064-532 nm). This produced a significant reduction in pigmentation, which is considered by MA patients to be the most disturbing aspect of the condition. No side effects were observed, and patients tolerated the pain of the laser treatment well. However, as treatment follow-up lasted only two months, possible side effects such as residual hypopigmentation were not identified, particularly in patients with phototypes V or VI, for whom six months follow-up after the multiple laser sessions would be required. Additional studies with histological examinations would also be needed.<sup>14</sup> In the case reported here, treatment consisted of photoprotection and rehydration with clinical follow-up.

This case study describes an uncommon form of MA because of the location and extent of the lesions. It also highlights the need for further studies to elucidate the etiopathogenesis of PCA with a view to finding effective treatment for this type of cutaneous amyloidosis. □

## REFERENCES

1. Palitz LL, Peck S. Amyloidosis cutis: a macular variant. *AMA Arch Dermatol Syphilol.* 1952;65 :451-7.
2. Abbas R, Alireza K, Saeid MJ. Report Macular amyloidosis: An assessment of prevalence, sex, and age. *Int J Dermatol.* 2004;43:898-99.
3. Breathnach SM. Amyloidosis of the skin. In: Freedberg IM, Eisen AZ, Wolff K, Austen KF, Goldsmith LA, Katz SI, Fitzpatrick TB, editors. *Fitzpatrick's Dermatology in General Medicine.* 5th ed. New York: Mc Graw Hill Inc; 1999. p.1760-63.
4. Kudur MH, B SP, H S, Prabhu S. Unusual presentation of generalized macular amyloidosis in a young adult. *Indian J Dermatol.* 2008;53:201-3.
5. Sampaio, SAP Rivitti, EA. *Dermatologia.* 3rd ed. São Paulo: Artes Médicas; 2007. p. 895-98.
6. Wong CK, Lin CS. Friction amyloidosis. *Int J Dermatol.* 1988;27:302-7.
7. Macsween RM, Saihan EM. Nylon cloth macular amyloidosis. *Clin Exp Dermatol.* 1997;22:28-9.
8. Peña-Penabad MC, Garcia-Silva J, Armijo M. Notalgia paresthetica and Macular amyloidosis: Cause - effect relationship? *Clin Exp Dermatol.* 1995;20:279.
9. Goulden V, Highet AS, Shamy HK. Notalgia paraesthetica--report of an association with macular amyloidosis. *Clin Exp Dermatol.* 1994;19:346-9.
10. Melo LV, Reis VMS, Criado PR, Müller H, Valente NYS. Amiloidose sistêmica associada a mieloma múltiplo: relato de caso com amiloidose cutânea exuberante.
11. Khoo BP, Tay YK, Goh CL. Calcipotriol ointment vs. betamethasone 17-valerate ointment in the treatment of lichen amyloidosis. *Int J Dermatol.* 1999;38: 539-41.
12. Jin AG, Por A, Wee LK, Kai CK, Leok GC. Comparative study of phototherapy (UVB) vs photochemotherapy (PUVA) vs topical steroids in the treatment of primary cutaneous lichen amyloidosis. *Photodermatol Photoimmunol Photomed.* 2001;17: 42-3.
13. Pandhi R, Kaur I, Kumar B. Lack of effect of dimethylsulphoxide in cutaneous amyloidosis. *J Dermatolog Treat.* 2002;13:11-4.
14. Ostovari N, Mohtasham N, Oadras MS, Malekzad F. 532-nm and 1064-nm Q-switched Nd:YAG laser therapy for reduction of pigmentation in macular amyloidosis patches. *J Eur Acad Dermatol Venereol.* 2008;22:442-6.

## MAILING ADDRESS / ENDEREÇO PARA CORRESPONDÊNCIA:

Nara Frota André

Rua Pedro I, 1.033 Centro

Fortaleza (CE) – Brazil

60035 101

E-mail: nara\_frota@yahoo.com.br

How to cite this article/Como citar este artigo: Melo BAL, Costa IS, Goes CAM, Tigre CAF, André NF. An unusual presentation of macular amyloidosis. *An Bras Dermatol.* 2011;86(4 Supl 1):S24-7.

*An Bras Dermatol.* 2011;86(4Supl1):S24-7.