

Annular elastolytic giant cell granuloma - Case report ^{*}

Granuloma anular elastolítico gigantocelular - Relato de caso

Rossana Ruth da Veiga Gonçalves¹
Fernanda de Oliveira Viana³
Diana Mendes da Fonseca³

Mario Fernando Ribeiro de Miranda²
Luíza Helena dos Santos Cavaleiro³

Abstract: Annular elastolytic giant cell granuloma is a rare granulomatous skin disease characterized histologically by phagocytosis of elastic fibers by multinucleated giant cells and clinically by annular patches with elevated borders and atrophic centers found mainly on sun-exposed skin. The pathogenesis of the disease is controversial. We report the case of a 44-year-old woman with classical clinical and histological findings of the disease whose condition improved when hydroxychloroquine was administered over a four-week period.

Keywords: Elastic tissue; Granuloma; Granuloma annulare; Histology

Resumo: O granuloma anular elastolítico gigantocelular é dermatose granulomatosa rara, caracterizada, histologicamente, por fagocitose das fibras elásticas por células gigantes multinucleadas e, clinicamente, por placas anulares com bordas elevadas e centro atrófico, com preferência por áreas expostas. A patogênese é controversa. Descreve-se um caso de mulher de 44 anos, com achados clínicos e histológicos clássicos, que apresentou boa resposta à hidroxicloroquina, após o período de 1 mês.

Palavras-chave: Granuloma; Granuloma Anular; Histologia; Tecido elástico

INTRODUCTION

Annular elastolytic giant cell granuloma (AEGG) is a rare dermatosis belonging to an interesting group of diseases that affect the elastic fibers in the skin and are clinically and/or histopathologically similar to granuloma annulare (GA) and necrobiosis lipoidica.¹ We describe the case of a 44-year-old patient with the characteristic clinical and histopathological findings of this disease.

CASE REPORT

A 44-year-old female patient from Pará presented with a one-year complaint of erythematous papules on the right arm that gradually increased in number

and size without associated symptoms. She reported having used various topical and oral medications without any improvement. Dermatological examination revealed annular plaques with papular, erythematous borders and reddish-brown atrophic centers spread over the arms and upper torso, either in isolation or in clusters with an arabesque-like appearance (Figure 1). A diagnosis of AEGG was suspected, and a biopsy of the lesion was requested. Histopathological examination revealed changes in collagen morphology and staining (collagen fibers with a fragmented, amphophilic appearance); abundant histiocytes, some of which were multinucleated; the absence of elastic

Received on 28.12.2010.

Approved by the Advisory Board and accepted for publication on 28.12.2010.

^{*} Study carried out in the Dermatology Service, Federal University of Pará (UFPA), Belém, PA, Brazil.

Conflict of interest: None / *Conflito de interesse: Nenhum*

Financial funding: None / *Suporte financeiro: Nenhum*

¹ Associate Professor, Dermatology Service, Federal University of Pará (UFPA) - Lecturer, Dermatology Residency, Federal University of Pará (UFPA) and Fundação Santa Casa de Misericórdia do Pará (FSCMPA), Belém, PA, Brazil.

² Dermatopathologist accredited by the International Committee for Dermatopathology (ICDP) and the Union Européenne des Médecins Spécialistes (UEMS). Associate Professor of Dermatology, Federal University of Pará (UFPA). Head of the Dermatopathology Laboratory in the Dermatopathology Service, ICS-UFPA, Belém, PA, Brazil.

³ Resident Dermatologist, Dermatology Service, Federal University of Pará (UFPA), Belém, PA, Brazil.

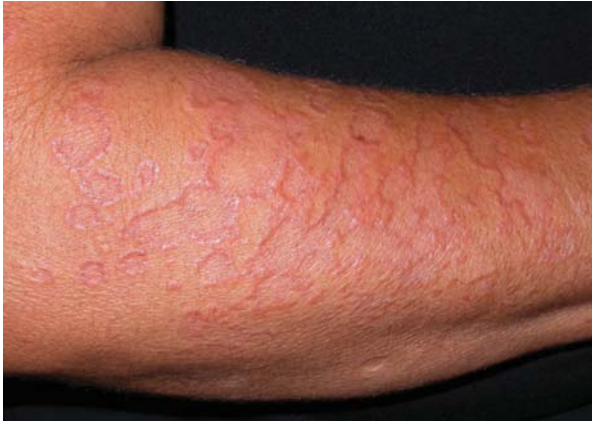

FIGURE 1: Annular plaques with an atrophic center and papular erythematous border distributed over the arms

fibers in the granuloma on Verhoeff staining; and signs of elastophagocytosis (Figures 2, 3, 4 and 5). The clinical and histological findings confirmed the hypothesis of AEGG.

DISCUSSION

The relationship between GA and AEGG is the subject of controversy. Some authors believe that AEGG is a type of GA preferentially located on sun-exposed skin, while others believe it to be an entity in its own right.^{1,2} It affects mainly middle-aged white women.³ Lesions are usually isolated or clustered in annular plaques with raised borders and atrophic centers. However, atypical forms have also been described.¹ The condition is found mainly on sun-exposed skin and is rarely described in covered areas.^{1,3} Diagnosis is based on histopathological findings of

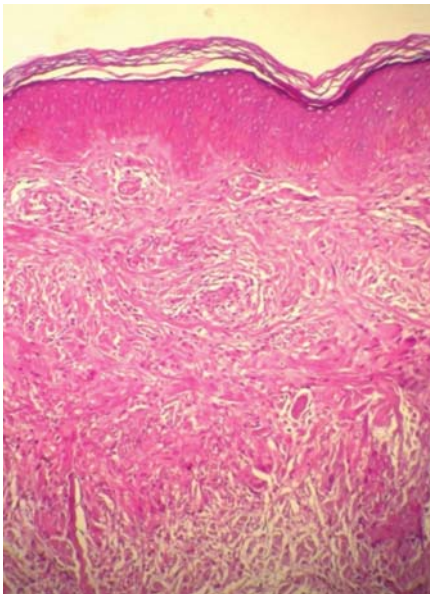


FIGURE 2: Epidermis without any significant changes. The dermis shows changes in collagen morphology and staining (collagen fibers with a fragmented, amphiphilic appearance) and abundant histiocytes, some of which are multinucleated

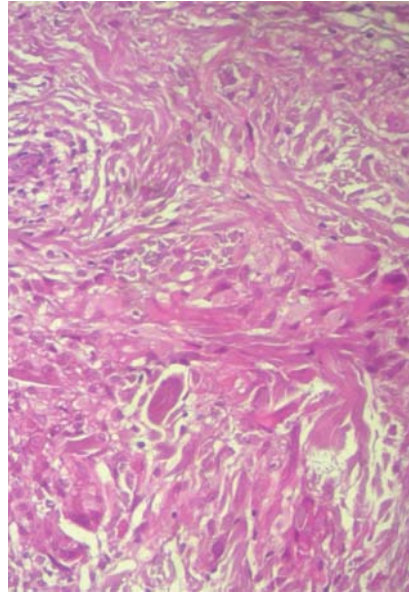


FIGURE 3: Dermal infiltrate made up of histiocytes and multinucleated giant cells

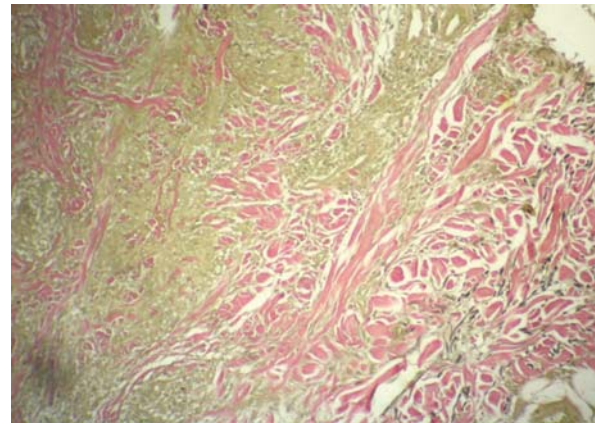


FIGURE 4: Verhoeff staining showing the absence of elastic fibers in the region of the granuloma

a granulomatous reaction with elastolysis and phagocytosis of elastic fibers by multinucleated giant cells and the absence of elastic fibers in the center of the granuloma.^{1,3,4} Elastophagocytosis is a non-specific phenomenon that can also be found in cases of generalized granuloma annulare and granulomatous slack skin. However, in AEGG there is a distinct zone of elastophagocytosis, and the quantity and distribution of giant cells differ from those observed in GA. In addition, in AEGG there is no necrobiosis of collagen or mucin deposition and elastosis is absent in some cases.¹ The pathogenesis of the condition is unknown. It has been suggested that ultraviolet radiation may cause changes in the antigenicity of elastic fibers, leading to a cellular immune response to these fibers. This theory is supported by immunohistochem-

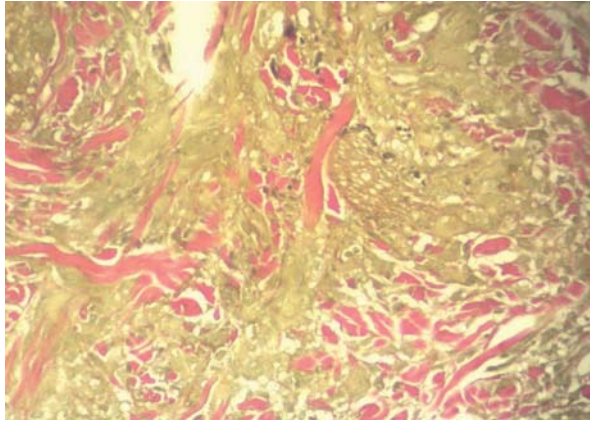


FIGURE 5: Elastophagocytosis

ical findings of an increased CD4/CD8 T-cell ratio.⁵ Therefore, the elastophagocytosis and granulomatous reaction may be a reflex of the inflammatory process, resulting in a reduction in, and subsequent complete loss of, elastic fibers.³ This pathological condition is normally confined to the skin. However, one case in which the eyes, lymph nodes and intestine were affected has been documented.⁶ The disease follows a chronic course, but there have been reports of spontaneous remission.⁷ In some cases it may be associated with diabetes mellitus.⁸ Therapy options include clofazimine, chloroquine and systemic corticosteroids.^{1,3,5,6} Notable in our case was the excellent response after one month of treatment with hydroxychloroquine in a daily dose of 400 mg. □

REFERENCES

1. Pock L, Blaková J, Caloudová H, Varjassyová R, Konkolová J, Hercogová. Annular elastolytic giant cell granuloma causes an irreversible disappearance of the elastic fibres. *J Eur Acad Dermatol Venereol.* 2004;18:365-8.
2. Ackerman AB, Chongchitnant N, Sanchez J, Guo Y, Bennin B, Reichel M, et al. Histologic diagnosis of inflammatory skin diseases. An algorithmic method based on pattern analysis. 2th ed. Baltimore: Williams & Wilkins; 1997. p. 50-3.
3. Zkaya-bayazit EO, Kbabani NY, Baykal C, Ozturk A, Okçu M, Soyer HP. Annular elastolytic giant cell granuloma: sparing of a burn scar and successful treatment with chloroquine. *Br J Dermatol.* 1999;140:525-30.
4. Ortel B, Rappersberger K, Konrad K. Middermal elastolysis in an elderly man with evidence of elastic fiber phagocytosis. *Arch Dermatol.* 1992;128:88-90.
5. Vehring KH, Bonsmann G, Brocker EB, Hamm H. Das anulare elastolytische Riesenzellgranulomeine – eine Differentialdiagnose kutaner Granulomatosen. *Hautarzt.* 1991;42:391-5.
6. Kurose N, Nakagawa H, Iozumi K, Nogita T, Furue M, Ishibashi Y. Systemic elastolytic granulomatosis with cutaneous, ocular, lymph nodal, and intestinal involvement. Spectrum of annular elastolytic giant cell granuloma and sarcoidosis. *J Am Acad Dermatol.* 1992;26:359-63.
7. Hermes B, Haas N, Czarnetzki BM. Annular elastolytic giant cell granuloma with a spontaneous healing tendency. *Hautarzt.* 1995;46:490-3.
8. Almeida Jr HL, Jannke HA, Amaral, MG. Granuloma anular elastolítico gigantocitário. *An Bras Dermatol.* 1998;73:266-8.

MAILING ADDRESS / ENDEREÇO PARA CORRESPONDÊNCIA:

Fernanda de Oliveira Viana

Rua Tibúrcio Cavalcante, 2777 - Apartamento 702

Dionísio Torres

60125-101 Fortaleza CE Brazil

E-mail: nandinbaviana@hotmail.com

How to cite this article/Como citar este artigo: Veiga Gonçalves RR, Miranda MFR, Viana FO, Cavaleiro LHS, Fonseca DM. Annular elastolytic giant cell granuloma - Case report. *An Bras Dermatol.* 2011;86(4 Supl 1):S69-71.

An Bras Dermatol. 2011;86(4Supl1):S69-71.