

Disseminated hypertrophic lichen planus: relevant response to acitretin

Líquen plano hipertrófico disseminado: relevante resposta à acitretina

Thais Jerez Jaime¹

Bianca de Mello Guaraldi¹

Thiago Jeunon⁴

Tatiana Jerez Jaime²

Daniel Fernandes Melo³

Claudio Lerer⁵

Abstract: Hypertrophic lichen planus is considered a variant of lichen planus with marked epidermal hyperplasia in response to persistent itch. It is clinically characterized by symmetric hyperkeratotic plaques, of purplish-grey color, often located in the pretibial region. Intense pruritus, refractoriness to conventional treatments and the possibility of association of the long-term injuries with squamous cell carcinoma requires an effective treatment. The first-line treatment is corticosteroids which can be applied either topically or systemically. Other therapeutic modalities proposed are: NB-UVB phototherapy or PUVA, immunosuppressive drugs and systemic retinoids, notably acitretin. We report a case with exuberant clinical presentation of hypertrophic lichen planus with excellent response to acitretin after nine months of treatment.

Keywords: Acitretin; Immunosuppressive drugs; Lichen planus; Prednisone

Resumo: O líquen plano hipertrófico é uma variante do líquen plano, com pronunciada hiperplasia epidérmica em resposta à coçadura persistente. Clinicamente, caracterizam-se por placas hiperqueratósicas, simétricas, de coloração cinza-violácea, com predileção pela região pré-tibial. O prurido intenso, a refratariedade aos tratamentos convencionais e a possibilidade de associação de um carcinoma epidermoide às lesões de longa duração impõem um tratamento eficaz. Os corticoides são considerados o tratamento de primeira linha e podem ser aplicados topicamente ou empregados de forma sistêmica. Outras modalidades terapêuticas propostas são a fototerapia com UVB-NB ou PUVA, imunossuppressores e retinoides sistêmicos, com destaque para a acitretina. Relatamos um caso com apresentação clínica exuberante e excelente resposta à acitretin, totalizando um seguimento de nove meses.

Palavras-chave: Acitretina, Imunossuppressores; Líquen plano, Prednisona

INTRODUCTION

Lichen planus (LP) is a chronic inflammatory disease of unknown etiology that affects skin, attachments and occasionally ,mucosae. Most cases occur sporadically and the few cases of family involvement seem to be related to the vertical transmission of hepatitis C or B viruses. Incidence of LP is higher in patients infected by these viruses that tend to have a more extense and resistant to treatment disease. LP

has a uniform distribution between the genders, with peak of incidence around 30 and 60 years of age. It is a frequently itchy dermatosis and it can present itself with annular, linear, bullous or atrophic lesions.¹⁻³ Hypertrophic lichen planus (HLP) represents the variety of LP in which the epidermis presents marked hyperplasia, due to persistent itching, being considered by some authors as a superposition of a chronic

Received on 17.08.2010.

Approved by the Advisory Board and accepted for publication on 28.09.2010.

* Work carried out at the Marcílio Dias Naval Hospital – Rio de Janeiro (RJ), Brazil.

Conflict of interest: None / *Conflito de interesse: Nenhum*

Financial funding: None / *Suporte financeiro: Nenhum*

¹ Third-year post graduation student from the Dermatology course at the Marcílio Dias Naval Hospital – Rio de Janeiro (RJ), Brazil.

² Preceptress at the Department of Dermatology from the University of Mogi das Cruzes (UMC) – Mogi das Cruzes (SP), Brazil.

³ Preceptor of the Department of Dermatology at the Marcílio Dias Naval Hospital – Rio de Janeiro (RJ), Brazil.

⁴ Preceptor and Head of the Department of Dermatopathology of the Dermatology service from the Federal Hospital of Bonsucesso (HFB) – Rio de Janeiro (RJ), Brazil.

⁵ Preceptor and head of the Dermatology Service at the Marcílio Dias Naval Hospital- Preceptor of the Professor Rubem David Azulay Dermatology Institute – Santa Casa da Misericórdia Hospital from Rio de Janeiro (IDPA – SCMRJ) – Rio de Janeiro (RJ), Brazil.

simple lichen to the LP lesions.⁴ It is reported here a case of HLP with excellent response to oral treatment with acitretin.

CASE REPORT

Seventy-five year-old female patient, dark skinned, coming from Rio de Janeiro that five years before had presented sudden appearance of pruritic lesions exclusively on the back of the hands. The lesions became progressively verrucous, extending to the upper and lower limbs, lumbosacral region and buttocks. The patient reported previous treatment in another service with LCD 10% and steroids, with no improvement. Dermatological examination found verrucous plaques, confluent, with irregular borders and well defined limits, with purplish grey outskirts and hypochromic center, affecting upper and lower limbs and buttock. (Figures 1,2 and 3). The initial procedure consisted of skin biopsy and laboratory tests which showed an increase in erythrocyte sedimentation rate and a cicatricial seropositivity for hepatitis A. Histopathology revealed psoriasiform hyperplasia, with hyperkeratosis, hypergranulosis, vacuolar degeneration of basal layer and blurring of the dermoepidermal junction by lymphocytic infiltrate in the papillary dermis. (Figures 4 and 5). The confirmation of the hypothesis of hypertrophic lichen planus was firm and the treatment was acitretin 40mg/day, hydroxyzine symptomatic and maintenance of topical LCD.

After 3 months of treatment it was observed partial improvement of the lesions, of the quality of life of the patient and pruritus. Today, in the ninth month of

treatment there has been total resolution of the lesions on the upper limbs and partial resolution of the lesions on the lower limbs without recurrence up to this moment. The dose was decreased to 30 mg/day in the 5th month of treatment and 25 mg/day in the 7th month and it is being kept until the present date.

DISCUSSION

HLP usually presents itself clinically as papules and symmetrical plaques, with lichenified and highly hyperkeratotic surface with coloration that varies from purple to gray having a predilection by the pretibial

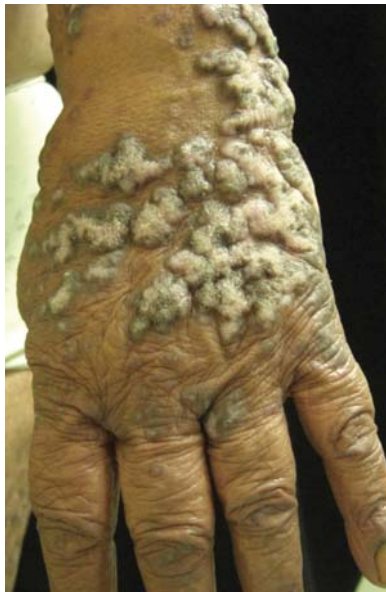

FIGURE 1: Back of the left hand showing verrucous plaques, confluent, with irregular borders and well defined limits

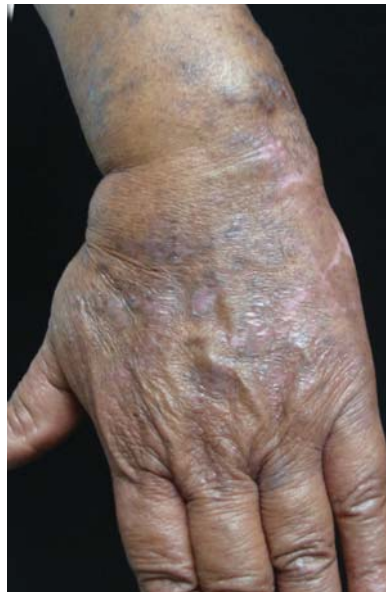

FIGURE 3: After 5 months of treatment with significant improvement of relief and dyschromia

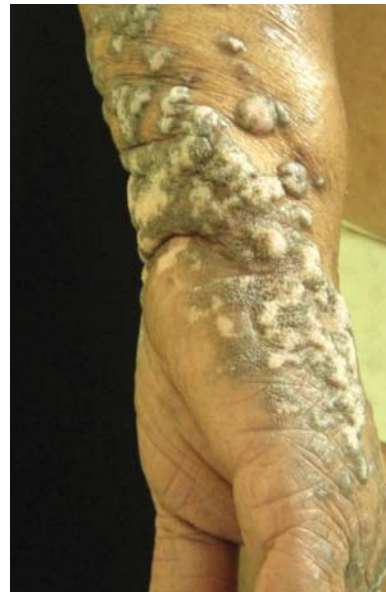

FIGURE 2: Verrucous plaques with purplish grey outskirts and hypochromic center

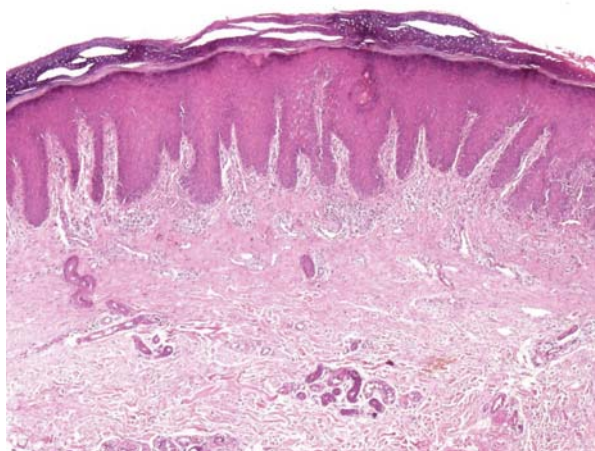


FIGURE 4: Psoriasiform hyperplasia, orthokeratotic hyperkeratosis, and hypergranulosis associated with inflammatory infiltration on the superficial dermis blurring the base of the epidermal cones. HE, enlargement of 20 x

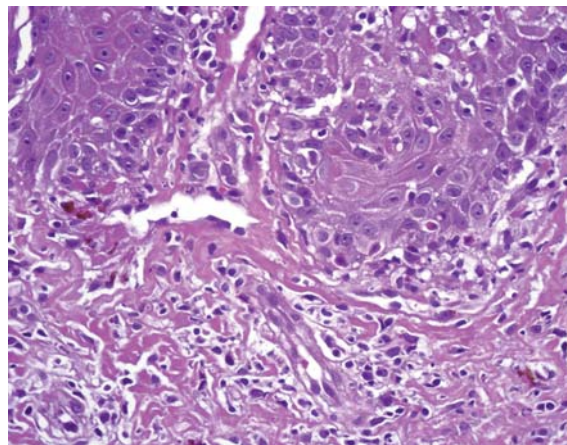


FIGURE 5: Detail of vacuolar degeneration of basal layer with keratinocytes with individual necrosis, blurring of the base of epidermal cones by lymphocytic inflammatory infiltrate in the papillary dermis and in between dermal papillae HE, enlargement of 400x

region. It is frequently associated to chronic venous insufficiency and it commonly causes residual hyperpigmentation or hypopigmentation when it evolves. There are reports of appearance of squamous cell carcinomas over HLP when they persist over time. Revision of the medical literature indicates the appearance of the disease approximately 12 years after the appearance of HLP.⁵⁻⁷

The diagnosis of HLP is morphologic, based on the clinical and histopathological aspects of the lesions. Microscopy reveals great psoriasiform hyperplasia, with bulbous epidermal cones blurred at the base by lymphocytic inflammatory infiltration, associated with keratinocytes with individual necrosis. Additionally, it is observed orthokeratotic hyperkeratosis, hypergranulosis and frequently vertical bundles of collagen in the dermal papillae denoting persistent itch.⁴ Its treatment is still unsatisfactory as it is only symptomatic. Systemical treatment of HLP is imperative when skin involvement is extensive being corticoid considered a drug of first choice.^{1,5,8-12} In refractory cases or contraindication to the same acitretin, cutaneous cyclosporine, azathioprine, mycophenolate mofetil, ciclofosfamida and

methotrexate and phototherapy are chosen.⁸⁻¹⁵

Acitretine is a half-life synthetic retinoid between 55 and 60 hours, time that can be increased in case of alcohol intake. Teratogenicity is among its most important side effects risk for which it is indicated oral contraception in childbearing women for 3 years after drug withdrawal. Hypertriglyceridemia as well as hypercholesterolemia and elevation of transaminases are also important changes caused by this medication being found that in 5 to 8% of the patients, but it is reversible with dose reduction. Mucocutaneous side effects are among the most prevalent as mucosa and skin xerosis, cheilitis and hair loss, but they are also dose dependent and reversible. Acitretine is used for different dermatological diseases having as its main effects the regulation of keratinization disorders such as psoriasis, ichthyosis, Darier's disease and palmoplantar keratoderms. More recently it was proposed to be used in very severe conditions and refractory cases of HLP and as an effective prevention of new cutaneous carcinomas, mainly the epidermoid ones, in predisposed patients as in the reported case beyond its indication for carriers of xeroderma pigmentosum and immunosuppressed ones.^{5-8,9,13,14}

It is reported here the case of an exuberant form of hypertrophic lichen planus for the extension of its dissemination besides its excellent response to the use of acitretine. □

REFERENCES

- Shiohara T, Kano Y. Lichen and Lichenoid Dermatoses. In: Bologna Jean L, Jorizzo Joseph L, editors. Dermatology. Elsevier; 2008. p.159-70.
- Welsh JP, Skvarka CB, Allen HB. A novel visual clue for the diagnosis of hypertrophic lichen planus. Arch Dermatol. 2006;142:954.
- Clarke GH. Hypertrophic lichen planus in West African Negroes. AMA Arch Derm Syphilol. 1951;64:314-9.
- Derm101.com [internet]. Histologic Diagnosis of Inflammatory Skin Diseases- An Algorithmic Based on Pattern Analysis, third edition. [cited 2010 Agu 24]. Available from: <http://www.derm101.com/resource/3>
- Fanti PA, Mattioli D, Morelli R, Varotti C. Hypertrophic lichen planus occurring after surgical procedures. Cutis. 1991;48:227-9.
- Manz B, Paasch U, Sticherling M. Squamous cell carcinoma as a complication of long-standing hypertrophic lichen planus. Int J Dermatol. 2005;44:773-4.
- Sengupta S, Das JK, Gangopadhyay A. Malignant transformation of hypertrophic lichen planus. Indian J Dermatol Venereol Leprol. 2006;72:470.
- Orfanos CE, Zouboulis CC, Almond-Roesler B, Geilen CC. Current use and future potential role of retinoids in dermatology. Drugs. 1997;53:358-88.
- Laurberg G, Geiger JM, Hjorth N, Holm P, Hou-Jensen K, Jacobsen KU, et al. In: Treatment of lichen planus with acitretin. A double-blind, placebo-controlled study in 65 patients. J Am Acad Dermatol. 1991;24:434-7.
- Kossard S, Artemi P. Acitretin for hypertrophic lichen planus-like reaction in a burn scar. Arch Dermatol. 2000;136:591-4.
- Nousari HC, Goyal S, Anhalt GJ. Successful treatment of resistant hypertrophic and bullous lichen planus with mycophenolate mofetil. Arch Dermatol. 1999;135:1420-1.
- Massa MC, Rogers RS 3rd. Griseofulvin therapy of lichen planus. Acta Derm Venereol. 1981;61:547-50.
- Bagan JV, Silvestre FJ, Mestre S, Gisbert C, Bermejo A, Agramunt J. Treatment of lichen planus with griseofulvin. Report of seven cases. Oral Surg Oral Med Oral Pathol. 1985;60:608-10.
- Berbis P. Acitretine. Ann Dermatol Venereol. 2001;128:737-45.
- Habib F, Stoeber PE, Picot E, Peyron JL, Meynadier J, Meunier L. Narrow band UVB phototherapy in the treatment of widespread lichen planus. Ann Dermatol Venereol. 2005;132:17-20

MAILING ADDRESS / ENDEREÇO PARA CORRESPONDÊNCIA:

Thais Jerez Jaime

Alameda Honduras, 270 - Alphaville 2

Alphaville

06470-130 Barueri SP, Brazil

Phones: (21) 7813- 3561/ (11) 4195-3363

E-mail: thaisjerez@yahoo.com.br

How to cite this article/Como citar este artigo: Jaime TJ, Jaime TJ, Guaraldi BM, Melo DF, Jeunon T, Lerer C. Disseminated hypertrophic lichen planus: relevant response to acitretin. An Bras Dermatol. 2011;86(4 Supl 1):S96-9.

An Bras Dermatol. 2011;86(4Supl1):S96-9.