

# Multiple cavitory pulmonary nodules in association with pyoderma gangrenosum - Case report \*

Múltiplos nódulos pulmonares cavitados em associação com pioderma gangrenoso - Relato de caso

Maraya de Jesus Semblano Bittencourt<sup>1</sup>  
Lília Sampaio Lobato<sup>3</sup>  
Helandro Stuart Castro Leandro<sup>5</sup>

Luciana Fontenele Brito Soares<sup>2</sup>  
Alexandre Dias Mançano<sup>4</sup>  
Diana Mendes da Fonseca<sup>6</sup>

**Abstract:** Pyoderma gangrenosum is a rare neutrophilic disease of unknown origin that is associated with systemic diseases in 50% of cases. It is characterized by erythematous-violaceous nodular lesions that quickly progress to painful ulcers, with undermined edges, necrotic-hemorrhagic, varying in size and depth, located mainly in the lower limbs. Extracutaneous locations of pyoderma gangrenosum are rare, usually involving the lungs; the main differential diagnosis in these cases is Wegener granulomatosis. We report a case of pyoderma gangrenosum, which showed multiple cavitory lung nodules, with good response to high doses of steroids. Once excluded the possibility of Wegener granulomatosis, the authors concluded that it was the manifestation of systemic pyoderma gangrenosum with pulmonary involvement.

**Keywords:** Cavitation; Multiple pulmonary nodules; Pyoderma gangrenosum; Wegener granulomatosis

**Resumo:** Pioderma gangrenoso é doença neutrofílica rara de etiologia desconhecida, que se associa a doenças sistêmicas em 50% dos casos. Caracteriza-se clinicamente por lesão nodular eritematoviolácea ou pústula que progride rapidamente para úlcera dolorosa, de bordas irregulares, fundo necrohemorrágico e localização preferencial nos membros inferiores. Manifestações sistêmicas do Pioderma gangrenoso são raras, envolvem geralmente os pulmões e o principal diagnóstico diferencial nestes casos é a granulomatose de Wegener. Relatamos um caso de paciente portador de pioderma gangrenoso que apresentava múltiplos nódulos pulmonares cavitados, com boa resposta a altas doses de corticoterapia. Uma vez excluída a possibilidade de granulomatose de Wegener, os autores concluíram tratar-se da manifestação sistêmica do pioderma gangrenoso.

**Palavras-chave:** Cavitação; Granulomatose de Wegener; Nódulos pulmonares múltiplos; Pioderma gangrenoso

Received on 06.03.2011.

Approved by the Advisory Board and accepted for publication on 15.05.2011.

\* Work carried out at the Fundação Santa Casa de Misericórdia do Pará (FSCMPA) – Belém (PA), Brazil.

Conflict of interest: None / *Conflito de interesse: Nenhum*

Financial funding: None / *Suporte financeiro: Nenhum*

<sup>1</sup> Master's degree in tropical diseases – Physician at the Fundação Santa Casa de Misericórdia do Pará (FSCMPA) – Belém (PA), Brazil

<sup>2</sup> Specialist in Radiology and Diagnostic Imaging by the Brazilian College of Radiology and Diagnostic Imaging - Physician Radiologist at Hospital Anchieta - Brasília (DF), Brazil.

<sup>3</sup> Specialist in Radiology and Diagnostic Imaging by the Brazilian College of Radiology and Diagnostic Imaging - Physician Radiologist at the Fundação Santa Casa de Misericórdia do Pará (FSCMPA) – Belém (PA), Brazil

<sup>4</sup> Specialist in Radiology and Diagnostic Imaging by the Brazilian College of Radiology and Diagnostic Imaging - Physician Radiologist at Hospital Anchieta - Brasília (DF), Brazil

<sup>5</sup> Specialist in Internal Medicine – Resident physician of the Nephrology Service of the Teaching Hospital de Clínicas Gaspar Vianna (FHCGV) – Belém (PA), Brazil

<sup>6</sup> Resident physician of the Dermatology Service of the Universidade Federal do Pará (UFPA) – Belém (PA), Brazil.

**INTRODUCTION**

Pyoderma gangrenosum (PG) is a chronic, ulcerative, destructive, neutrophilic disease of unknown etiology that in about 50% of cases is associated with systemic illnesses such as inflammatory bowel disease, rheumatoid arthritis, monoclonal gammopathy, immunological dysfunction, hematological disorders and malignancy.<sup>1-4</sup> Systemic involvement is rare in PG and the lungs are the most affected organs.<sup>5-9</sup> The main differential diagnosis in these cases is Wegener granulomatosis (WG).

**CASE REPORT**

A 17-year-old male patient had presented ulceronodular lesions in the inguinal region for 6 years and received several previous treatments, without improvement. One month before cutaneous lesions worsened, he had dyspnea, cough with hemoptysis, chest pain and febrile episodes. The dermatological exam revealed ulcers with discretely elevated erythematous-violaceous borders, necrotic and hemorrhagic base bilaterally in the inguinal region. There were no palpable lymph nodes (Figure 1). The histopathological exam of the cutaneous lesion showed spongiotic foci, lymphocyte and eosinophil exocytosis in the epidermis and, in the dermis, vascular proliferation and dense mixed inflammatory infiltrate composed of frequent neutrophils and eosinophils around vessels, annexes and dermal interstices (Figure 2). Atypias and parasites absent in exam with H&E. The correlation of cutaneous and histopathological findings was compatible with PG. The computerized tomography of the thorax revealed the presence of multiple pulmonary nodules, some of them with central cavitation, without mediastinal lymph node enlargement or pleural effusion (Figures 3, 4 and 5). Myelogram: reactive hypercellularity. Colonoscopy: non specific, mild

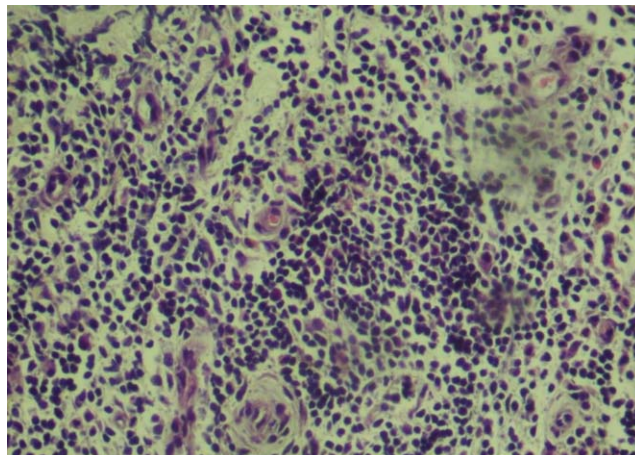


FIGURE 2: Histopathological exam: vascular proliferation and dense lymphocyte infiltrate associated with frequent neutrophils and eosinophils around vessels, annexes and occupying interstices of the dermal connective tissue

chronic colitis. The pulmonary biopsy was not carried out due to lack of operational conditions. Tomography of facial sinuses, bronchoalveolar lavage, bronchoscopy, AARB search in sputum examination, CA 19-9, CEA, alpha-fetoprotein, VDRL, Antinuclear antibodies (ANA) or antinuclear factor (ANF) profile, antiDNA, complements C3, C4 and CH50, anti SM, anti RNP, antiRo, cANCA and pANCA, hemocultures, urea, creatinine and EAS without alterations. After two weeks of corticotherapy at full dose the patient obtained expressive improvement of the symptom complex and thorax control tomography showed evidence that the cavitary lung nodules has disappeared (Figure 6). Since there was no involvement of the upper respiratory tract or kidney alteration, cANCA and pANCA were negative and fast response to corticotherapy, WG hypothesis was excluded and the diagnosis of PG pulmonary manifestation confirmed.

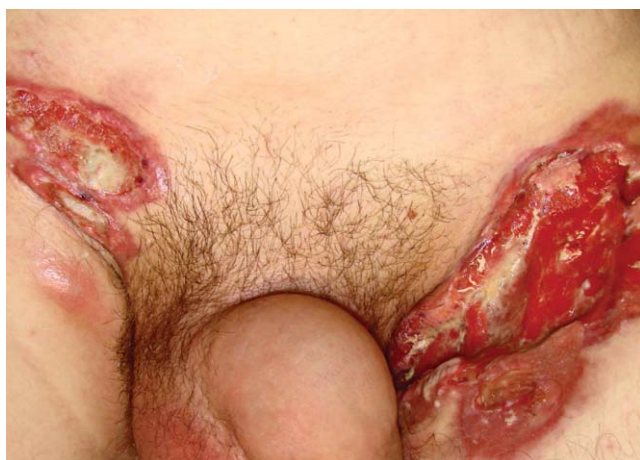

FIGURE 1: Ulcerated lesions with erythematous borders, necrotic and hemorrhagic base, satellite pustules located in the inguinal regions D and E

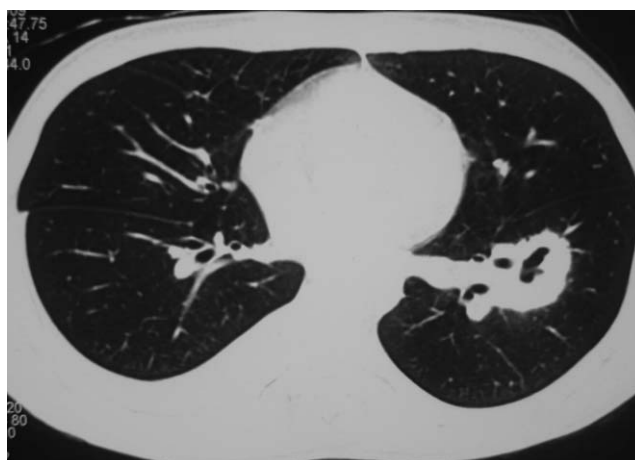


FIGURE 3: Tomographic cut of thorax showing cavitary pulmonary nodular lesions

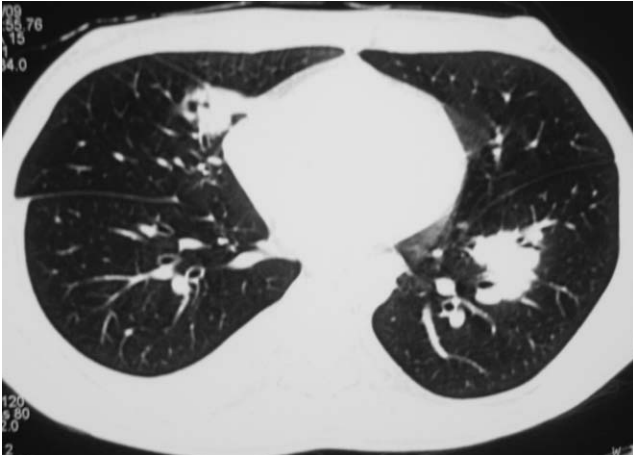


FIGURE 4: Tomographic cut of thorax showing cavitory pulmonary nodular lesions

## DISCUSSION

Pyoderma gangrenosum (PG), first described by Brunsting and O'Larry in 1930, is a rare neutrophilic, ulcerative, painful and non infectious dermatosis, described as having a strong association with ulcerative colitis of unknown pathogenesis.<sup>1,2,3</sup> It is clinically characterized by erythematous-violaceous nodular lesion or pustule that progresses quickly to painful single or multiple ulcer, with irregular and loose borders, necrotic and hemorrhagic base, preferentially located on lower limbs.<sup>2,4</sup> It may be classified into four types, based on clinical and histopathological characteristics: classical (ulcerative), pustular, bullous and vegetative.<sup>1,3</sup> Skin biopsy is essential for diagnosis confirmation.<sup>4</sup> The differential diagnosis includes systemic vasculitis, infection, ischemic ulceration and primary T-cell lymphoma. The aggressive nature of ulcers, negative cultures for bacteria and fungi as well as compatible histopathology assist in the diagnosis.<sup>8</sup>

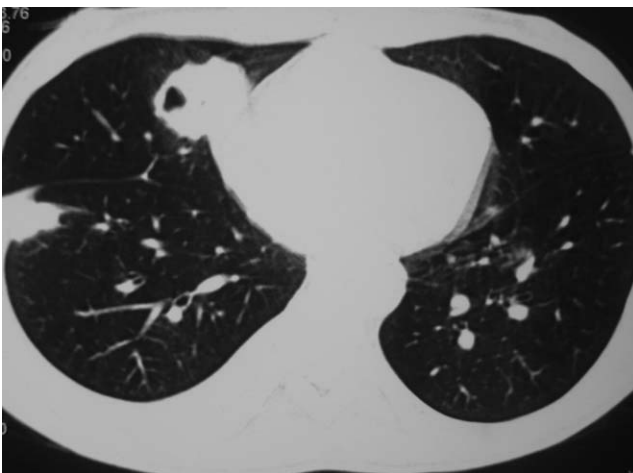


FIGURE 5: Tomographic cut of thorax showing cavitory pulmonary nodular lesions

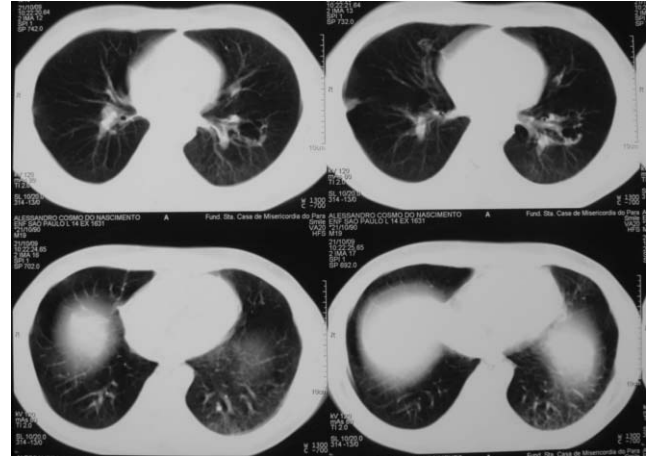


FIGURE 6: Tomographic cut of thorax, mediastinal window, showing resolution of cavitory pulmonary nodular lesions

The clinical progression usually has a chronic course, with frequent recurrences. Until now, PG treatment is considered controversial and there are no established protocols. Treatment options are: broad spectrum antibiotics, corticosteroids, immunosuppressors and immunomodulators. Prednisone in high doses (1mg/kg/day) is the most effective agent for control of the systemic manifestations of PG, especially the pulmonary form.<sup>6,9,10</sup> The pulmonary manifestation of PG may present as solitary unilateral opacity, interstitial pneumonitis, pleural effusion and multiple pulmonary nodules, the most frequent form.<sup>6,11-15</sup> The main differential diagnosis in such cases is WG, which makes the computed tomography-guided lung biopsy necessary.<sup>6,8,9</sup> PG and WG, in a limited form, present similarities in the clinical and histopathological presentations.<sup>3-5</sup> In lung PG, however, the inflammatory lesions are aseptic, without necrotizing granulomatous inflammation or vasculitis.<sup>8,10</sup> In addition, the c-Anca is highly specific for WG, present in 80-90% of the patients with classical WG and in 55-66% if those with limited WG. We report a rare case of PG with cutaneous and systemic manifestation of cavitory pulmonary nodules. Only eleven similar cases have been published in the international literature.<sup>9</sup> It is of fundamental importance to know this clinical association, so little known by dermatologists and radiologists, for more success in the diagnosis, treatment and follow-up of these patients. □

## REFERENCES

1. Powell FC, Schroeter AL, Su WPD. Pyoderma gangrenosum: a review of 86 patients. *Q J Med.* 1985;55:173-86.
2. Brunsting LA, Goeckerman WH, O'Leary PA. Pyoderma (echthyma) gangrenosum: clinical and experimental observations in five cases occurring in adults. *Arch Dermatol Syph.* 1930;22:655-80.
3. Berbert ALCV, Mantese SAO, Rocha A, Rezende J, Cunha TFR. Pioderma granulomatoso superficial: relato de caso de variante rara do pioderma gangrenoso. *An Bras Dermatol.* 2009;84:285-8.
4. Barbato MT, Bakos L, Masiero NCMS, Bolson P. Perfil clinicopatológico dos pacientes com pioderma gangrenoso do Hospital de Clínicas de Porto Alegre (2000-2006). *An Bras Dermatol.* 2008;83:431-6.
5. Wong YW, Lyon CC, Benbow EW, Bradley BL, Beck MH. Pyoderma gangrenosum in a thoracotomy wound associated with a pulmonary cavitating lesion. *Clin Exp Dermatol* 2003; 28:274-6.
6. Krüger S, Piroth W, Amo Takyi B, Breuer C, Schwarz ER. Multiple aseptic pulmonary nodules with central necrosis in association with pyoderma gangrenosum. *Chest.* 2001;119:977-8.
7. Kasuga I, Yanagisawa N, Takeo C, Koga M, Kiyokawa H, Yonemaru M, et al. Multiple pulmonary nodules in association with pyoderma gangrenosum. *Resp Med.* 1997;91:493-5.
8. Field S, Powell FC, Young V, Barnes L. Pyoderma gangrenosum manifesting as a cavitating lung lesion. *Clin Exp Dermatol.* 2008;33:418-23.
9. Batalla A, Pérez-Pedrosa A, García-Doval I, González-Barcala FJ, Rosón E, de la Torre C. [Lung involvement in pyoderma gangrenosum: a case report and review of the literature]. *Actas Dermosifiliogr.* 2011;102:373-7.
10. Liu ZH, Lu XL, Fu MH, Zhang GY, Liu WD. Pyoderma gangrenosum with pulmonary involvement? *Eur J Dermatol.* 2008;18:583-5.
11. Lebbe C, MoulonquetMichau I, Perrin P, Blanc F, Frija J, Civatte J. Steroid responsive pyoderma gangrenosum with vulvar and pulmonary involvement. *J Am Acad Dermatol* 1992;27:623-5.
12. McCulloch AJ, McEvoy A, Jackson JD, Jarvis EH. Severe steroid responsive pneumonia associated with pyoderma gangrenosum and ulcerative colitis. *Thorax.* 1985;40:314-5.
13. Vignon-Pennamen MD, Zelinsky-Gurung A, Janssen F, Frija J, Wallach D. Pyoderma gangrenosum with pulmonary involvement. *Arch Dermatol.* 1989;125:1239-42.
14. Brown TS, Marshall GS, Callen JP. Cavitating pulmonary infiltrate in an adolescent with pyoderma gangrenosum: a rarely recognized extracutaneous manifestation of a neutrophilic dermatosis. *J Am Acad Dermatol.* 2000;43:108-12.
15. Wang JL, Wang JB, Zhu YJ. Pyoderma gangrenosum with lung injury. *Thorax.* 1999;54:953-5.

---

*MAILING ADDRESS:*

*Maraya de Jesus Semblano Bittencourt  
Travessa Timbó, 1890, Aptº 905 - Marco  
CEP: 66085-654 - Belém, PA - Brazil  
E-mail: marayabittencourt@botmail.com*

How to cite this article: Bittencourt MJS, Soares LFB, Lobato LS, Mançano AD, Leandro HSC, Fonseca DM. Multiple cavitary pulmonary nodules in association with pyoderma gangrenosum: case report. *An Bras Dermatol.* 2012;87(2):301-4.