

Do you know this syndrome? *

Você conhece esta síndrome?

Aristóteles Rosmaninho ¹
Iolanda Conde Fernandes ³
Manuela Selores ⁵

Teresa Pinto-Almeida ²
Susana Machado ⁴

CASE REPORT

A 65 year-old man presented for evaluation of multiple widespread nodules in his body. The lesions were long standing and began during his childhood. More lesions appeared over time. On physical examination multiple, subcutaneous, soft, mobile and non painful nodules and tumors were observed in the arms, legs and abdomen distorting the affected areas (Figures 1, 2 and 3). His past medical history was remarkable for diabetes mellitus and hepatocarcinoma secondary to chronic HBV infection. He denied alcohol consumption. Similar but less extensive

lesions were observed in his two brothers and father. Some lesions were surgically excised because they caused functional discomfort. The histopathological examination showed the presence of globules of mature white adipose tissue surrounded by thin fibrous capsules. The analytical study showed no significant abnormalities including lipid abnormalities. Based on the characteristic clinical history, family history and histopathology the diagnosis of familial multiple lipomatosis (FML) was made.

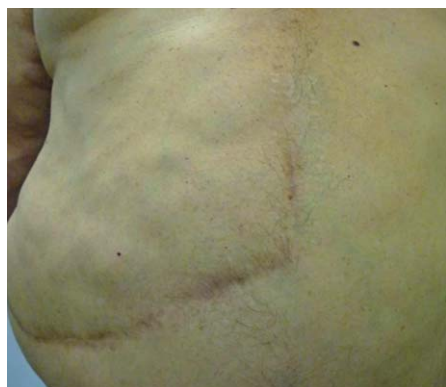

FIGURE 1: Multiple subcutaneous lesions in the abdomen

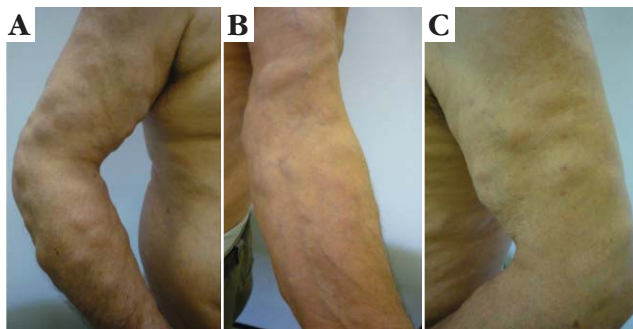


FIGURE 2: Multiple subcutaneous lesions in the arms

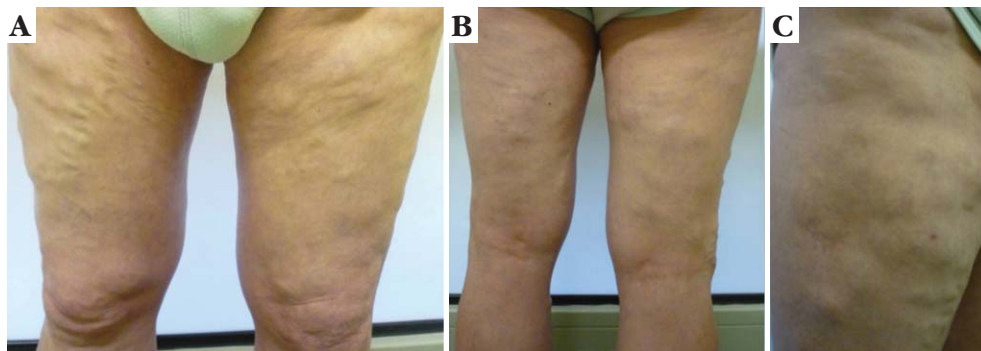


FIGURE 3: Subcutaneous lesions in the legs

Received on 03.08.2011.

Approved by the Advisory Board and accepted for publication on 22.11.2011.

* Work carried out at the Centro Hospitalar do Porto-Hospital de Santo António (EPE-HSA) - Porto, Portugal.

Conflict of interest: None / *Conflito de interesse: Nenhum*

Financial funding: None / *Suporte financeiro: Nenhum*

¹ Intern in Dermatovenereology - Centro Hospitalar do Porto-Hospital de Santo António (EPE-HSA) - Porto, Portugal.

² Physician - Intern in Dermatovenereology - Centro Hospitalar do Porto-Hospital de Santo António (EPE-HSA) - Porto, Portugal.

³ Physician - Intern in Dermatovenereology - Centro Hospitalar do Porto-Hospital de Santo António (EPE-HSA) - Porto, Portugal.

⁴ Physician - Hospital Assistant in Dermatovenereology - Centro Hospitalar do Porto-Hospital de Santo António (EPE-HSA) - Porto, Portugal.

⁵ Physician - Director of the Dermatovenereology Service - Centro Hospitalar do Porto-Hospital de Santo António (EPE-HSA) - Porto, Portugal.

DISCUSSION

Lipomas are among the most common tumors seen in the soft body parts and usually are solitary lesions.¹ Multiple lipomas found on the trunk and extremities with relative sparing of the head and shoulders that appear mostly in the third decade of life and affect several members of a family are highly suggestive of FML.^{2,3} However, they can occur at an earlier age and have a more diffuse distribution. FML is a rare benign hereditary syndrome and an incidence of 0.002% has been reported. The lipomas associated with FML are usually painless and patients are not troubled by the disease. FML is usually transmitted in an autosomal dominant fashion and the high level of prevalence among first degree family members confirms this hypothesis.^{4,5} However, cases with a recessive inheritance have also been reported. A translocation involving the high-mobility-group protein isoform I-C on chromosome 12 and the lipoma preferred partner gene on chromosome 3 is implicated in the disease genesis.⁴ Men are affected twice more commonly as women.² It is important to distinguish FML from other causes associated with subcutaneous lipomas such as Madelung's disease, Dercum's disease, Bannayan-Zonana syndrome and Cowden syndrome.

Madelung's disease is characterized by symmetrical unencapsulated fat deposition located mainly in the neck and shoulder regions and in 90% of the cases it is associated with alcoholism.⁶ Other associated metabolic disorders include: hyperlipidaemia, hyperthyroidism, hypothyroidism, hypogonadism and diabetes mellitus. It has also been described after liver transplant.^{7,8} The lipomas in Dercum's disease are painful and the disease affects mainly post-menopausal women. Asthenia and mental disturbances are possible associated symptoms.⁹ In Bannayan-Zonana syndrome the accumulation of fatty tissue is associated with development delay, hypotonia and lipid myopathy that are recognized during the first few years of life. Intestinal polyposis and vascular malformations are also common findings. In Cowden syndrome other skin tumors are present, mainly facial trichilemmomas, papillomatous papules and fibromas. A mutation in PTEN gene is usually present. The main treatment consists of surgical excision of the lesions responsible for cosmetic and functional impairment. Other possible treatment techniques include liposuction and injection lipolysis with phosphatidyl choline. □

Abstract: Lipomas are among the most common tumors seen in the soft body parts and usually are solitary lesions. The authors report a case of a male patient that presented for evaluation of multiple subcutaneous nodules that caused important functional and cosmetic impairment. The diagnosis of familial multiple lipomatosis was made. Physicians should be able to recognize and characterize this rare disease.

Keywords : Lipoma; Lipomatosis; Subcutaneous fat

Resumo: Os lipomas estão entre os tumores mais frequentemente observados nas partes moles do corpo, sendo geralmente lesões solitárias. Os autores relatam o caso de um paciente do sexo masculino que se apresentou para a avaliação de múltiplos nódulos subcutâneos que causavam um importante prejuízo funcional e estético. O diagnóstico final foi de lipomatose múltipla familiar. Os médicos devem ser capazes de reconhecer e caracterizar esta doença rara.

Palavras-chave: Gordura subcutânea; Lipoma; Lipomatose

REFERENCES

- Ronan S, Broderick T. Minimally invasive approach to familial lipomatosis. *Plast Reconstr Surg.* 2000;106:878.
- Lefell D, Braverman I. Familial multiple lipomatosis. *J Am Acad Dermatol.* 1986;15:275.
- Rubinstein A, Goor Y, Gazit E, Gabili S. Non-symmetric subcutaneous lipomatosis associated with familial combined hyperlipidaemia. *Br J Dermatol.* 1989;120:689.
- Schoenmakers EF, Wanschura S, Mols R, Bullerdiek J, Van den Berghe H, Van de Ven WJ. Recurrent rearrangements in the high mobility group protein gene, HMGI-C, in benign mesenchymal tumours. *Nature Genet.* 1995;10:436.
- Keskin D, Ezirmik N, Celik H. Familial multiple lipomatosis. *Isr Med Assoc J.* 2002;4:1121-3.
- Gon AS, Minelli L, Mendes MF. Benign symmetric lipomatosis. *An Bras Dermatol.* 2005;80:545-6.
- Goetze S, Hommann M, Eisner P, Kaatz M. Induction of benign symmetric lipomatosis (Launois-Bensaude Syndrome) in a female patient after liver transplantation. *Dermatology.* 2008;216:337-340.
- Lee SY, Jeon CW, Lee SJ. Benign symmetrical lipomatosis (Madelung's Disease). *J Am Coll Surg.* 2009;208:164.
- Brodovsky S, Westreich M, Leibowitz A, Schwartz Y. Adiposis dolorosa (Dercum's disease): 10-year follow-up. *Ann Plast Surg.* 1994;33:664-8.

MAILING ADDRESS:

Aristóteles Rosmaninho

Rua D. Manuel II, s/nº, Edifício das Consultas Externas, 4099-001 - Porto, Portugal.

E-mail: arisrosmaninho@gmail.com

How to cite this article: Rosmaninho A, Pinto-Almeida T, Fernandes IC, Machado S, Selores M. Do you know this syndrome? Familial multiple lipomatosis. *An Bras Dermatol.* 2012;87(2):324-5.