

Treatment of Toxic Epidermal Necrolysis with Intravenous Immunoglobulin: a series of three cases *

Tratamento da necrólise epidérmica tóxica com imunoglobulina endovenosa: uma série de três casos

Cristiane Comparin¹

Luiz Carlos Takita³

Roberta Ayres Ferreira do Nascimento⁵

Günter Hans Filho²

Nayara de Castro Wiziack Costa⁴

Lidiane de Oliveira Costa Nanni⁶

Abstract: Stevens-Johnson's syndrome (SJS) and toxic epidermal necrolysis (TEN) are life-threatening dermatoses, that lead to keratinocyte apoptosis induced by interactions between Fas (cell death receptor) and soluble Fas-ligand, present in serum of Stevens-Johnson's syndrome / toxic epidermal necrolysis patients. Anti-Fas antibodies in intravenous immunoglobulin (IVIg) would block the apoptosis cascade. Three cases of toxic epidermal necrolysis occurred in one male and two female patients, after use of allopurinol, leprosy multidrug therapy concomitant with dipyrone, and diclofenac. The cases were treated with intravenous immunoglobulin 2-3 mg/kg and prednisone 20-50 mg/day. The interruption of new lesions outbreak and reepithelization were extremely fast after the use of intravenous immunoglobulin, without adverse effects. Controlled studies are needed to confirm the efficacy of intravenous immunoglobulin in Stevens-Johnson's syndrome / toxic epidermal necrolysis, but the results seem promising.

Keywords: Drug toxicity; Epidermal necrolysis, toxic; Fas ligand protein; Immunoglobulins, intravenous

Resumo: A Síndrome de Stevens-Johnson e a Necrólise Epidérmica Tóxica são dermatoses graves, que levam à apoptose dos queratinócitos induzida pela interação entre Fas (receptor de morte celular) e Fas-ligante solúvel, presente no soro de pacientes com Síndrome de Stevens-Johnson e Necrólise Epidérmica Tóxica. Anticorpos anti-Fas contidos na imunoglobulina endovenosa podem bloquear esta cascata apoptótica. Três casos de Necrólise Epidérmica Tóxica são descritos, ocorrendo após uso de alopurinol, diclofenaco e poliquimioterapia para hanseníase concomitante com dipirona. Os três casos foram tratados com imunoglobulina endovenosa 2-3 mg/kg, divididos em 4 ou 5 dias e prednisona 20-50 mg/dia. A interrupção no surgimento de novas lesões e a reepitelização foram extremamente rápidas, sem ocorrência de efeitos adversos. Estudos controlados são necessários para confirmar a eficácia da imunoglobulina endovenosa na Síndrome de Stevens-Johnson e Necrólise Epidérmica Tóxica, porém, seus resultados parecem ser promissores.

Palavras-chave: Erupção por droga; Imunoglobulinas intravenosas; Necrólise epidérmica tóxica; Proteína ligante Fas

Received on 04.06.2011.

Approved by the Advisory Board and accepted for publication on 15.08.2011.

* Study carried out at the Department of Dermatology, Teaching Hospital, Federal University of Mato Grosso do Sul (Universidade Federal do Mato Grosso do Sul - UFMS) – Campo Grande (MS), Brazil.

Conflict of interest: None

Financial funding: None

¹ MD - Dermatologist, Residency Preceptor of Dermatology of the Department of Dermatology, Teaching Hospital, Federal University of Mato Grosso do Sul (Universidade Federal do Mato Grosso do Sul - UFMS) – Campo Grande (MS), Brazil.

² PhD - Adjunct Professor of Dermatology, Head of the Medical Residency Program in Dermatology and of the Department of Dermatology, Federal University of Mato Grosso do Sul (Universidade Federal do Mato Grosso do Sul - UFMS) – Campo Grande (MS), Brazil.

³ MSc - Pathologist, Professor of Special Anatomic Pathology and Medical Residency Program in Dermatology, Federal University of Mato Grosso do Sul (Universidade Federal do Mato Grosso do Sul - UFMS) – Campo Grande (MS), Brazil.

⁴ MD - Dermatologist, Assistant Professor of Dermatology, Federal University of Mato Grosso do Sul (Universidade Federal do Mato Grosso do Sul - UFMS) – Campo Grande (MS), Brazil.

⁵ MD - Dermatologist – Private clinic – São José do Rio Preto (SP), Brazil.

⁶ MD - Dermatologist – Private clinic – Bauru (SP), Brazil.

INTRODUCTION

Stevens-Johnson syndrome (SJS) and Toxic Epidermal Necrolysis (TEN) are rare life-threatening dermatoses. SJS is defined when there is <10% denuded cutaneous surface; overlapping SJS-TEN when detachment involves 10-29%, and over 30%, is considered TEN. Drugs presently used, usually antibiotics, dipyrone, allopurinol, non-steroidal anti-inflammatory and anti-seizure agents, are the cause of most cases.¹ The severity-of-illness score (SCORTEN) was validated by mortality prediction in TEN.²

Experiments have demonstrated that interactions between Fas (CD95, cell death receptor) and soluble-Fas-ligand (sFas-Ligand) induced keratinocyte-apoptosis in SJS/TEN. Keratinocytes experimentally exposed *in vitro* to soluble Fas-ligand-containing serum from TEN/SJJ-patients, entered into dose-dependent apoptosis, proving causality. Keratinocytes cultured in the presence of anti-Fas-ligand antibodies also showed dose-dependent reduction in apoptotic cells. Results were reproduced by exposing keratinocytes to isolated-soluble Fas-ligand, corroborating its crucial trigger-function in their apoptosis.

These data strongly support the hypothesis that serum from TEN-patients mediates keratinocyte apoptosis, through interaction between Fas and sFas-Ligand.³

INTRAVENOUS IMMUNOGLOBULIN

Intravenous immunoglobulin (IVIG) is plasma-

derivative from pooled plasma of many blood donors with high immunoglobulin G concentration against foreign antigens and auto-antigens, including anti-Fas-antibodies, which bonded to Fas preventing its interaction with sFas-Ligand, blocking apoptosis (Figure 1).⁴⁻⁶ IVIG treatment: 3-4 g/kg divided into 3 consecutive days, administered in the first 7 days, has shown great possibility of success.

Despite lack of randomized controlled studies, available data supports IVIG use to treat cases of TEN, demonstrated by 3 cases that presented exceptional response.

CASE REPORTS

Case 1

A 55-year-old female patient developed lesions fifteen days after taking allopurinol. Admitted on day 3, she presented vesicobullous lesions, large areas of denuded skin and oral mucosa. Table 1 shows clinical parameters. Histopathology confirmed TEN. Prednisone 0.5 mg/kg/day treatment was prescribed. Seven days later she suffered acute myocardial infarction. As cutaneous detachment persisted, a total dose of 2g/kg IVIG was prescribed on day ten after admission. Three days later, her general clinical and dermatological condition improved significantly, with progressive reepithelization and complete recovery (Figures 2 and 3).

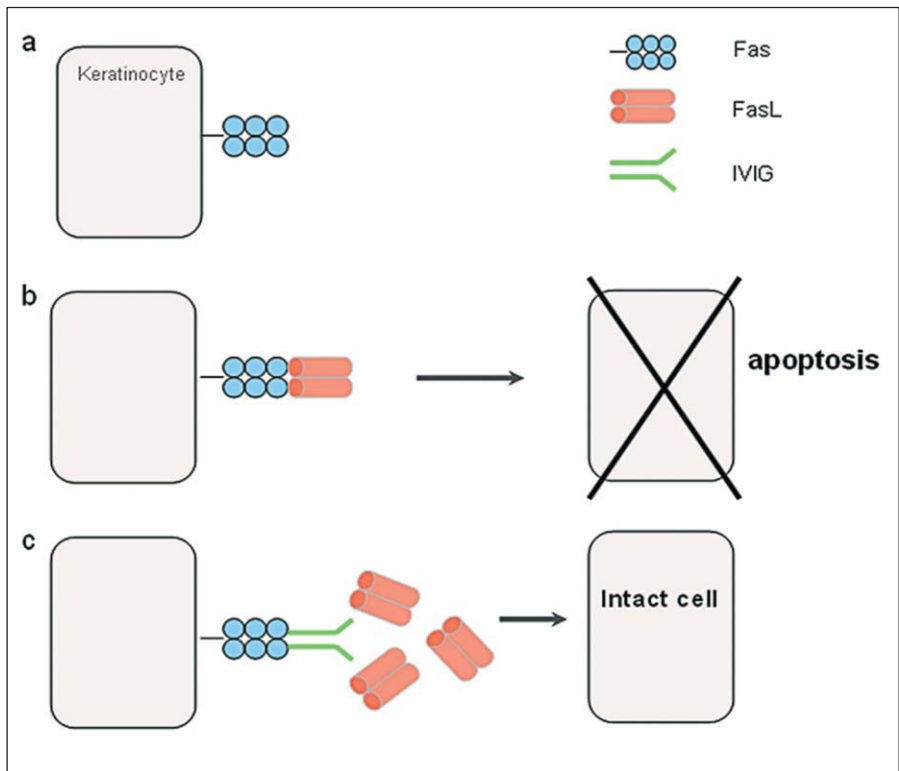


FIGURE 1: Mechanisms of IVIG action: apoptosis mediated by Fas-FasL in keratinocytes of TEN patients. A. normal epidermis. B. TEN induced expression of Fas on the cell surface and interact with FasL, leading to apoptosis. C. TEN epidermis treated with IVIG: inhibition of apoptosis by blocking of Fas due to anti-Fas antibodies in IVIG

Adapted source: Molgó M, et al. 2009.⁶

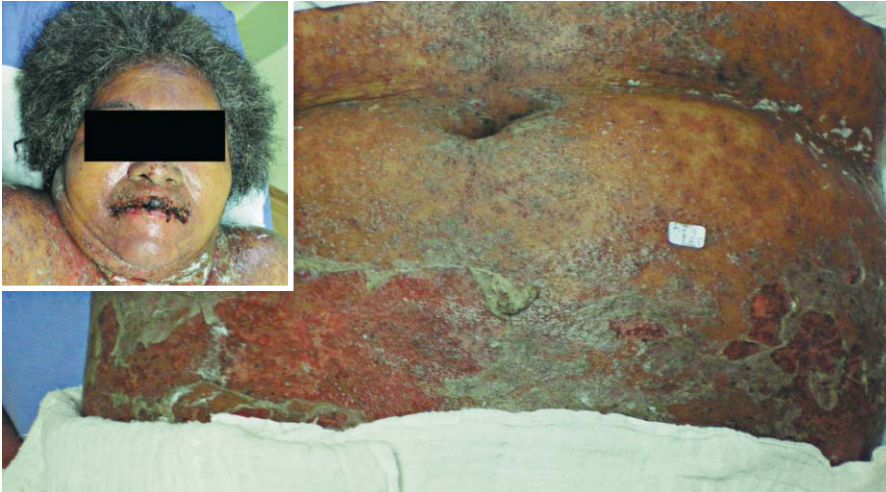

FIGURE 2: Fourth day of the disease. Oral involvement and areas of ulceration on the trunk

Case 2

A 48-year-old woman as admitted having presented bullous lesions for 10 days, after rifampicin, clofazimine and dapsons ingestion for a month for leprosy, and dipyrone. She presented oral and genital mucosal ulcerations, blisters and epidermal detachment in > 80% of body surface area (BSA). Histopathology confirmed TEN. Prednisone 40 mg and IVIG 3 g/kg were prescribed. Her general clinical condition improved significantly, with partial reepithelization five days later and complete recovery on day 14.

Case 3

A 45-year-old man patient reported skin blisters that appeared two days after taking diclofenac. The exam showed erythematous-violaceous plaques, surmounted by blisters. Histopathology confirmed TEN. Prednisone 50mg/day therapy was established. Because of epidermal detachment progression, IVIG

2.5 g/kg was introduced on day 8. After 5 days, blister-outbreak ceased and reepithelization on > 70% BSA was observed (Figures 4 and 5). One day after IVIG treatment ended, a few blisters developed on his arms. Prednisone 0.5 mg/kg/day was reintroduced and blisters gradually diminished, with complete recovery within 7 days.

DISCUSSION

Numerous drugs have been implicated in the pathogenesis of SJS/TEN, making detailed anamnesis fundamental to elucidate the causative drug and prevent future re-exposure.¹

Prospective open studies and case series show evidence on IVIG use in SJS/TEN. Among studies that demonstrated no benefits of IVIG, the largest included patients with chronic renal failure and age >60, factors associated with greater basal mortality, and probably, bad response to IVIG.⁷ Many patients received 2 g/kg of IVIG, a dose lower than presently recommend-

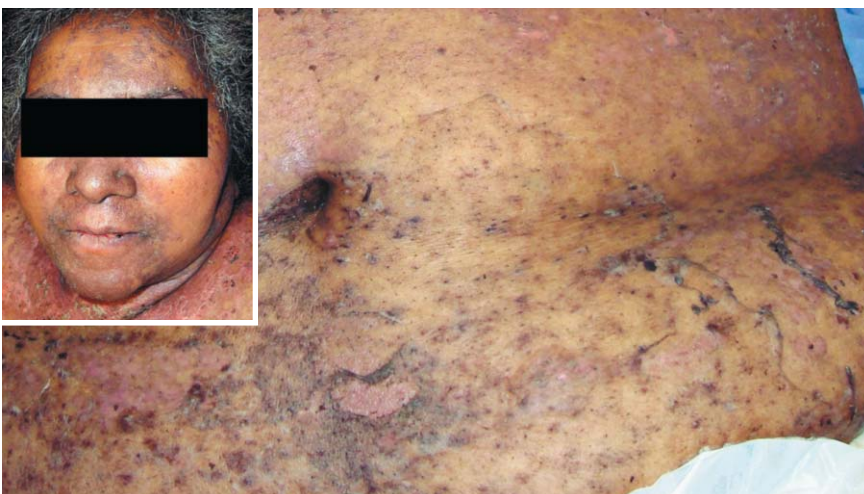

FIGURE 3: Third day of IVIG, with partial reepithelization

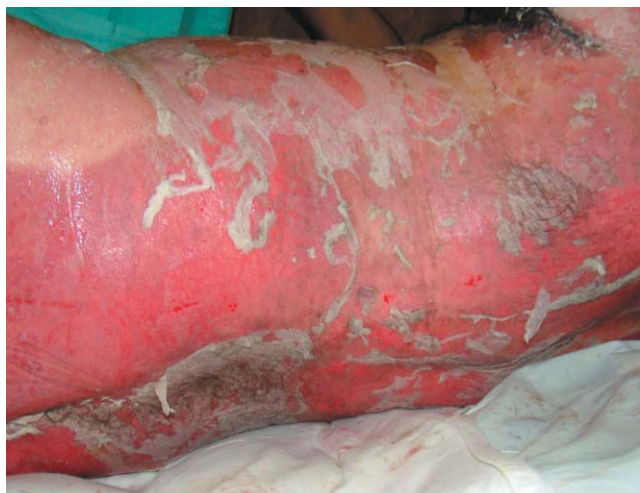

FIGURE 4: Eighth day of evolution, first day of IVIG. Large denuded areas on posterior trunk

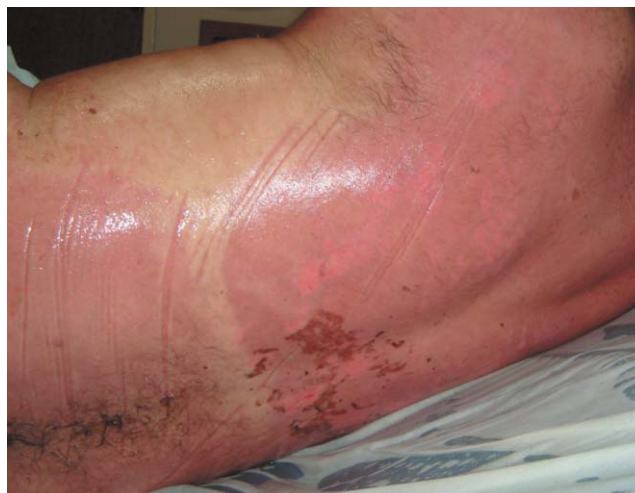

FIGURE 5: Fifth day of IVIG, showing almost complete reepithelization

ed, as also shown in other studies that obtained no benefit.

In a retrospective multicentre-study, 48 patients treated with IVIG had a survival rate of 88%, much higher than expected. Factors associated with death were: old age (average: 66.2); epidermal detachment extension (average: 65%); delay in starting IVIG (average: 10 days); lower dose (<2 g/kg); and coexistent renal, cardiac or infectious diseases and cancer.⁸ In a review, 11 out of 14 studies demonstrated IVIG effectiveness.⁴ A European guideline recommends starting IVIG treatment early after confirmation of TEN diagnosis (evidence level IIIb, recommendation grade C).⁹

In a study on TEN, skin biopsies evaluated by immunohistochemistry showed that most samples positive for Fas/Fas-ligand before therapy, were negative right after treatment with IVIG.¹⁰

Risk of death evaluated by SCORTEN in the first and third cases described was 58.3%, however, there was no available data about the bicarbonate level necessary for a complete evaluation (Table 1). Nevertheless, both cases showed considerable risk of death, with the possibility that IVIG might help their recovery. In the third case there were new blisters after IVIG treatment ended, favoring the protective role of IVIG against keratinocyte apoptosis. We

TABLE 1: The seven independent risk factors of SCORTEN, the score reached by each patient and the corresponding expected mortality

Laboratorial parameters	Case 1		Case 2		Case 3	
Leukogram (mm3) ^a	5.000 wbc / 5% band forms		9.600 wbc / 1% band forms		30.000 wbc / 17% band forms	
Creatinine (mg/dL) ^a	2 mg/dL	1,2 mg/dL	1,6 mg/dL			
SCORTEN parameters^c		Punctuation		Punctuation		Punctuation
Age ≥ 40 years	55 years	X	48 years	X	45 years	X
Malignancy	No		No		No	
Tachycardia > 120 bpm ^d	78 bpm		88 bpm		122 bpm	X
Epidermal detachment >10%	80%	X	>80%	X	80%	X
Urea >10 mmol/L (> 28 mg/dL)	80 mg/dL	X	36 mg/dL	X	54 mg/dL	X
Glucose >114 mmol/L (> 252 mg/dL)	261 mg/dL	X	114 mg/dL		116 mg/dL	
Bicarbonate < 20 mmol/L	-----		-----		-----	
Final score level	4		3		4	
Expected mortality	58,30%		35,30%		58,30%	

^aThese parameters are not included in SCORTEN evaluation; ^b white blood cells; ^c One point each parameter; ^d beats per minute

observed delay in the resolution of exulcerations before IVIG was introduced, possibly due to successive apoptosis of new keratinocytes forming in the basal layer. Treatment with IVIG, therefore, would also promote reepithelization.

TEN is a serious, rapidly progressive systemic-cutaneous condition. After connection between Fas and sFas-Ligand, the signalization chain progresses and programmed keratinocyte death proceeds. This emphasizes the importance of introducing treatment

within 72 hours. However, after this time has elapsed, its use is also indicated, as it could protect non-affected areas and keratinocytes in formation. The three patients described were treated after an average period of 10 days, nevertheless, exceptional improvement could be observed. If the results of future studies corroborate these observations, early prescription of adequate doses of IVIG will be safer, bringing great benefits to patients with TEN. □

REFERENCES

1. Criado PR, Criado RFJ, Vasconcelos C, Ramos RO, Gonçalves. Reações cutâneas graves adversas a drogas - aspectos relevantes ao diagnóstico e ao tratamento - Parte I - anafilaxia e reações anafilactóides, eritrodermias e o espectro clínico da síndrome de Stevens-Johnson & necrólise epidérmica tóxica (Doença de Lyell). *An Bras Dermatol*. 2004;79:471-88.
2. Bastuji-Garin S, Fouchard N, Bertocchi M, Roujeau JC, Revuz J, Wolkenstein P. SCORTEN: a severity of illness score for toxic epidermal necrolysis. *J Invest Dermatol*. 2000;115:149-53.
3. Abe R, Shimizu T, Shibaki A, Nakamura H, Watanabe H, Shimizu H. Toxic epidermal necrolysis and Stevens-Johnson syndrome are induced by soluble Fas ligand. *Am J Pathol*. 2003;162:1515-20.
4. Mydlarski PR, Ho V, and Shear NH. Canadian Consensus Statement on the Use of Intravenous Immunoglobulin Therapy in Dermatology. *J Cut Med Surg*. 2006;10:205-21.
5. Viard I, Wehrli P, Bullani R, Schneider P, Holier N, Salomon D, et al. Inhibition of toxic epidermal necrolysis by blockade of CD95 with human intravenous immunoglobulin. *Science*. 1998;282:490-3.
6. Molgó M, Carreño N, Hoyos-Bachiloglou R, Andresen M, González S. Uso de inmunoglobulina humana endovenosa en pacientes con necrolisis epidérmica tóxica y síndrome de sobreposición Stevens Johnson necrolisis tóxica epidérmica. *Rev Méd Chile*. 2009;137:383-9.
7. Bachot N, Revuz J, Roujeau JC. Intravenous immunoglobulin treatment for Stevens-Johnson syndrome and toxic epidermal necrolysis: a prospective non-comparative study showing no benefit on mortality or progression. *Arch Dermatol*. 2003;139:33-6.
8. Prins C, Kerdel FA, Padilla RS, Hunziker T, Chimenti S, Viard I, et al. TEN-IVIG Study Group. Toxic epidermal necrolysis-intravenous immunoglobulin. Treatment of toxic epidermal necrolysis with high-dose intravenous immunoglobulins: multicenter retrospective analysis of 48 consecutive cases. *Arch Dermatol*. 2003;139:26-32.
9. Enk A; European Dermatology Forum Guideline Subcommittee. Guidelines on the use of high-dose intravenous immunoglobulin in dermatology. *Eur J Dermatol*. 2009;19:90-8.
10. Romanelli P, Schlam E, Green JB, Trent JT, Ricotti C, Elgart GW, et al. Immunohistochemical evaluation of toxic epidermal necrolysis treated with human intravenous immunoglobulin. *G Ital Dermatol Venereol*. 2008;143:229-33.

MAILING ADDRESS:

Cristiane Comparin
 Serviço de Dermatologia Dr. Günter Hans
 Hospital Universitário – NHU/UFMS
 Av. Sen. Filinto Müller, S/N. Vila Ipiranga
 79090-190 Campo Grande, MS
 E-mail: cris_comparin@yahoo.com.br

How to cite this article: Comparin C, Hans-Filho G, Takita LC, Costa NCW, Nascimento RAF, Nanni LC. Treatment of Toxic Epidermal Necrolysis with Intravenous Immunoglobulin: a series of three cases. *An Bras Dermatol*. 2012;87(3):477-81.