

A unique case of hereditary bilateral segmental neurofibromatosis on the face^{*}

Neurofibromatose segmentar bilateral hereditária da face: caso único

Irena Jankovic¹
Milan Visnjic²
Milena Velickovic⁴

Predrag Kovacevic²
Dimitrije Jankovic³

Abstract: Segmental neurofibromatosis is a rare clinical finding generally with no family history and facial involvement. There are four subtypes of segmental neurofibromatosis: true segmental, localized cases with deep involvement, hereditary segmental and bilateral segmental neurofibromatosis. Here we report three patients from the same family (father, son and granddaughter) with segmental bilateral neurofibromatosis on the face. This form hasn't noticed in the literature.

Keywords: Face; Neurofibromatoses; Skin

Resumo: A neurofibromatose segmentar é um achado clínico raro, geralmente com história familiar negativa e raro envolvimento facial. Existem quatro subtipos de neurofibromatose segmentar: segmentar verdadeira, segmentar com envolvimento visceral profundo, segmentar com história familiar e segmentar cutânea bilateral. Aqui nós reportamos três pacientes de uma mesma família (pai, filho e neta) com neurofibromatose segmentar bilateral na face. Esta forma ainda não foi relatada na literatura.

Palavras-chave: Face; Neurofibromatoses; Pele

INTRODUCTION

Segmental neurofibromatosis (SN) is a rare disorder. It is characterized by neurofibromas and /or café-au-lait macules limited to an area or segment of the body. Facial involvement is very rare. It was initially defined as involvement of "one side of the body", but not all cases are unilateral. Segmental neurofibro-

matosis occurs in four subtypes, described as a true segmental type (Riccardi's neurofibromatosis 5), a localized type with deep involvement, a hereditary type, and a bilateral type.¹ Segmental cases are explained by somatic mutations occurring in late embryonic development. At present, 150 segmental

Received on 10.09.2011.

Approved by the Advisory Board and accepted for publication on 07.12.2011.

^{*} Study carried out at the Clinic of Plastic and Reconstructive Surgery, Clinical Center Nis, Serbia.

Conflict of interest: None

Financial funding: None

¹ Plastic and Reconstructive surgeon, PhD, Assistant Professor. Clinic of Plastic and Reconstructive Surgery, Clinical Center Nis, Serbia.

² Plastic and Reconstructive surgeon, PhD, Professor. Clinic of Plastic and Reconstructive Surgery, Clinical Center Nis, Serbia.

³ Internist, PhD, Assistant Professor. Faculty of Cosmetology and Esthetics Banja Luka, Department of Pathology and Pathophysiology, University Synergy Bjeljina, Bosnia and Herzegovina.

⁴ DMD Health Center Nis, Serbia.

cases of neurofibromatosis have been described in the literature. Familial occurrence has been reported in only eight families.²

We present a case with familial occurrence of segmental bilateral neurofibromatosis on the face.

CASE REPORT

Three patients from the same family (father, son and granddaughter) were admitted to our clinic with lesions on their faces (Figure 1).

The 61-year-old father presented multiple small and discrete elevated lesions on his forehead and nasolabial areas, which had developed progressively on the nose and cheek over the past 22 years (Figure 2). On examination, coalescing pink and shiny colored papulonodular lesions (0.5 - 1cm) were

observed distributed over the nasolabial area. On palpation, lesions were mostly soft in consistency and nontender. There were no telangiectasia, ulceration or other surface changes. No other abnormalities were detected on the rest of the body. His general physical examination was normal including intelligence, speech, and auditory functions. Neurological examination did not reveal abnormalities. Slit lamp examination of the eyes did not detect any abnormality. Imaging did not reveal any bone abnormality or malignancy. A 37-year-old son presented multiple small elevated lesions over his forehead and nasolabial areas (Figure 3). A 12-year-old granddaughter also had lesions over her nasolabial areas (Figure 4).

Their lesions had developed since early childhood. Surgical treatment was applied to both father

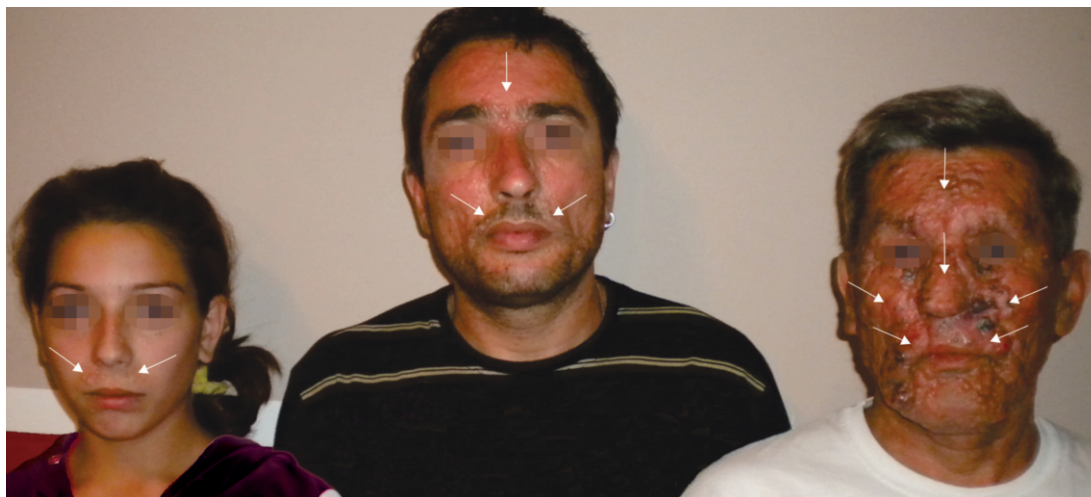

FIGURE 1: Family (right - father, middle - son and left - granddaughter) with segmental bilateral neurofibromatosis on the face

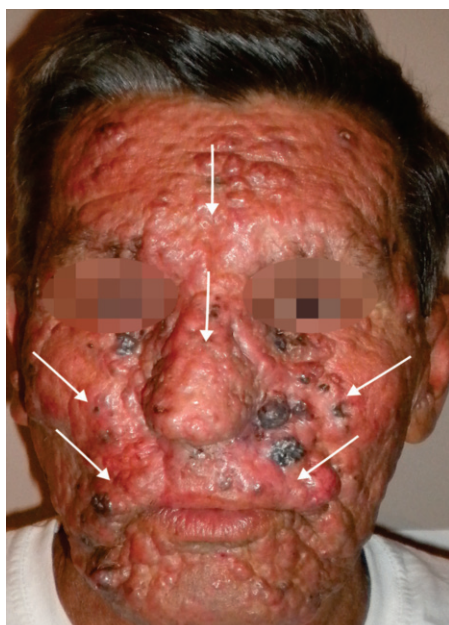


FIGURE 2: Father with diffuse facial lesions of his whole face

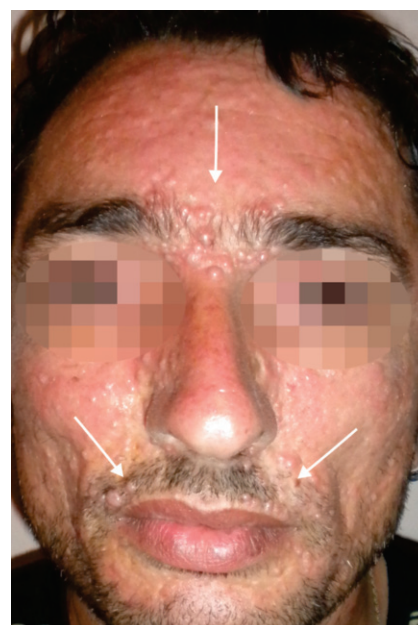

FIGURE 3: Son with multiple small elevated lesions over his forehead and nasolabial areas

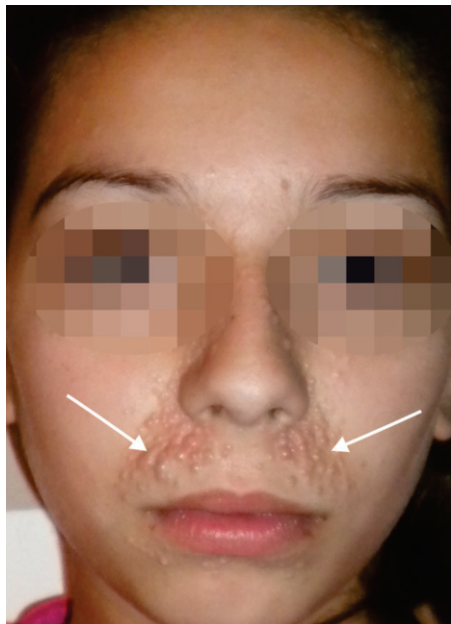

FIGURE 4:
Granddaughter
with lesions over
her nasolabial
areas

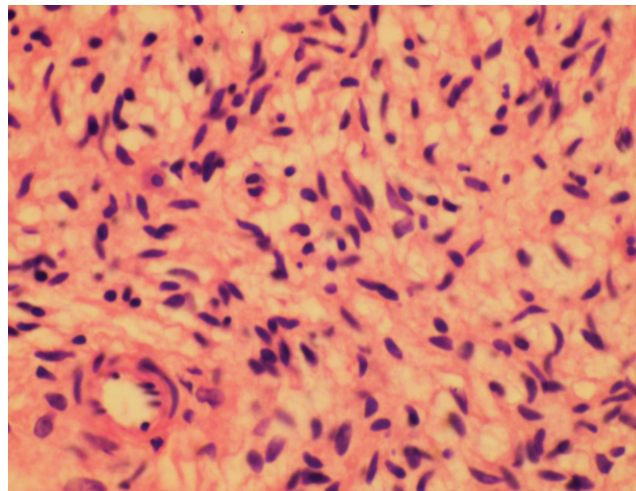


FIGURE 5: Photomicrograph showing a proliferation of fusiform cells in a loose fibrous stroma (H&E, X400)

and son for tumour reduction. Histologic examination of skin biopsies taken from lesions revealed a proliferation of fusiform cells in a loose fibrous stroma, consistent with neurofibroma (Figure 5).

Within a follow-up period of 2 years there was progression of the lesions of the father. Surgical treatment of nasolabial lesion was performed again.

DISCUSSION

SN was first described by Gammel in 1931.³ Following this Crowe et al. described additional patients with neurofibromas and cafe-au-lait macules in a dermatomal distribution and suggested the nomenclature "sectorial neurofibromatosis".⁴ Miller and Sparkes proposed the SN term, which is still used in contemporary literature.⁵ According to Riccardi's classification, SN is included in Type V neurofibromatosis that includes unilateral SN.⁶ However, many apparent cases could not fulfill these stringent criteria. Roth et al. further classified SN into four subtypes: true segmental, localized cases with deep involvement, hereditary segmental and bilateral SN.¹

The etiology of SN is poorly understood. Early somatic mutations cause generalized disease, clinically indistinguishable from nonmosaic forms. Later somatic mutation gives rise to localized disease often

described as segmental. In individuals with mosaic or localized manifestations of SN, disease features are limited to the affected area, which varies from a narrow strip to one quadrant and occasionally to one half of the body. Distribution is usually unilateral but can be bilateral, either in a symmetric or asymmetrical arrangement. To date more than 100 cases of SN have been reported, and facial involvement is very rare. To the best of our knowledge, there are only four earlier published reports on facial involvement in SN.⁷⁻⁹ Common affected sites reported for SN are the thorax and abdomen in 55% of cases, upper extremities and inguinal/axillary in 20% each, lower limb and face in 10% each.¹⁰ Cases of SN have been reported in association with extracutaneous manifestations including visceral neurofibromas, soft tissue hypertrophy, skeletal abnormality, and unilateral renal agenesis. Generally, there is no family history of similar disorder in patients with SN and it has been reported in only eight cases.² This is probably the fifth reported case of SN affecting the face and ninth reported case of familial occurrence, as well as the first report in which an individual is affected with hereditary segmental and bilateral neurofibromatosis. To conclude, this case of SN is reported for its rarity and atypical occurrence. □

REFERENCES

1. Maldonado Cid P, Sendagorta Cudós E, Noguera Morel L, Beato Merino MJ. Bilateral segmental neurofibromatosis diagnosed during pregnancy. *Dermatol Online J.* 2011;17:6.
2. Oguzkan S, Cinbis M, Ayter S, Anlar B, Aysun S. Familial segmental neurofibromatosis. *J Child Neurol.* 2004;19:392-4.
3. Gammel JA. Localized neurofibromatosis. *Arch Dermatol Syphilol.* 1931;24:712-3.
4. Crowe FW, Schull WJ, Neel JVA. Clinical, pathological and genetic study of multiple neurofibromatosis. Springfield, IL: Charles C. Thomas; 1956.
5. Miller RM, Sparkes RS. Segmental neurofibromatosis. *Arch Dermatol.* 1977;113:837-8.
6. Riccardi VM. Neurofibromatosis: clinical heterogeneity. *Curr Prob Cancer.* 1982;7:1-34.
7. Hager CM, Cohen PR, Tschen JA. Segmental neurofibromatosis: case report and review. *J Am Acad Dermatol.* 1997;37:864-9.
8. Dogra S, Kumaran MS, Radotra BD, Kanwar AJ. Segmental neurofibromatosis on the face. *Clin Exp Dermatol.* 2004;29:556-8.
9. Agarwal A, Thappa DM, Jayanthi S, Shivaswamy KN. Segmental neurofibromatosis of face. *Dermatol Online J.* 2005;11:33.
10. Stolarczuk DA, Silva AL, Figueiras FM, Alves MF, Silva SC. Neurofibroma subungueal solitario: relato de um caso inedito no sexo masculino. *An Bras Dermatol.* 2011;86:569-72.

MAILING ADDRESS:

Irena Jankovic

Blvd dr Zorana Djindjica 48

18000 Nis Serbia

E-mail: irenajankovic1410@gmail.com

How to cite this article: Jankovic I, Kovacevic P, Visnjic M, Jankovic D, Velickovic M. A unique case of hereditary bilateral segmental neurofibromatosis on the face. *An Bras Dermatol.* 2012;87(6):895-8.