

Case for diagnosis

Caso para diagnóstico

Kleyton de Carvalho Mesquita¹

Izelda Maria Carvalho Costa²

CASE REPORT

We describe the case of a twelve-year old patient presented with a four-month history of painful coalescent ulcerations in the oral cavity and lips, including the tongue and palate, with edema, erythema, and crusts. Three months later, he presented erythematous vegetating ulcers on the basis of the penis and in the perianal region (Figure 1). He had no other complaints.

Laboratory tests resulted in normal complete blood count, complement, and immunoglobulins. Serology for viral hepatitis, syphilis, and HIV were negative. Tests showed high inflammatory activity. The ASCA test (ASCA IgG: 46,13U; IgA: 50,89U) was positive; the p-ANCA and c-ANCA tests were negative. Colonoscopy was normal.

Histopathology of the lower lip and of the lesions on the basis of the penis showed suprabasal acantholytic cleft and a mixed inflammatory process, with eosinophils. Skin fragments from the perianal region revealed epidermal hyperplasia, neutrophil abscesses, intraepithelial eosinophils, and a moderate mixed inflammatory process, with eosinophils on the dermis (Figure 2). Direct Immunofluorescence (DIF) was negative for immunoglobulin and complement deposits in the oral mucosa.

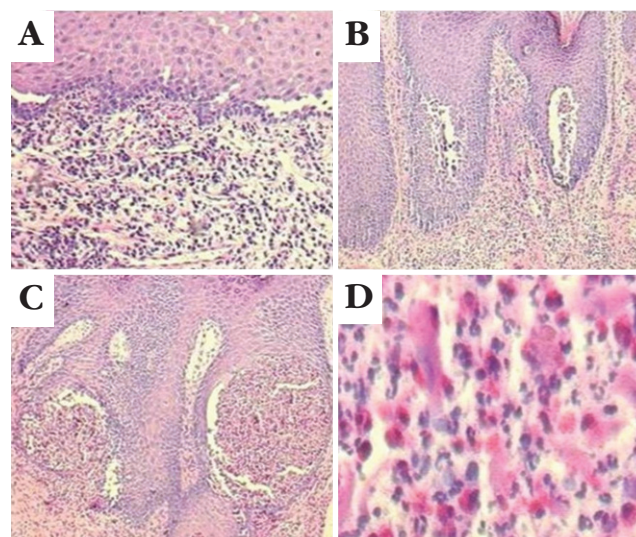


FIGURE 2: A. Lower lip mucosa: suprabasal clefts and acantholytic cells, mixed inflammatory process with eosinophils. (H&E X 20). B. Skin of the basis of the penis: epidermal hyperplasia and suprabasal multifocal acantholysis formed by clefts where there are eosinophils and neutrophils; on the dermis, moderate mononuclear inflammatory infiltrate, with eosinophils and neutrophils. (H&E X 10). C. Perianal plaque skin: epidermal hyperplasia and intraepithelial voluminous abscesses. (H&E X 10). D. Detail of the abscess: neutrophilic infiltrate with numerous eosinophils and dissociated keratinocytes. (H&E X 40)

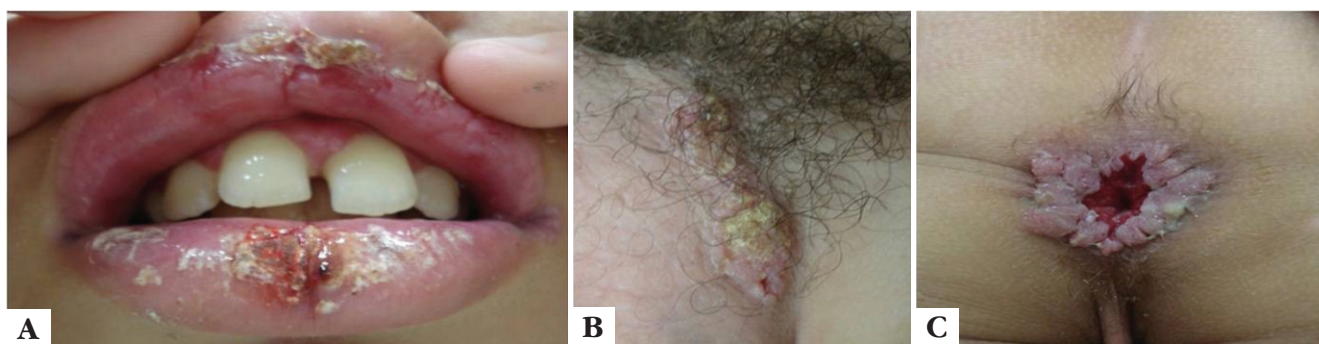


FIGURE 1: A. Lips: ulcerated crusted lesions in the lip mucosa; B. Basis of the penis: erythematous crusted plaques; C. Perianal region: vegetating erythematous plaque

Received on 16.12.2011.

Approved by the Advisory Board and accepted for publication on 13.11.2012.

* Work conducted at the Hospital University of Brasília (Hospital Universitário de Brasília) – University of Brasília (Universidade de Brasília - HUB-UnB) – Brasília (DF), Brazil.

Conflict of interest: None

Financial funding: None

¹ MSc student of Health Sciences – University of Brasília (Universidade de Brasília – UnB) – Dermatologist, Federal District Department of Health (Secretaria do Estado de Saúde do Distrito Federal – SES-DF) – Brasília (DF), Brazil.

² PhD in Dermatology, Federal University of Sao Paulo (Universidade Federal de Sao Paulo - UNIFESP) – Professor of Dermatology, University of Brasília (Universidade de Brasília - UnB) – Brasília (DF), Brazil.

©2012 by Anais Brasileiros de Dermatologia

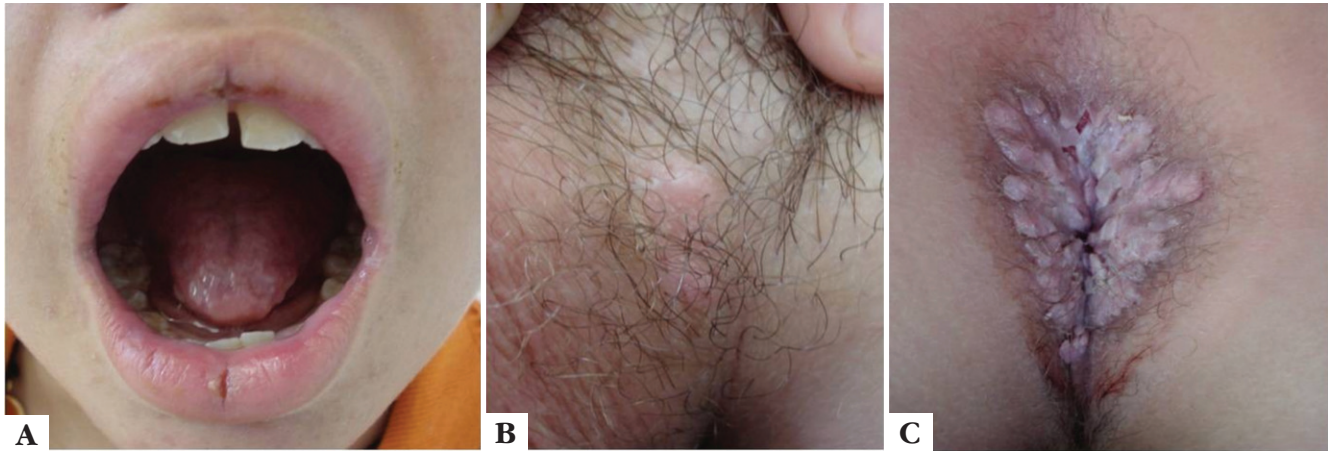


FIGURE 3: Eighteen weeks after beginning treatment. Marked improvement of ulcerated lesions of the lip mucosa (A) and of the erythematous crusted plaque on the basis of the penis (B). There has been slow improvement of the perianal lesion (C)

DISCUSSION

Based on the clinical presentation and histopathological findings, the main diagnoses considered were pemphigus vegetans (a variant of pemphigus vulgaris) and pyodermitis-pyostomatitis vegetans (PD-PSV). The differentiation between them could only be made by immunofluorescence, since clinical presentation and histopathological findings are very similar in both diseases. Direct and indirect immunofluorescence (DIF and IIF) are negative or weakly positive in PD-PSV, whereas they are positive and reveal strong intercellular deposits of IgG and C3 in pemphigus vegetans.¹⁻³ Considering that our patient's DIF test was negative, we made the definite diagnosis of PD-PSV.

PD-PSV is a rare inflammatory disease characterized by pustular and vegetating plaques that affect the skin and mucous membranes. The etiology of PD-PSV is unknown, and its pathogenesis is poorly understood.^{1,4,5} It is associated with gastrointestinal disease and has been described as a highly specific marker for inflammatory bowel diseases (IBD).^{6,7} Diagnostic differentiation between PD-PSV and pemphigus vegetans is essential, even though immunosuppressant regi-

men would be similar. The association of PD-PSV with IBD is well known, and IBD precedes the onset of oral lesions by months or years in most cases. Ulcerative colitis occurs in 70-78%, and Crohn's disease is seen in 11% of patients. In about 15% of cases, skin lesions precede gastrointestinal symptoms. Therefore, patients with PD-PSV must be monitored to detect the onset of IBD. There is not a single treatment protocol, and none of the treatment regimens presented solid scientific evidence of having superior efficacy.^{2,3,8,9}

The patient was treated with prednisone 1mg/Kg/day and azathioprine 1mg/Kg/day. Corticosteroid doses were gradually tapered and stopped at the end of six months. After normal dosing of glucose-6-phosphate-dehydrogenase, dapsone 100mg/day was introduced as a corticoid-sparing agent, and azathioprine was discontinued one month later. The patient showed improvement of the lesions, which was slower for the perianal plaques (Figure 3). The patient was followed up as an outpatient for nine months. After that, dapsone was discontinued. He took part in periodic screening protocols (clinical and laboratorial) for early detection of IBD. □

Abstract: Pyodermatitis-pyostomatitis vegetans is a rare mucocutaneous dermatosis characterized by pustular and vegetating lesions of the skin and oral mucosa. It is considered a highly specific marker for inflammatory bowel diseases. The authors describe a case of pyodermatitis-pyostomatitis vegetans in a pediatric patient who presented marked clinical improvement after beginning treatment with oral corticosteroids, azathioprine, and dapsone. Bowel surveillance is mandatory, since the dermatosis is associated with inflammatory bowel diseases in more than 70% of patients, especially ulcerative colitis.

Keywords: Colitis, ulcerative; Crohn disease; Eosinophilia; Inflammatory bowel diseases; Skin diseases

Resumo: A piodermatite-pioestomatite vegetante é uma dermatose mucocutânea rara, caracterizada por lesões pustulosas e vegetantes na pele e mucosa oral. É considerada um marcador altamente específico para doenças intestinais inflamatórias. Os autores descrevem um caso de piodermatite-pioestomatite vegetante em paciente pediátrico, o qual apresentou boa resposta a corticoterapia oral associada à azatioprina e à dapsona. A vigilância intestinal é mandatória, uma vez que a dermatose está associada a doenças intestinais inflamatórias em mais de 70% dos casos, especialmente a colite ulcerativa.

Palavras-chave: Colite ulcerativa; Dermatopatias; Doença de Crohn; Doenças inflamatórias intestinais; Eosinofilia

REFERENCES

1. Cunha PR, Barraviera SR. Dermatoses bolhosas autoimunes. *An Bras Dermatol.* 2009;84:111-24.
2. Nigen S, Poulin Y, Rochette L, Lévesque MH, Gagné E. Pyodermatitis-Pyostomatitis Vegetans: Two Cases and a Review of the Literature. *J Cutan Med Surg.* 2003;7:250-5.
3. Hegarty AM, Barrett AW, Scully C. Pyostomatitis vegetans. *Clin Exp Dermatol.* 2004;29:1-7.
4. Matias FAT, Rosa DJF, Carvalho MTF, Castañon MCMN. Piodermatitepioestomatite vegetante: relato de caso e revisão de literatura. *An Bras Dermatol.* 2011;86(Supl 1):S137-40.
5. Femiano F, Lanza A, Buonaiuto C, Perillo L, Dell'Ermo A, Cirillo N. Pyostomatitis vegetans: a review of the literature. *Med Oral Patol Oral Cir Bucal.* 2009;14:E114-7.
6. Al-Rimawi H, Hammad M, Raweily E, Hammad H. Pyostomatitis vegetans in childhood. *Eur J Pediatr.* 1998;157:402-5.
7. Leibovitch I, Ooi C, Huilgol S, Reid, James CL, Selva D. Pyodermatitis-pyostomatitis vegetans of the eyelids case report and review of the literature. *Ophthalmology.* 2005;112:1809-13.
8. Yasuda M, Amano H, Nagai Y, Tamura A, Ishikawa O, Yamaguchi S. Pyodermatitis-pyostomatitis vegetans associated with ulcerative colitis: successful treatment with total colectomy and topical tacrolimus. *Dermatology.* 2008; 217:146-8.
9. Ruiz-Roca J, Berini-Aytés L, Gay-Escoda C. Pyostomatitis vegetans. Report of two cases and review of the literature. *Oral Surg Oral Med Oral Pathol Oral Radiol Endod.* 2005; 99:447-54.

MAILING ADDRESS:

Kleyton de Carvalho Mesquita.

QE 34, conjunto P, casa 25. Guará II.

71065-162 Brasília, DF

E-mail address: kleyton.mesquita@gmail.com

How to cite this article: Mesquita KC, Costa IMC. Case for diagnosis. Pyodermatitis-pyostomatitis vegetans - Case report. *An Bras Dermatol.* 2012;87(6):929-31.