



Nail apparatus melanoma: a diagnostic opportunity*

Melanoma do aparelho ungueal: uma oportunidade diagnóstica

Ana Maria Carreño¹
Silmara N. Pennini³
Antonio Pedro Mendes Schettini³

Sílvia Rocha Nakajima²
Renato Candido Junior⁴

Abstract: Malignant Melanoma is a high mortality neoplasm. The involvement of the nail apparatus is rare, with only 2 out of 3 patients seeking medical attention as the result of recent nail melanocytic lesions. This results in late diagnosis and a prognosis worse than cutaneous melanoma. We report a female, presenting with ulcerative lesions with clinical and laboratory features compatible with leishmaniasis. On return after treatment initiation a longitudinal melanonychia was observed on her first right finger. Biopsy of the nail matrix was performed. Histopathology was compatible with melanoma in situ. Longitudinal melanonychia is not a specific sign for melanoma and it is important that the dermatologist should identify the suspect lesions correctly. The incidental diagnosis of nail melanoma in situ in our case significantly impacted the patient's survival.

Keywords: Medical oncology; Melanoma; Nail diseases

Resumo: Melanoma Maligno é uma neoplasia de alta mortalidade, sendo raro o acometimento do aparelho ungueal. Apenas 2/3 dos pacientes procuram atendimento médico devido lesão melanocítica ungueal recente, tornando o diagnóstico tardio e com prognóstico pior que do melanoma cutâneo. Descreve-se um caso de paciente sexo feminino, apresentando lesões ulceradas com características clínico-laboratoriais compatíveis com leishmaniose tegumentar americana. No retorno após início do tratamento foi observada melanoníquia longitudinal no primeiro quirodáctilo direito. Realizada biópsia da matriz ungueal com histopatológico compatível com melanoma in situ. Melanoníquia longitudinal não é sinal específico de melanoma. A identificação das lesões suspeitas é importante tarefa dos dermatologistas. O diagnóstico incidental de melanoma ungueal in situ do caso relatado resultou em grande impacto na sobrevida da paciente.

Palavras-chave: Doenças da unha; Melanoma; Oncologia

INTRODUCTION

Malignant melanoma is a high mortality neoplasm, with an average 5-year survival rate of 56% in developing countries, despite representing only 4% of all skin cancers.^{1,2} Among different types of melanoma, Acral Lentiginous contributes with 5-10% of cases in Caucasian populations.² Nail apparatus involvement is even rarer, with an estimated prevalence of 0.7-3.5% of melanomas.³

Longitudinal melanonychia is the classic clinical presentation of early nail apparatus melanoma but it can also be a sign of other, more benign, conditions.^{4,7} Only 2 out of 3 patients with early nail apparatus melanoma seek medical attention, which results in late diagnosis in most cases, leading to worse prognosis than that of cutaneous melanoma.^{3,8} Traditional treatment has been the amputation of the affected digit up to the proximal joint.³

Received on 26.02.2012.

Approved by the Advisory Board and accepted for publication on 09.05.2012.

* Study conducted at the Alfredo da Matta Foundation (FUAM) - Manaus (AM), Brazil.

Conflict of interest: None

Financial funding: None

¹ Resident in Dermatology at the Federal University of (UFAM) - Manaus (AM), Brazil.

² Resident in Dermatology at the Alfredo da Matta Foundation (FUAM) - Manaus (AM), Brazil.

³ Master's Degree - Dermatologist Physician at the Alfredo da Matta Foundation (FUAM) - Manaus (AM), Brazil.

⁴ Dermatologist Physician at the Alfredo da Matta Foundation (FUAM) - Manaus (AM), Brazil.

CASE REPORT

17-year-old female student from Manaus (Amazonas State), Fitzpatrick's phototype III, presented at the dermatology clinic with two ulcerated lesions. These were consistent with leishmaniasis, both clinically and by lab (presence of *Leshmania sp. amatigotes* pattern on direct examination). Pentavalent antimonial was prescribed. During clinic follow-up, it was noted that the patient had a longitudinal melanonychia on the right thumb (Figure 1). On questioning, she informed that this had been present for approximately one year. She also reported family history of melanoma (great-aunt). Dermatoscopic examination revealed lines varying in color from light brown to black, with different sizes, width and distances, with the most proximal area being more intense and thicker than the distal area, forming a tri-

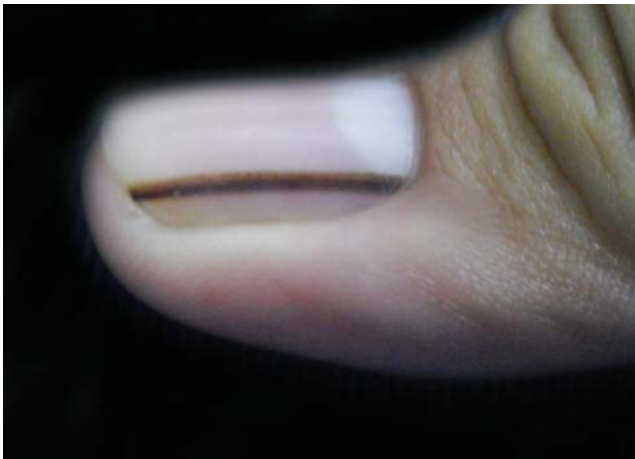

FIGURE 1: Clinical aspect of the patient's longitudinal melanonychia

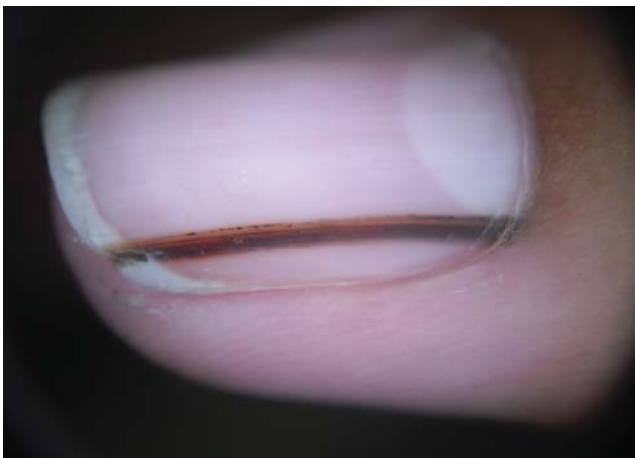

FIGURE 2: Dermatoscopic examination of the patient's longitudinal melanonychia

angular shape (Figure 2). Ungual matrix biopsy was performed by shaving. Histopathology was compatible with melanoma *in situ* (Figure 3). Surgical management involved excision of unguinal apparatus up to periosteal region. Following histopathology no neoplasm showed in the 40 cuts made. Clinical staging was TisN0M0 (Stage 0). Patient followed up for 11 months without recurrence (Figure 4).

DISCUSSION

Nail apparatus melanoma (NAM) is more common among Black and Asian ethnic groups with no gender preference and is more frequent between fifth and seventh decades.^{3,5,7} While 2-3% of melanomas in Caucasians are situated in the unguinal apparatus, this percentage rises to 15-20% in Afro-Caribbeans.³ NAM

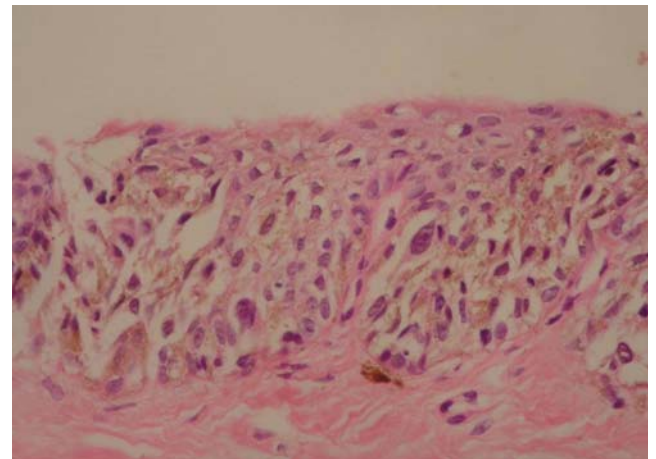


FIGURE 3: Histopathology showing atypical melanocytes not confined to basement membrane with pagetoid spread. No dermal invasion. (HEX40)

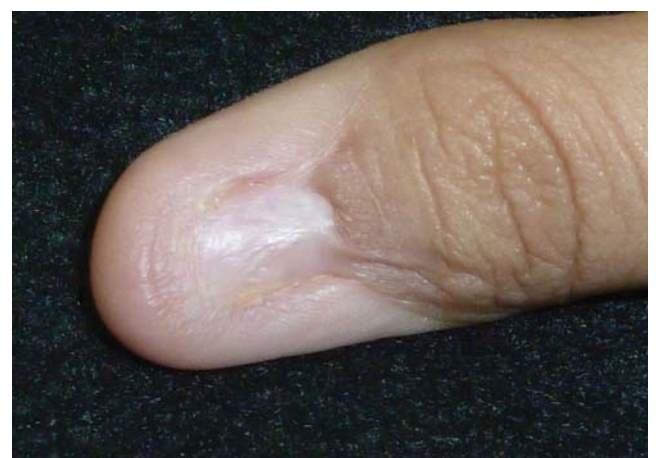

FIGURE 4: Clinical appearance after eleven months of follow-up without signs of recurrence

is more commonly seen on the thumb, followed by the hallux and index finger.^{3,5,7}

NAM typically manifests as longitudinal melanonychia (LM) which can also be a clinical manifestation of other unguis apparatus changes which cause unguis matrix melanocytic activation. The pigmented bands due to continuous growth of the nail plaque can be seen in unguis matrix nevi, benign melanocytic hyperplasia and inflammatory, traumatic and iatrogenic changes.^{4,5,6,7} LM is therefore not a specific sign for NAM, and one of the important functions of the dermatologist is to correctly identify the suspect lesions.

Clinical examination with the naked eye can reveal suggestive characteristics however, not pathognomonic of melanoma such as non-homogeneous pigmentation with different coloured lines, the presence of unguis plaque fissure, the proximal area wider than the distal area (triangular), hazy lateral borders and periungual skin pigmentation (Hutchinson's sign).⁴

Levit *et al.* produced an aide-memoire (ABCDEF rules) to help distinguish alarming from non-alarming melanonychia⁹, as follows:

- A (*age, Afro-Americans, native Americans and Asians*): fifth and seventh decades;
- B (*nail band*): colour from *brown* to *black*, ≥ 3 mm wide, irregular borders;
- C (*change*): rapid increase in size of band and/or change in nail morphology;
- D (*digit involved*): thumb > hallux > index finger, dominant hand, only one digit;
- E (*extension*): Hutchinson's sign;
- F (*family*): personal or familial history of nevi dysplastic syndrome and melanoma.

Dermatoscopy is a non-invasive tool which has allowed a greater degree of diagnostic accuracy of pigmented lesions and the identification of early melanoma compared to visual clinical inspection.¹⁰ Dermatoscopic characteristics associated with NAM are brown bands with irregular longitudinal lines of different colours and widths and with loss of parallel organization. Further findings include micro-

Hutchinson's sign, pigmentation of periungual tissue seen with dermatoscope but not with naked eye.^{4,5,7,10} Although there is no current consensus to dermatoscopic monitoring, Koga *et al.* recommend 6-monthly evaluation of suspicious LM, with patient advised to return sooner if changes in the lesion develop.⁵

Hirata *et al.* have suggested that the use of intraoperative dermatoscopy on the nail bed and matrix with polarized light could result in better visualization of pigmented lesions since this examines the region of melanin production. Although this is an invasive technique it could give the best level of diagnostic accuracy⁶ when compared with clinical examination, ABCDEF rules and traditional dermatoscopy.

Histopathology is still the gold standard, and biopsy can be incisional or excisional.³ Although there is no current consensus on managing unguis melanoma *in situ*, surgical excision entails the complete unguis apparatus itself, including the nail plaque, bed and matrix.⁸ The resulting defect can be corrected with a partial or total skin graft.⁸ In our case, with histopathology of melanoma *in situ*, the surgical treatment chosen was the excision of the entire nail apparatus affected, leaving the lesion to be healed by secondary intention. The shaving biopsy had already included the entire lesion, since the histopathology of second excision showed no more atypical melanocytes.

Compared with cutaneous melanoma, where 80% of cases are diagnosed at the TNM stage I, only 20% of NAM are diagnosed at this stage.³ Late diagnosis decreases the possibility of curative treatment without the need for mutilation, and increases mortality rates. Over 50% of patients die before 5 years after diagnosis.

It is not uncommon for LM to go unnoticed or ignored by patients or even by non-specialist physicians. It remains a challenge for dermatologists. The reported case shows an incidental diagnosis detected at the clinic of nail apparatus melanoma at an early stage, resulting in saving the young woman's thumb and, possibly, her life. This case highlights the importance of a thorough global examination of each patient, together with the need for fuller information to be given to people about the potential malignant nature of longitudinal melanonychia, and draws attention to the dermatologist's key role in the differential diagnosis of this clinical sign. □

REFERENCES

1. Canto ACM, Oliveira J. Melanoma cutâneo: doença curável? Revisão de literatura e apresentação de um organograma de investigação e tratamento. *Rev AMRIGS*. 2007;51:312-6.
2. Bishop JAN. Lentigos, melanocytic naevi and melanoma. In: Burns T, Breathnach S, Cox N, Griffiths C. *Rook's textbook of dermatology*. 8th ed. West Sussex: Wiley-Blackwell; 2010. p. 1-54,57.
3. Mendonça IRSM, Kac BK, Silva RT, Spinelli LP, Orofino RR, França JR. Melanoma do aparelho ungueal. *An Bras Dermatol*. 2004;79:575-80.
4. Di Chiacchio N, Hirata SH, Enokihara MY, Michalany NS, Fabbrocini G, Tosti A. Dermatologists' accuracy in early diagnosis of melanoma of the nail matrix. *Arch Dermatol*. 2010;146:382-7.
5. Koga H, Saida T, Uhara H. Key point in dermatoscopic differentiation between early nail apparatus melanoma and benign longitudinal melanonychia. *J Dermatol*. 2011;38:45-52.
6. Hirata SH, Yamada S, Enokihara MY, Di Chiacchio N, de Almeida FA, Enokihara MM, et al. Patterns of nail matrix and bed of longitudinal melanonychia by intraoperative dermatoscopy. *J Am Acad Dermatol*. 2011;65:297-303.
7. Braun RP, Baran R, Le Gal FA, Dalle S, Ronger S, Pandolfi R, et al. Diagnosis and management of nail pigmentations. *J Am Acad Dermatol*. 2007;56:835-47.
8. Duarte AF, Correia O, Barros AM, Azevedo R, Haneke E. Nail matrix melanoma in situ: conservative surgical management. *Dermatology*. 2010;220:173-5.
9. Levit EK, Kagen MH, Scher RK, Grossman M, Altman E. The ABC rule for clinical detection of subungual melanoma. *J Am Acad Dermatol*. 2000;42:269-74.
10. Phan A, Dalle S, Touzet S, Ronger-Savlé S, Balme B, Thomas L. Dermoscopic features of acral lentiginous melanoma in a large series of 110 cases in a white population. *Br J Dermatol*. 2010;162:765-71.

MAILING ADDRESS:

Antonio Pedro Mendes Schettini
Rua Codajás, 24 - Cachoeirinha
69065-130 Manaus, AM.
Brazil
E-mail: apmschettini@gmail.com

How to cite this article: Carreño AM, Nakajima SR, Pennini SN, Candido Junior R, Schettini APMS. Nail apparatus melanoma: a diagnostic opportunity. *An Bras Dermatol*. 2013;88(2):268-71.