

Primary systemic amyloidosis, acquired cutis laxa and cutaneous mucinosis in a patient with multiple myeloma*

Amiloidose sistêmica primária, cútis laxa adquirida e mucinose cutânea em paciente com mieloma múltiplo

Fernanda Guedes Lavorato¹
 Juan Manuel Piñeiro Maceira³
 Laura Araújo Serpa¹

Maria de Fátima Guimarães Scotelaro Alves²
 Natasha Unterstell¹
 Luna Azulay-Abulafia⁴

DOI: <http://dx.doi.org/10.1590/abd1806-4841.20132531>

Abstract: A 57-year-old woman presented with periorbital ecchymoses, laxity in skin folds, polyneuropathy and bilateral carpal tunnel syndrome. A skin biopsy of the axillary lesion demonstrated fragmentation of elastic fibers, but with a negative von Kossa stain, consistent with cutis laxa. The diagnosis of primary systemic amyloidosis was made by the presence of amyloid material in the eyelid using histopathological techniques, besides this, the patient was also diagnosed with purpura, polyneuropathy, bilateral carpal tunnel syndrome and monoclonal gammopathy. She was diagnosed as suffering from multiple myeloma based on the finding of 40% plasma cells in the bone marrow, component M in the urine and anemia. The patient developed blisters with a clear content, confirmed as mucinosis by the histopathological exam. The final diagnoses were: primary systemic amyloidosis, acquired cutis laxa and mucinosis, all related to multiple myeloma.

Keywords: Amyloidosis; Cutis laxa; Mucinoses; Multiple myeloma

Resumo: Mulher de 57 anos, com equimose periorbitária, frouxidão cutânea nas dobras, polineuropatia e síndrome do túnel do carpo bilateral. O exame histopatológico da lesão axilar revelou fragmentação de fibras elásticas, porém a coloração de von Kossa foi negativa; o diagnóstico foi de cútis laxa. Amiloidose sistêmica primária foi confirmada pela presença de material amilóide no exame histopatológico da pálpebra, além de púrpura, polineuropatia, síndrome do túnel do carpo bilateral e gamopatia monoclonal. Foi diagnosticada como portadora de mieloma múltiplo por apresentar 40% de plasmócitos na medula óssea, componente M urinário e anemia. A paciente evoluiu com bolhas de conteúdo citrino, cujo exame histopatológico mostrou mucinose. Os diagnósticos finais foram: amiloidose sistêmica primária, cútis laxa adquirida e mucinose, todos vinculados ao mieloma múltiplo.

Palavras-chave: Amiloidose; Cútis laxa; Mieloma múltiplo; Mucinoses

INTRODUCTION

Systemic amyloidosis may occur associated to clonal lymphoid diseases in which immunoglobulins are produced, including non-Hodgkin's lymphoma, Waldenström's macroglobulinemia and multiple myeloma (MM).

Acquired cutis laxa (CLA) is rare and may appear at any age. There are reports of its association with plasma cell dyscrasias, including MM.¹ The link

between CLA and MM remains uncharted, however, it is believed to be immune mediated.² There is no synchronism between the courses of MM and CLA.

Mucinosis may also occur in cases of paraproteinemia, such as MM.

The case reported here features primary systemic amyloidosis, acquired cutis laxa and cutaneous mucinosis in a patient with MM.

Received on 11.02.2013.

Approved by the Advisory Board and accepted for publication on 18.05.2013.

* Work performed at Pedro Ernesto University Hospital at Rio de Janeiro State University (HUPE-UERJ) - Rio de Janeiro (RJ), Brazil.

Conflict of interest: None

Financial funding: None

¹ MD, Dermatologist with residency in Dermatology at Pedro Ernesto University Hospital at Rio de Janeiro State University (HUPE-UERJ) - Rio de Janeiro (RJ), Brazil.

² MD, PhD. Associate Professor of dermatology at Pedro Ernesto University Hospital at Rio de Janeiro State University (HUPE-UERJ) - Rio de Janeiro (RJ), Brazil.

³ MD, Post-doctorate at the Armed Forces Institute of Pathology. - Associate professor at Rio de Janeiro Federal University (UFRJ), - Rio de Janeiro (RJ), Brazil.

⁴ MD, PhD in dermatology, Adjunct Professor of dermatology at Rio de Janeiro State University (UERJ), Chair Professor of dermatology at Gama Filho University - Rio de Janeiro (RJ), Brazil.

CASE REPORT

A fifty-seven year old, female informed the presence of bilateral eyelid hyperchromia for the last fifteen years, followed by an increase in palpebral volume that started three years after the first symptoms. Six years ago, she observed cutaneous laxity in skin-fold areas and bilateral palpebral ptosis. In the last four years, the patient reports pain and paresthesia in a stocking-like pattern affecting the lower limbs. The patient denied any familial history of cutaneous lesions.

She had a previous history of bilateral carpal tunnel syndrome and blepharoplasties performed in two different occasions, 2008 and 2009.

Dermatologic examination of eyelids showed hyperchromia, increase of local volume, cutaneous laxity and bilateral ptosis with periorbital ecchymoses (Figure 1). We observed cutaneous laxity, hyperchromic papules and comedones over the skinfolds, such as the armpits, cervical and inframammary regions (Figure 2). Biopsies of both axillary and palpebral lesions were performed.

Histopathological examination of the axillary lesion did not show any significant alteration with hematoxiline-eosine stain, detecting only one epidermic cyst, corresponding to the observed papule. Orcein staining showed the fragmentation of elastic fibers and von Kossa staining was negative, i.e., without evidence of calcium, thus establishing the diagnosis of acquired cutis laxa (Figure 3).

Histological exam of the palpebral material showed an amorphous eosinophilic substance, located on the superior and vascular dermises, positive for red Congo staining and with green birefringence to polarized light, which confirmed the diagnosis of amyloidosis (Figure 4).

Laboratory exams demonstrated normocytic and normochromic anemia, an inversion of the albumin-globulin ratio, IgG-Kappa monoclonal gammopathy, Bence-Jones proteinuria and 40% of plasma cells in the bone marrow specimen, prompting a diagnosis of multiple myeloma.

The patient evolved with citrine-content blisters on the inframammary region. A plaque, with severe edema, located on the left arm was biopsied, showing dermic edema with moderate fibroblast proliferation, some of which were stellate (Figures 5A and 5B). Colloidal iron staining determined the presence of mucin, and the diagnosis of papular mucinosis, which was not in agreement with the clinical presentation, thus making it difficult to classify the disease in this case (Figures 5C and 5D). A negative result for red Congo stain discarded bullous amyloidosis.

The final diagnoses were, accordingly, primary systemic amyloidosis, acquired cutis laxa and cuta-

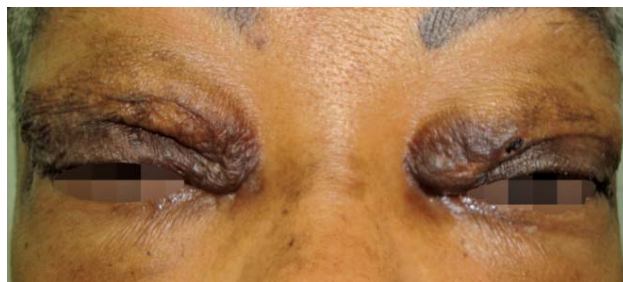

FIGURE 1: Noticeable ecchymoses, increase in local volume, laxity of skin and bilateral palpebral ptosis

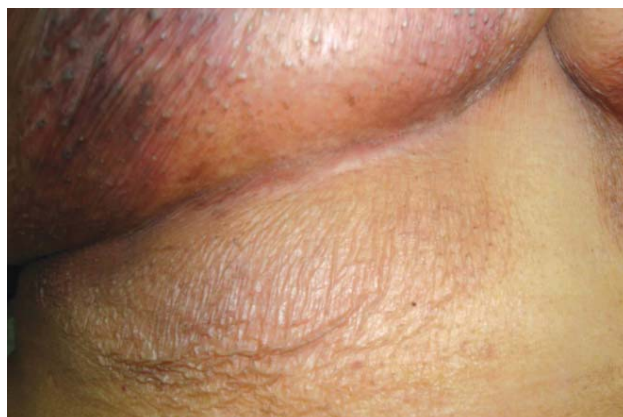

FIGURE 2: Laxity of skin on the inframammary region

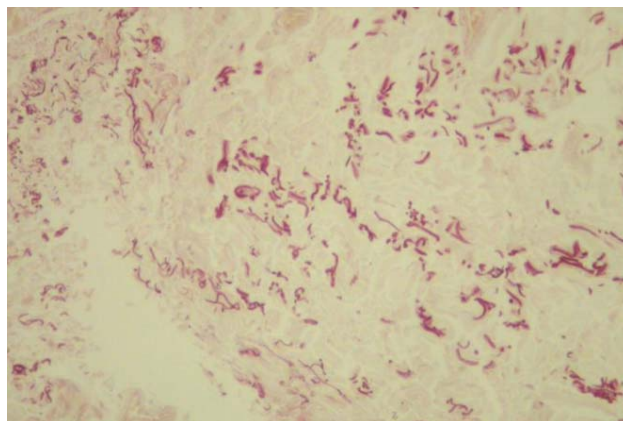


FIGURE 3: Skin specimen from the axillary lesion, stained by orcein, showing fragmented elastic fibers

neous mucinosis, all dermatologic manifestations associated to MM.

DISCUSSION

The diagnosis of primary systemic amyloidosis was made based on the following findings: presence of amyloid material on the perivascular dermis; purpura – including in the periorbital area, considered a marker for this disease; polyneuropathy; bilateral carpal tunnel syndrome; inversion of the albumin-

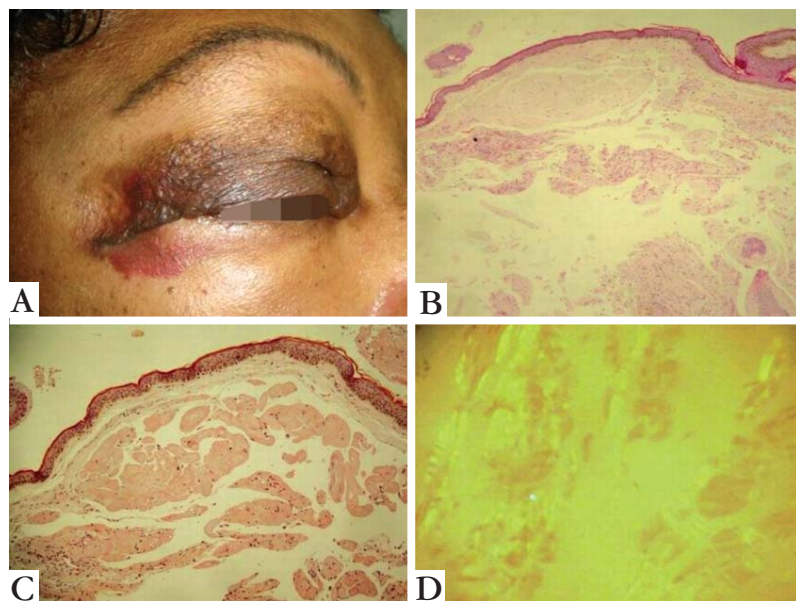


FIGURE 4: A. Periorbital ecchymoses; B. Skin fragment from the palpebral lesion, stained by HE, showing: amorphous eosinophilic substance, in the superior dermis; C. Red Congo stain highlighting the amyloid substance in the superior dermis; D. Red Congo stain under polarized light, revealing the green birefringence of the amyloid substance

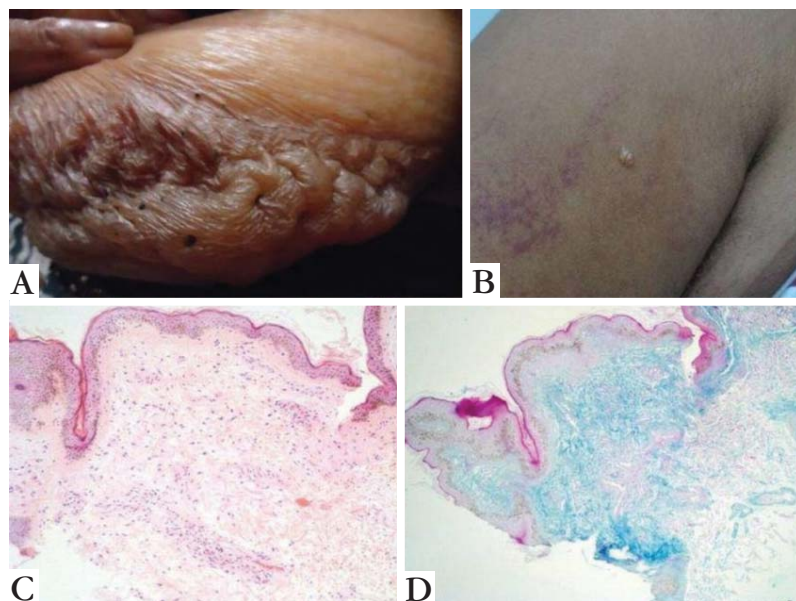


FIGURE 5: A. Inframammary blister, with citrine content; B. Plaque with severe edema and purpuric lesions on the left arm C. HE: edema in the dermis and stellate fibroblasts; D. Colloidal iron: presence of mucin in the dermis

globulin ratio and IgG-Kappa monoclonal gammopathy. The patient was diagnosed with MM by presenting 40% of plasma cells in the bone marrow exam, urinary M component and anemia.

Carpal tunnel syndrome appears in 25% of cases of primary systemic amyloidosis, and it is often bilateral.³ The peripheral nervous system may also be affected. Both conditions were detected in our patient.

Mucocutaneous alterations are present in 20 to 40% of the cases, frequently as the first signs of amyloidosis.³ The following may also occur: purpura (spontaneous or secondary to minimal trauma), waxy papules, plaques or nodules (these are the most distinctive lesions) on skinfolds and affecting the central area of the face, and macroglossia. Purpuric lesions

are the most frequent ones, and may affect all the body, however the characteristic lesion is the periorbital one ("raccoon eyes").⁴ Those are believed to be secondary to amyloid deposits on the vascular walls, creating capillary frailty.

Multiple myeloma rarely affects the skin. There are, however, several diseases that have cutaneous manifestations and that may be associated to multiple myeloma (Chart 1).

Mucinosis was yet another condition found in the context of paraproteinemia. This case was considered as a form of the illness that could not be included in any of the defined forms of classification of mucinoses, because, histopathologically the patient had an intense deposit of mucin, with moderate pro-

CHART 1: Cutaneous diseases associated to multiple myeloma**Specific cutaneous manifestations:**

- Extramedullary cutaneous plasmacytoma

Almost always associated:

- Scleromyxedema
- POEMS syndrome
- Schnitzler's syndrome
- Necrobiotic xanthogranuloma

Frequently associated:

- Normolipemic plane xanthoma
- Buschke's Scleroderma
- Acquired deficiency of C1 esterase inhibitor angioedema

Significant association (≥15% of cases):

- Primary systemic amyloidosis
- *Erythema elevatum diutinum*
- Subcorneal pustular dermatosis
- IgA Pemphigus
- Pyoderma gangrenosum

Occasionally associated:

- Acquired cutis laxa
- Sweet Syndrome
- Hypergammaglobulinemic purpura of Waldenström
- Disseminated xanthoma
- Small vessel cutaneous vasculitis
- Acquired Bullous Epidermolysis
- Paraneoplastic pemphigus

liferation of fibroblasts and without an increase in collagen, which would lead us to the diagnosis of papular mucinosis. However, we observed, clinically, a plaque with severe edema on the arm and the presence of inframammary blisters, which were discordant with the histopathological classification. Therefore, we might classify this case as atypical cutaneous mucinosis. There are no cases reported on the

literature of cutaneous mucinosis manifesting clinically as blisters. Until the present, there is only one published report of papular mucinosis associated to primary systemic amyloidosis in a patient with paraproteinemia.⁵

Acquired cutis laxa has been described in patients with MM. In several patients with CLA, the involvement of the face and neck occurs first, with a cephalocaudal progression, such as in the case reported here. Despite the probability of visceral involvement in CLA, causing pulmonary emphysema, gastric fibromas and tracheobronchial malacia, no other organ was affected in our patient.

A possible differential diagnosis, in this case, is pseudoxanthoma elasticum (PXE), one of our first hypotheses. It was rejected by the absence of calcium on von Kossa staining. Other findings were also contrary to this diagnosis, such as the palpebral involvement (there are no reports on the literature of PXE affecting the eyelids); and the absence of signs that other organs were affected, such as, retinal angioid streaks.

There are no treatments to prevent the progression of cutis laxa, although the normal cicatrization process of these patients allows for surgical corrections.⁶ Due to the progressive nature of this disease, many interventions are required over time. Two blepharoplasties were performed in our patient, with subsequent relapse of the palpebral ptosis.

First-line treatment for MM was started with Bortezomib and Dexamethasone, followed by autologous bone marrow transplantation, with clinically important dermatological improvement.

This case presents a plethora of cutaneous findings (primary systemic amyloidosis, acquired cutis laxa and mucinosis), all linked to MM. There is not, at present, another description of all these findings on the same patient. □

REFERENCES

1. Gupta A, Helm TN. Acquired cutis laxa associated with multiple myeloma. *Cutis*. 2002;69:114-8.
2. McCarty MJ, Davidson JM, Cardone JS, Anderson LL. Cutis laxa acquisita associated with multiple myeloma: a case report and review of the literature. *Cutis*. 1996;57:267-70.
3. Alvarez-Ruiz SB, García-Río I, Daudén E. Amiloidosis sistémicas (*Systemic amyloidosis*). *Actas Dermosifiliogr*. 2005;96:69-82.
4. Oliveira EV, Pozetti AC, Pozetti EM, Antonio JR, Michalany NS. Primary systemic amyloidosis associated with multiple myeloma. *An Bras Dermatol*. 2012;87:119-22.
5. Ishibashi A, Nakabayashi K, Kukita A. Coexistence of papular mucinosis and systemic amyloidosis associated with lambda-type IgD paraproteinemia. *J Dermatol*. 1989;16:64-7.
6. Shah-Desai SD, Collins AL, Tyers AG. Surgical correction of entropion and excess upper eyelid skin in congenital cutis laxa: a case report. *Orbit*. 1999;18:53-8.

MAILING ADDRESS:

Fernanda Guedes Lavorato
Secretaria da dermatologia.
Av. 28 de setembro, 77 - Vila Isabel
20551-030 - Rio de Janeiro - RJ
Brazil
E-mail: fglavorato@yahoo.com.br

How to cite this article: Lavorato FG, Alves MFGS, Maceira JMP, Unterstell N, Serpa LA, Azulay-Abulafia L. Primary systemic amyloidosis, acquired cutis laxa and cutaneous mucinosis in a patient with multiple myeloma. *An Bras Dermatol*. 2013;88(6 Suppl 1):S32-5.